

“Non-Diabetic Retinal Vascular Disease”

Brad Sutton, O.D., F.A.A.O.

Clinical Professor

IU School of Optometry

Indianapolis Eye Care Center

Retinal Vascular Disease

- ▶ No financial disclosures

Hypoperfusion Syndrome

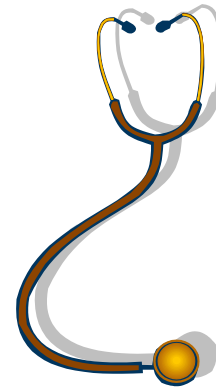
- ▶ Occurs when the eye lacks blood perfusion secondary to carotid artery blockage or ophthalmic artery blockage.
- ▶ Terminology debate: venous stasis retinopathy vs. hypoperfusion syndrome
- ▶ Why is venous stasis retinopathy a poor term for this condition? Because it is an arterial problem, not a venous problem. The venous stasis is the result of poor flow into the arteries

Hypoperfusion Syndrome

- ▶ Patient may complain of dull, chronic ache in the affected eye
- ▶ Photostress issues / dazzle
- ▶ TIA symptoms may or may not be present (amaurosis fugax)
- ▶ Possible bruit / decreased pulse strength in carotid


Hypoperfusion Syndrome

- ▶ Bruit at 30-85% blockage; swishing sound
- ▶ Bell vs. diaphragm
- ▶ Definitive diagnosis requires carotid imaging



Hypoperfusion Syndrome

- ▶ Peripheral dot / blot hemorrhages
- ▶ Dilated veins
- ▶ Relatively spares the posterior pole



Ocular Ischemic Syndrome

- ▶ With ocular ischemic syndrome same findings plus.....
 - ▶ NVD / NVE / NVI
 - ▶ Iritis
 - ▶ Sluggish pupil
 - ▶ Conjunctival congestion
 - ▶ Corneal Edema
 - ▶ 80% unilateral / 20% bilateral

Ocular Ischemic Syndrome

- ▶ Rare! Only 10% of eyes with 70+% blocked carotids
- ▶ 60% CF or worse VA by one year: 82% if NVI is present
- ▶ Teichopsia: colored afterimages after viewing lights
- ▶ More likely in patients with increased homocysteine and CRP

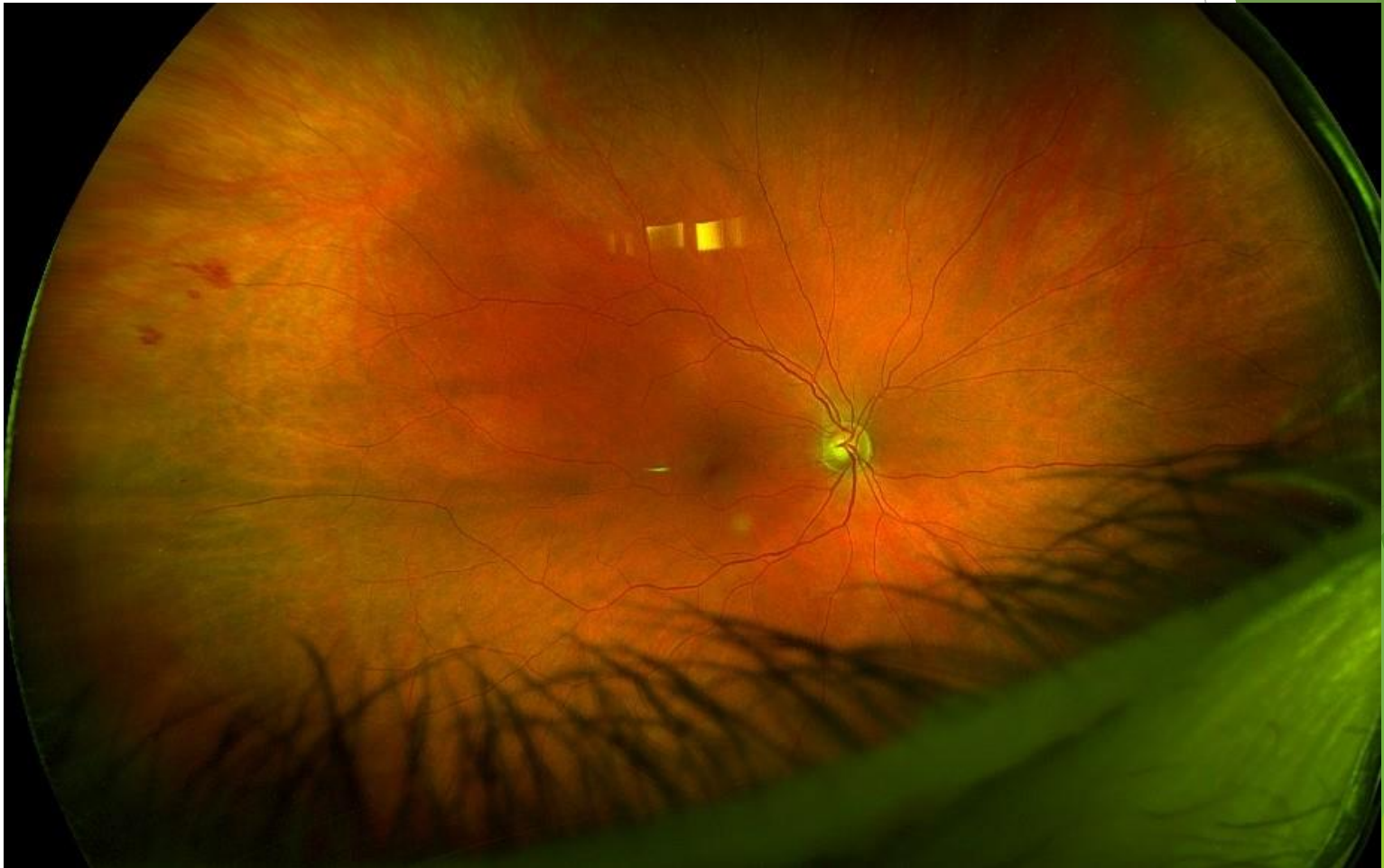Ocular Ischemic Syndrome

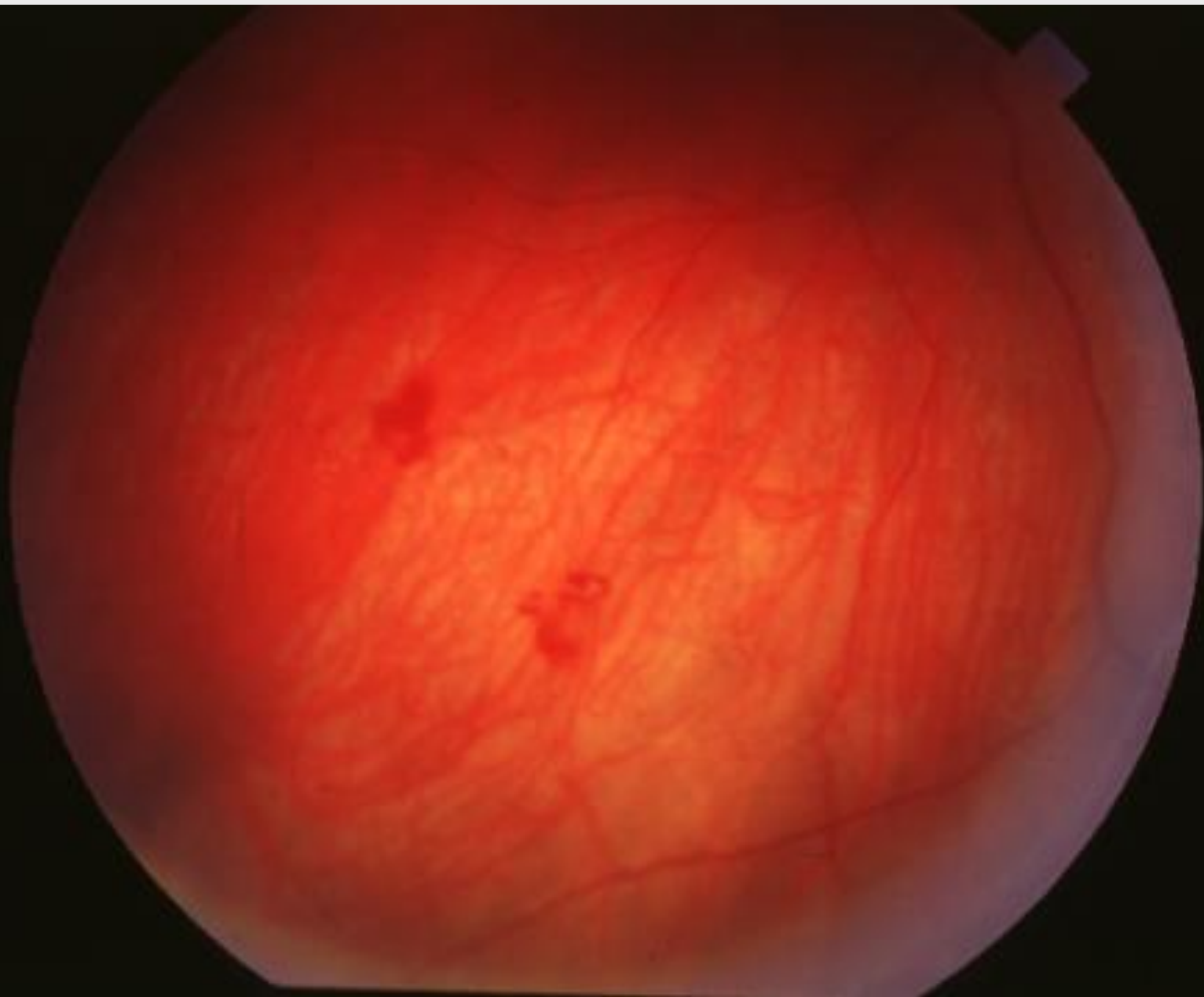
- ▶ When presented with these ocular findings.....
 - ▶ Question about TIA
 - ▶ Check carotids
 - ▶ Arrange for carotid testing (Doppler has limits)
 - ▶ ESR
 - ▶ C-reactive protein
 - ▶ CBC

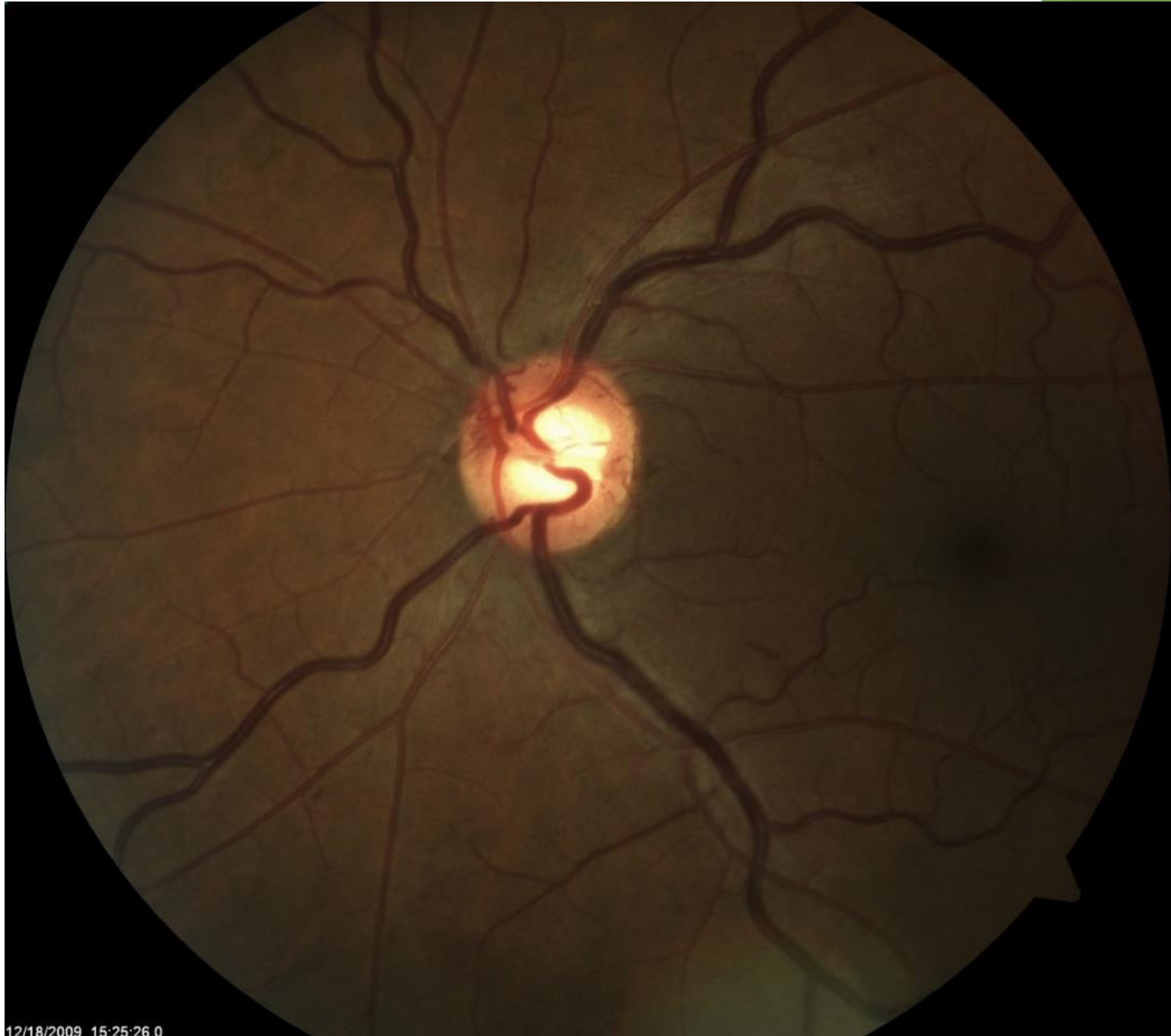
Ocular Ischemic Syndrome

- ▶ Treatment:
 - ▶ Systemic management (diet, drugs, surgery)
 - ▶ PRP / cryotherapy?
 - ▶ Avastin / Lucentis / Eyelea?
 - ▶ Five-year mortality rate of 40%

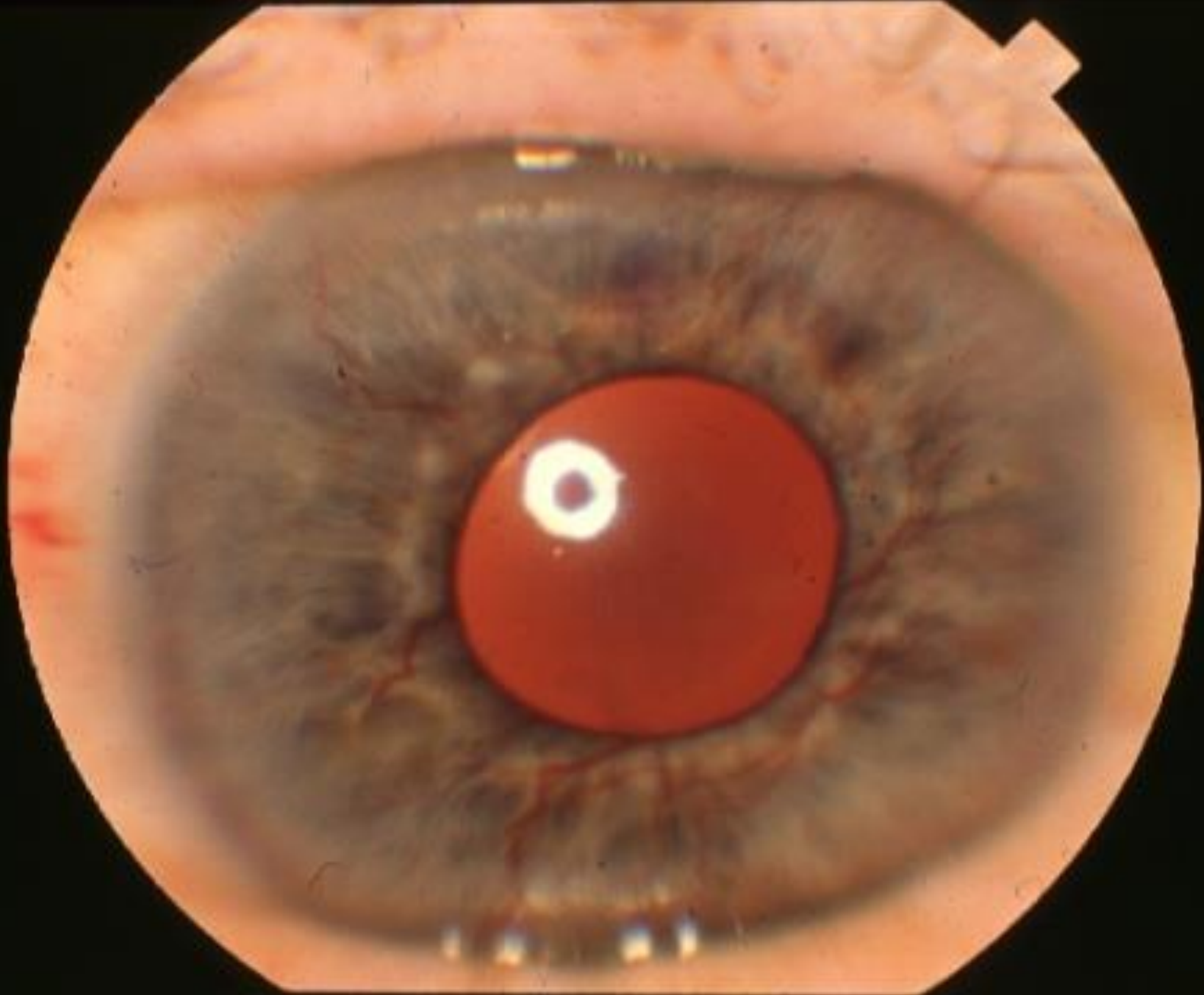
Hypoperfusion syndrome







6.3.9.0



Sickle Cell Retinopathy


- ▶ Hemoglobinopathy affecting mostly AA (8% in US carry trait, .27% have sickle cell disease.)
- ▶ About 100,000 people in the US have the disease
- ▶ Malaria and natural selection (sickle trait carriers are resistant to malaria)
- ▶ AC, SA, SS, Sthal, SC. All forms **autosomal recessive**. A is normal hemoglobin
- ▶ Improper amino acid substitutions

Sickle Cell

- ▶ RBC's become sickle shaped
- ▶ RBC's get trapped > hypoxia > ischemia > more sickling = cycle (also sickle due to acidosis, hyperosmolarity)
- ▶ Splenectomies common, can be fatal
- ▶ SS patients have the worst systemic complications while SC and Sthal patients have the most severe ocular problems

Sickle Cell

- ▶ Related to blood viscosity- ? Related to life expectancy
- ▶ Sickle cell retinopathy progresses through five stages



Red Blood Cell

Sickle Cell Stages


- ▶ Stage I :peripheral arteriolar occlusion
- ▶ Stage II:peripheral arterio-venular anastomoses
- ▶ Stage III: Neo
- ▶ Stage IV: Vitreous Heme
- ▶ Stage V: RD

Sickle Cell Retinopathy

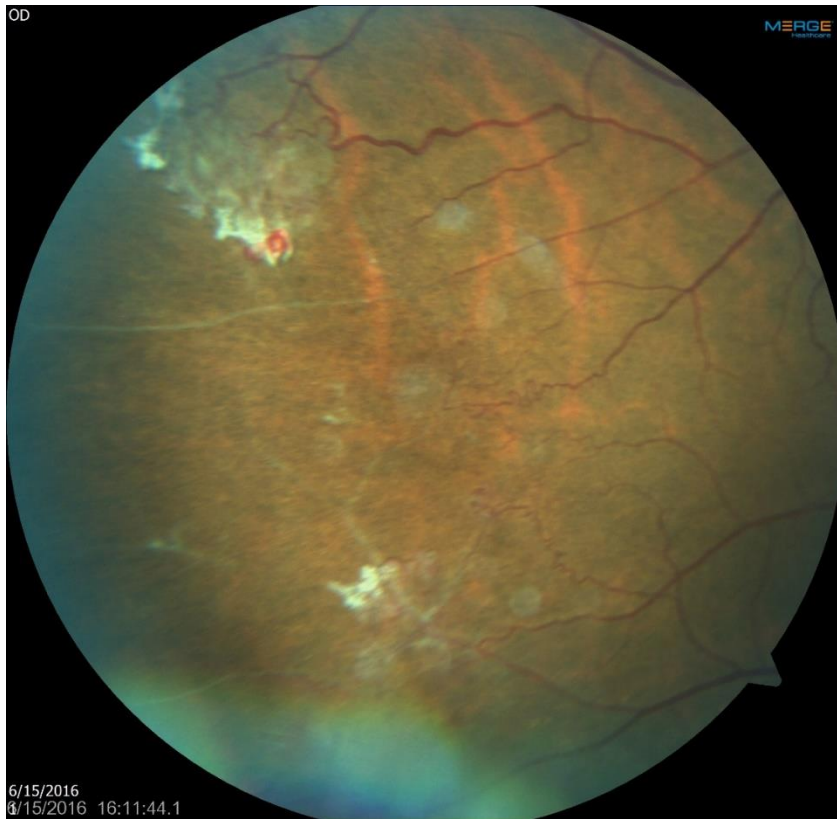- ▶ **Pre-proliferative findings...**
- ▶ Salmon-patch hemes
- ▶ Sunburst pigment
- ▶ Refractile bodies
- ▶ Silvering of arterioles
- ▶ ERM
- ▶ Schisis
- ▶ Conj. comma sign
- ▶ **Proliferative findings and others:**
- ▶ Sea-fan NV
- ▶ Vit Heme
- ▶ RD
- ▶ Angioid streaks
- ▶ CRAO / BRAO
- ▶ Hyphema issues (24-24 rule)

Sickle Cell Retinopathy

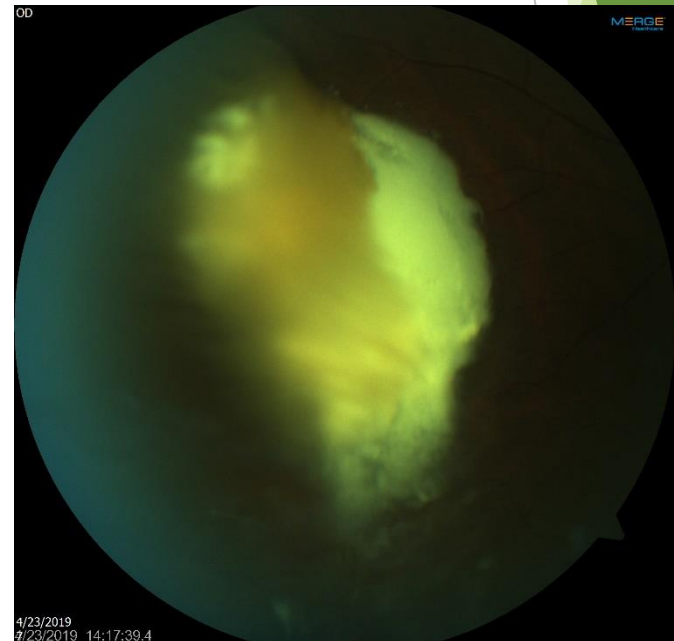

- ▶ PRP or cryo anterior to sea fans
- ▶ Anti-VEGF injections
- ▶ Is treatment always necessary? No! The sickled RBC's can occlude the sea fan NVE, and cause it to regress



Sea fans: S-Thal

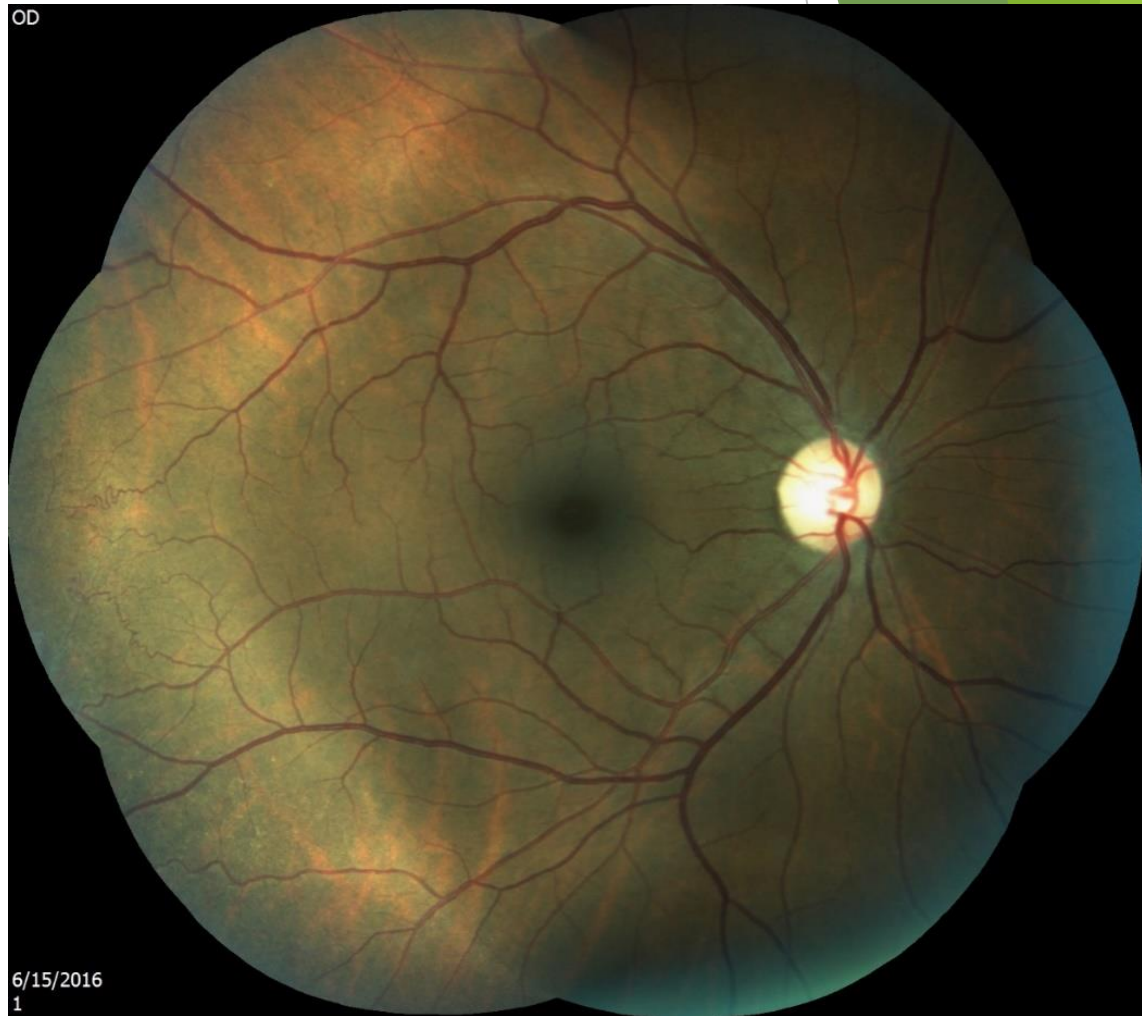

2016

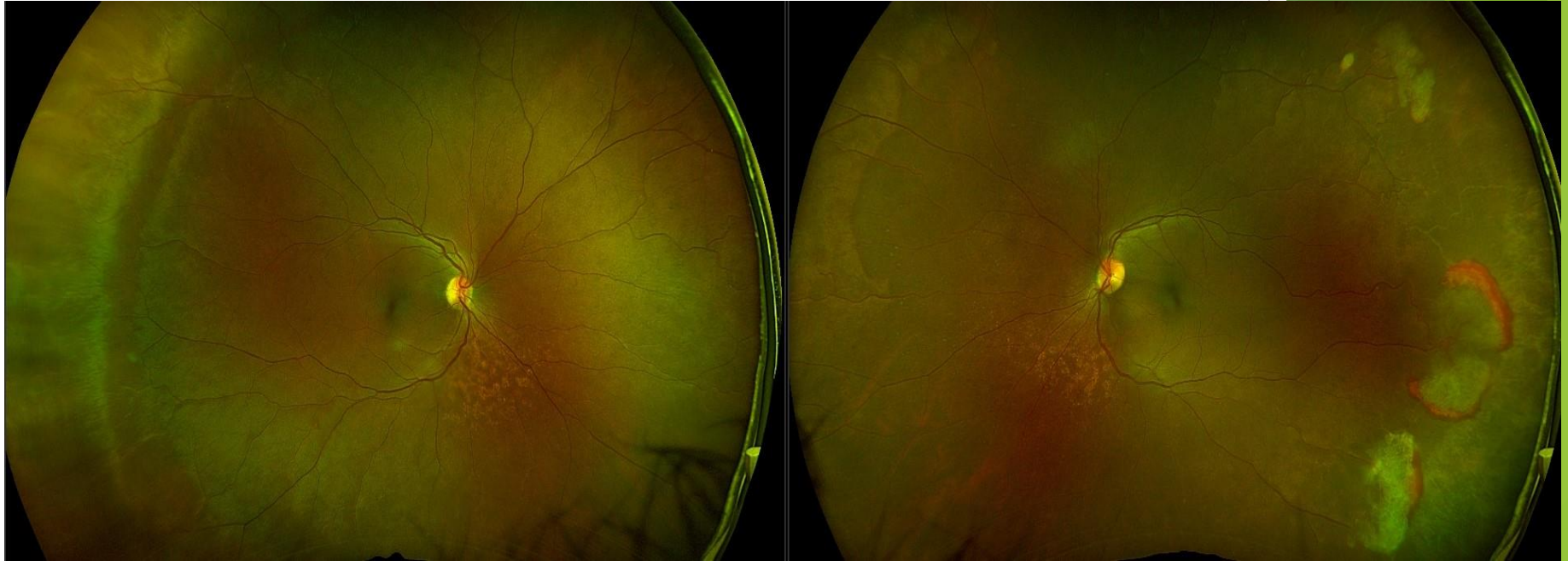


2019

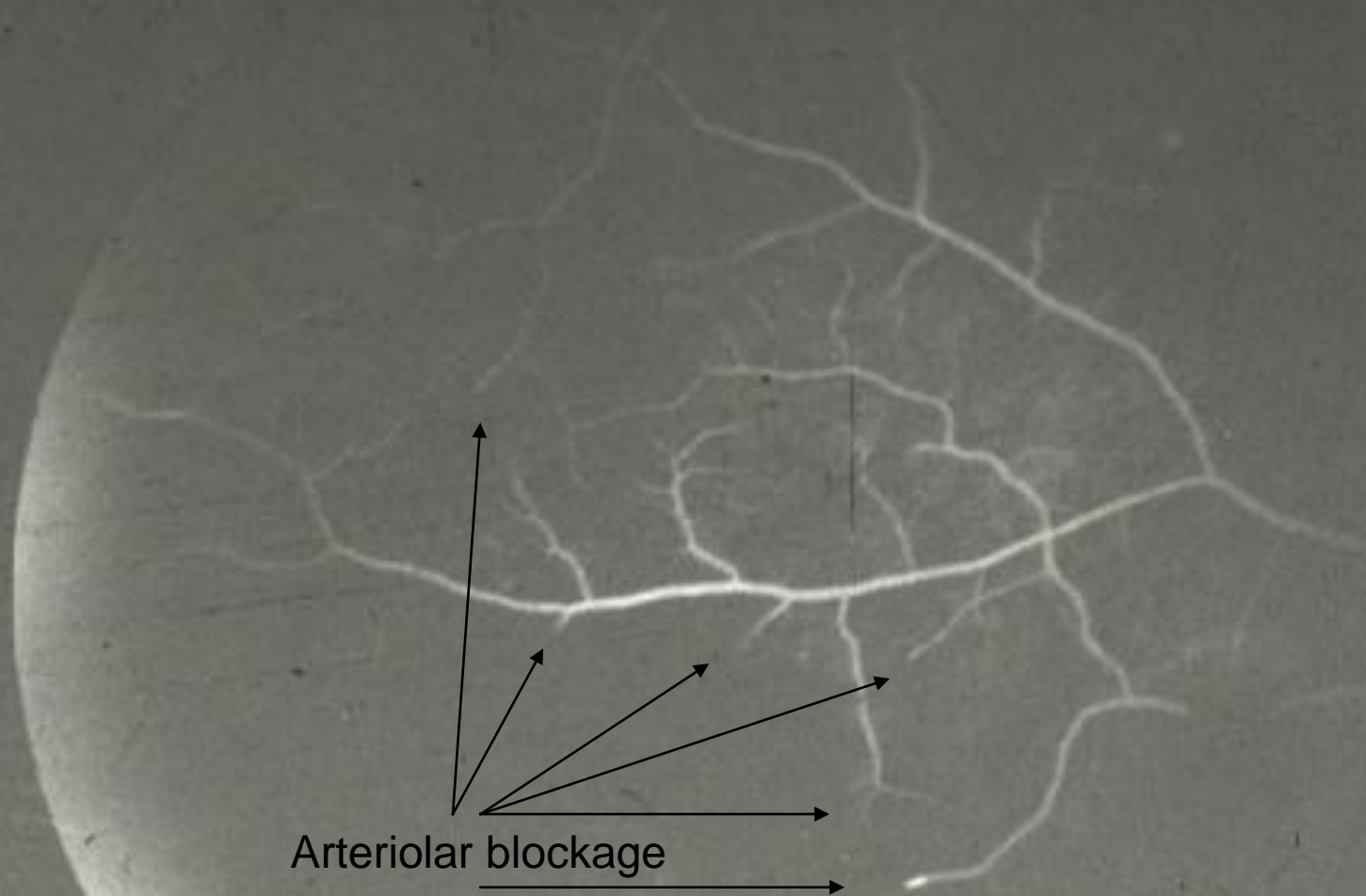
Peripheral anastomoses: S- Thalassaemia



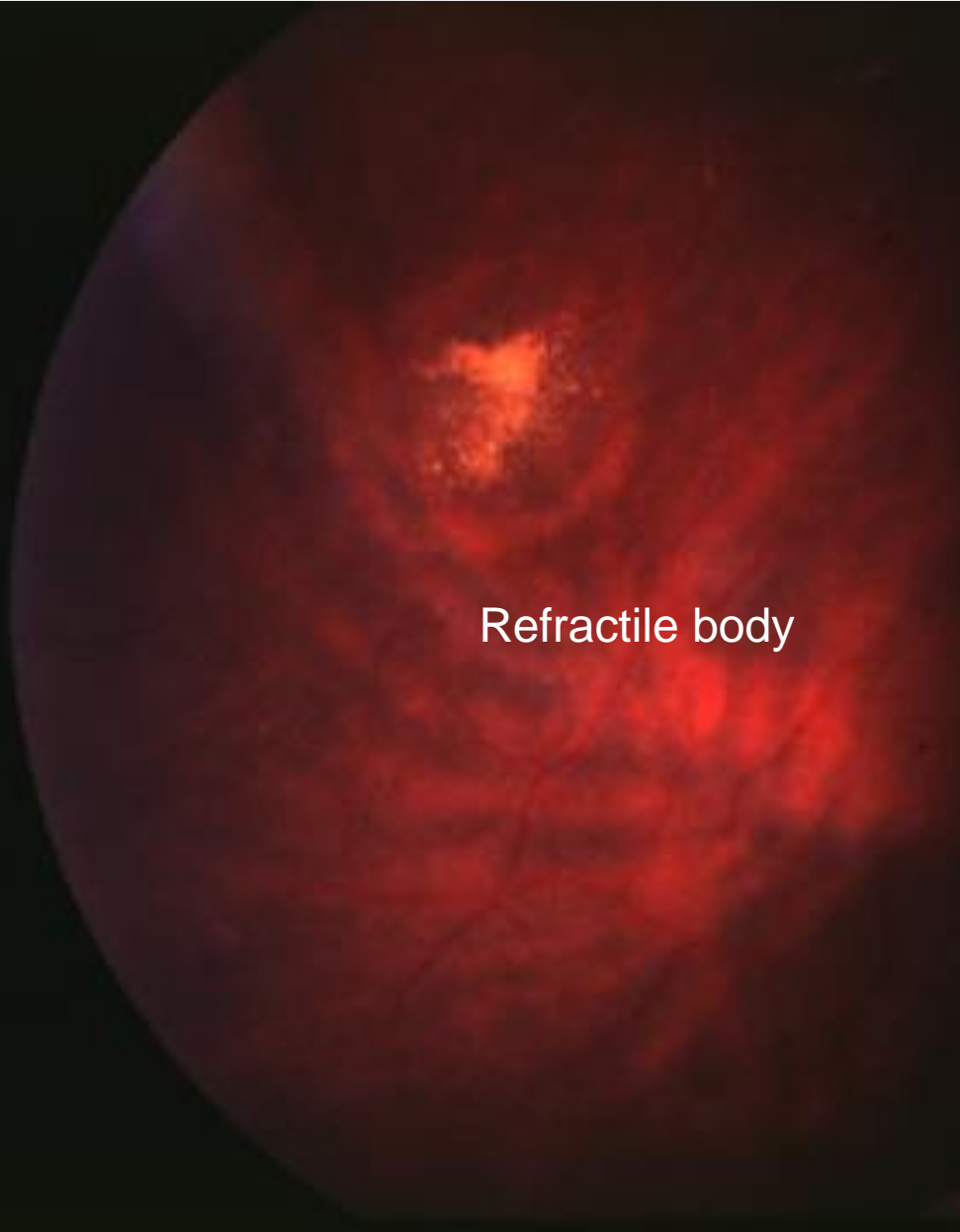
Not sickle cell, but.....



4481



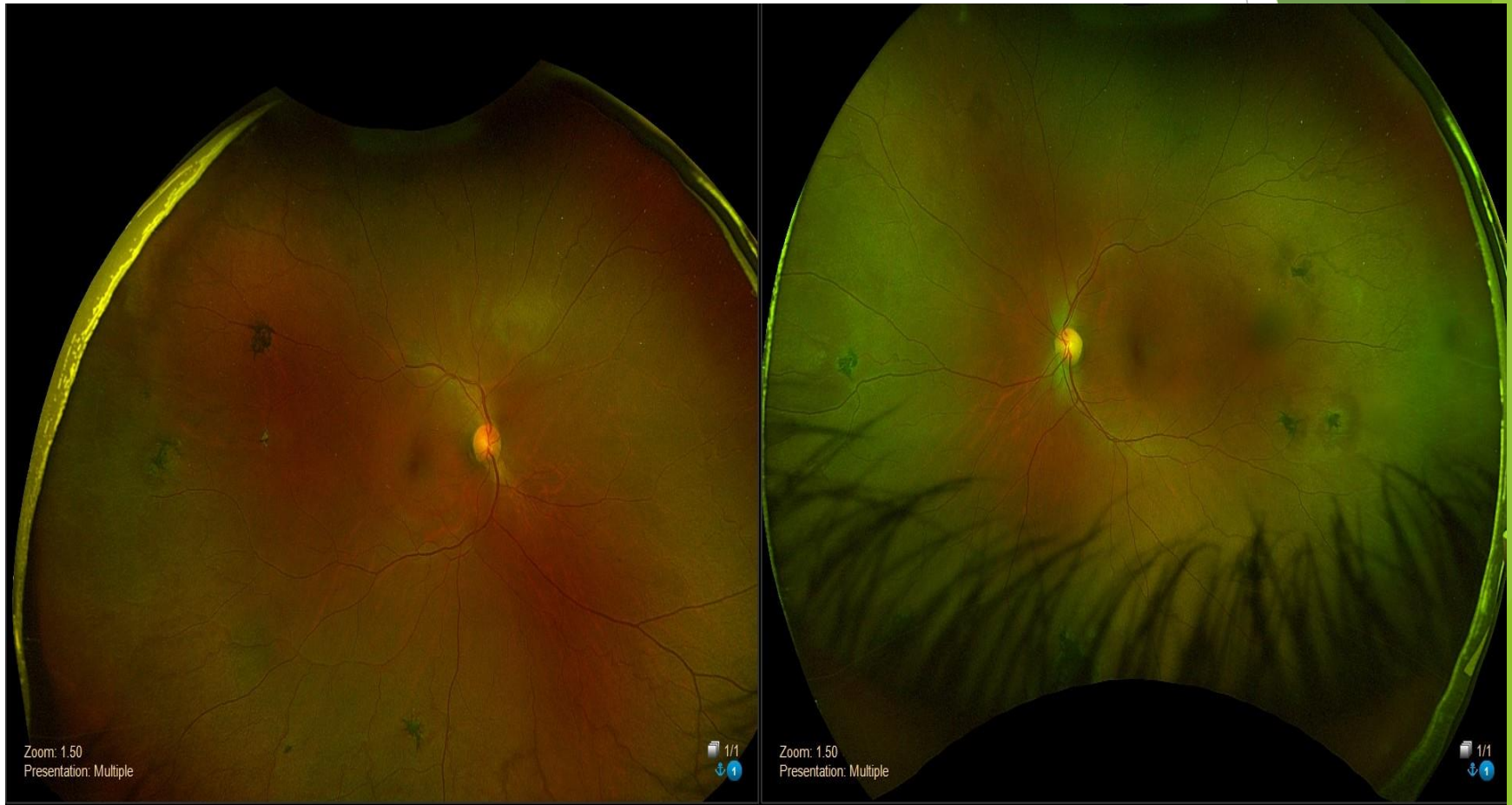
Arteriolar blockage

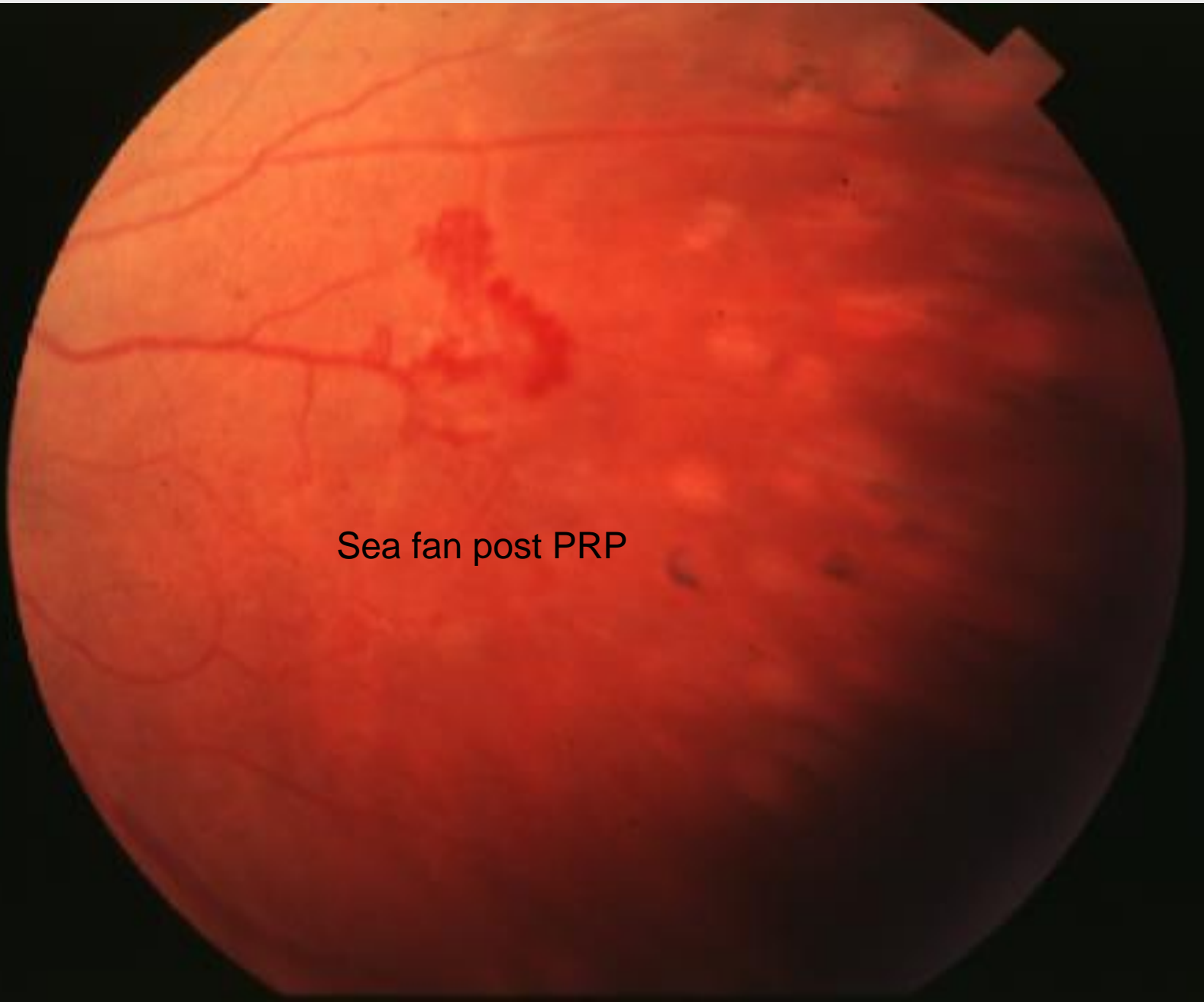


Refractile body

0.0.0.0

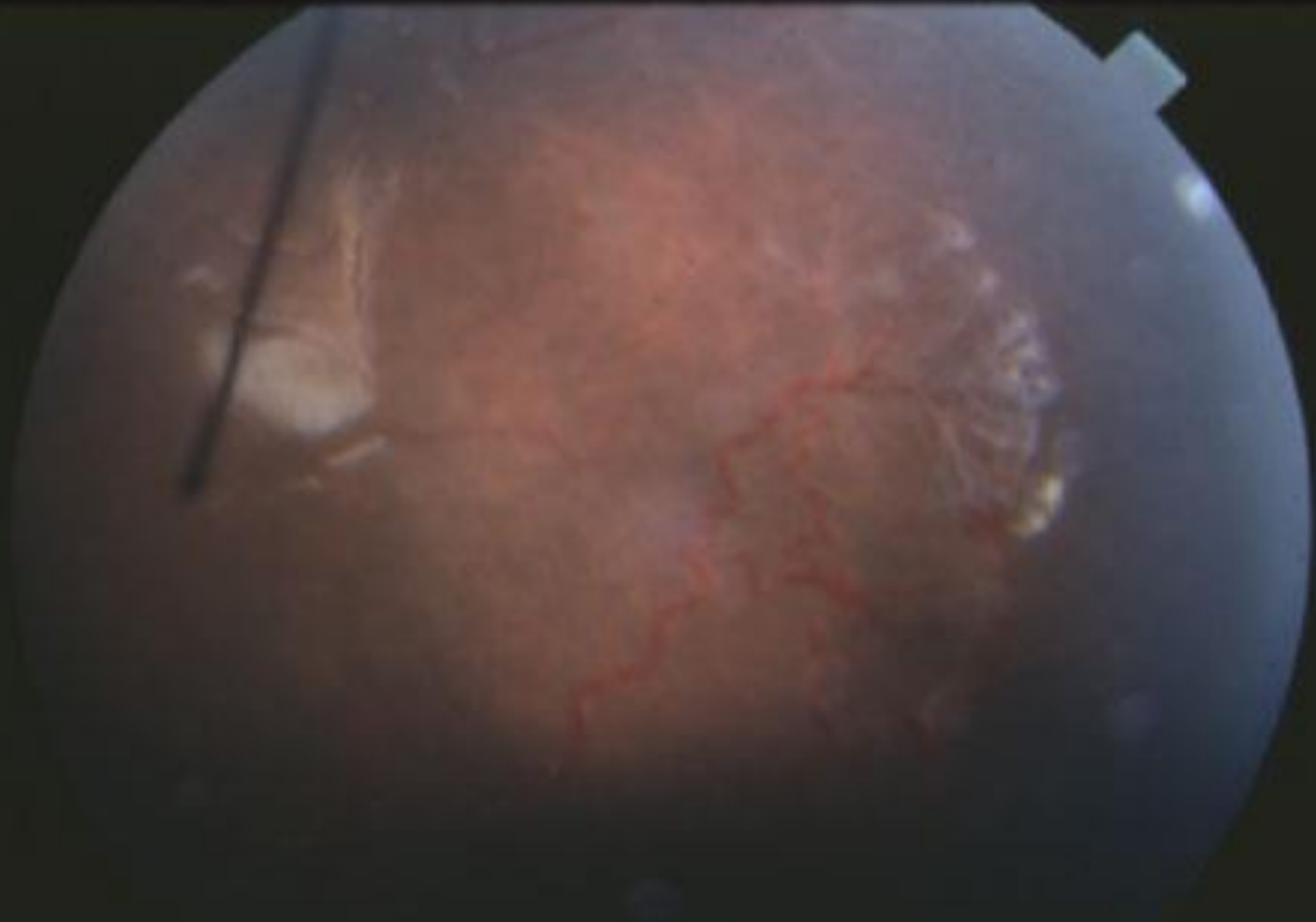
Sunburst pigment

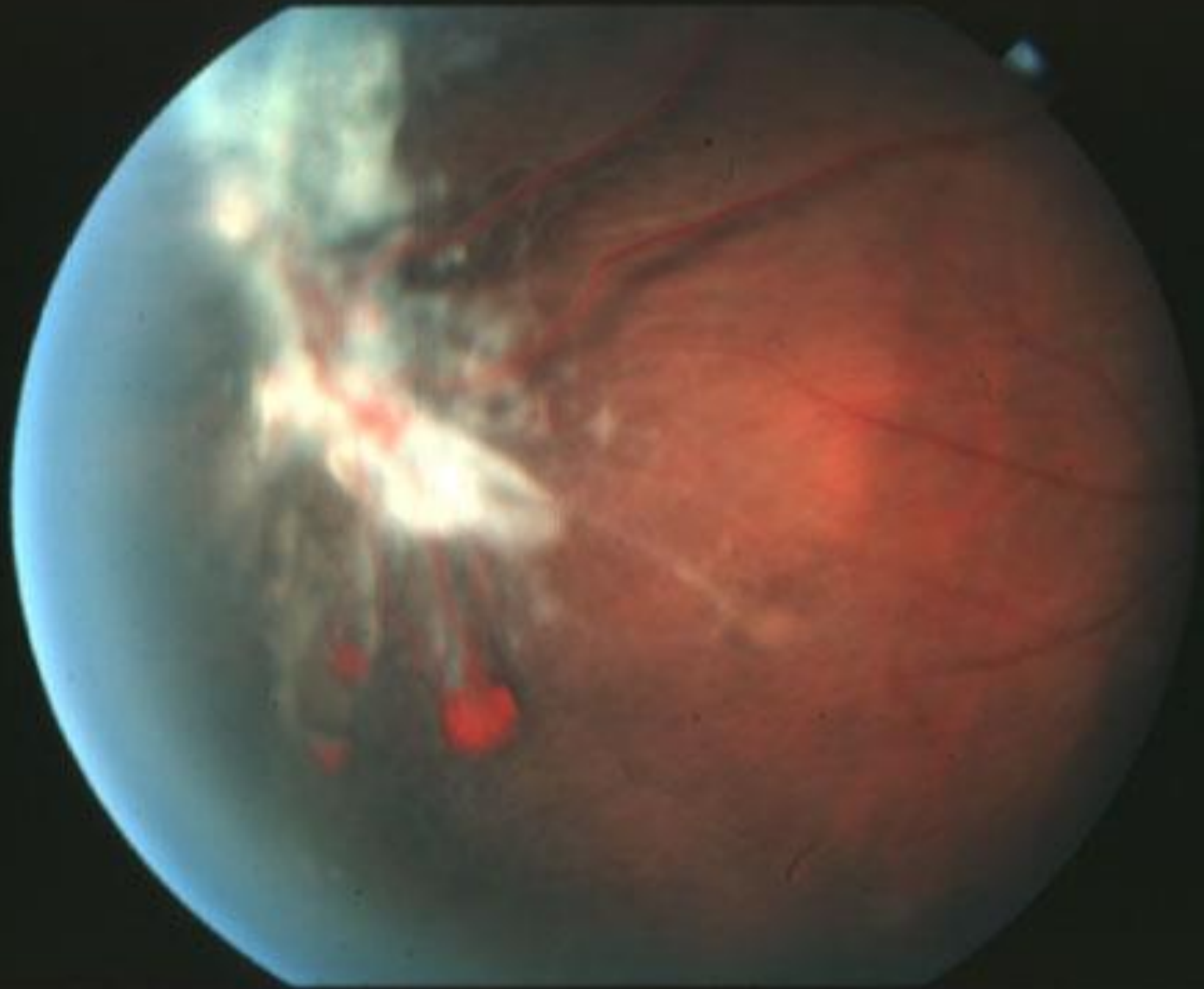



Sea fan post PRP

0017





15710

Hypertensive Retinopathy

- ▶ 58 million Americans with HTN
- ▶ About 40% of AA adults; around 30% of C adults
- ▶ 75% of people over age 65
- ▶ 20% of all hypertensive individuals are undiagnosed
- ▶ Primary hypertension comprises 85-90% of all cases

Hypertensive Retinopathy

- ▶ Many associated retinal findings-window to the body
- ▶ Arteriosclerosis, or arterial hardening, is an early finding
- ▶ Narrowing of the arteries

Hypertensive Retinopathy Grading

- ▶ Grade I : arteries $\frac{3}{4}$ normal caliber
- ▶ Grade II : arteries $\frac{1}{2}$ normal caliber
- ▶ Grade III : arteries $\frac{1}{3}$ normal caliber
- ▶ Grade IV : arteries thread-like or invisible

Study

- ▶ *Hypertension* Journal 2013 (October issue)
- ▶ 2907 Hypertensive patients followed for 13 years.....
- ▶ Mild HTN retinopathy = 35% increase in stroke risk
- ▶ Moderate to severe HTN retinopathy = 137% increase in stroke risk

Hypertensive Retinopathy

- ▶ Sclerosis > increased ALR
- ▶ Flame hemes (NFL)
- ▶ CWS (diastolic above 110)
- ▶ Gunn's sign
- ▶ Papilledema
- ▶ Vein occlusions



Malignant Hypertension

- ▶ Ocular findings are severe and include exudative edema and papilledema
- ▶ Mortality rate:
 - ▶ 80% @ 1 year
 - ▶ 95% @ 2 years



Hypertensive Retinopathy

- ▶ The choroid is commonly affected
- ▶ Elschnig's spots and Siegrist's streaks
- ▶ Watch asymmetry: possible carotid issues

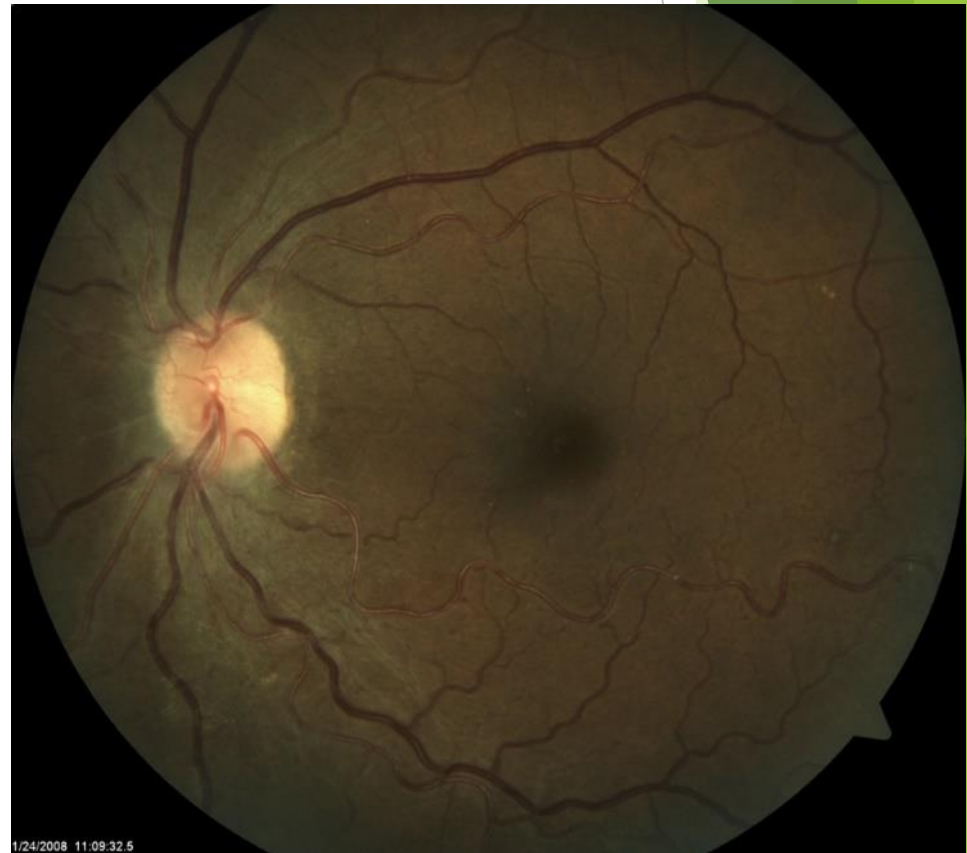
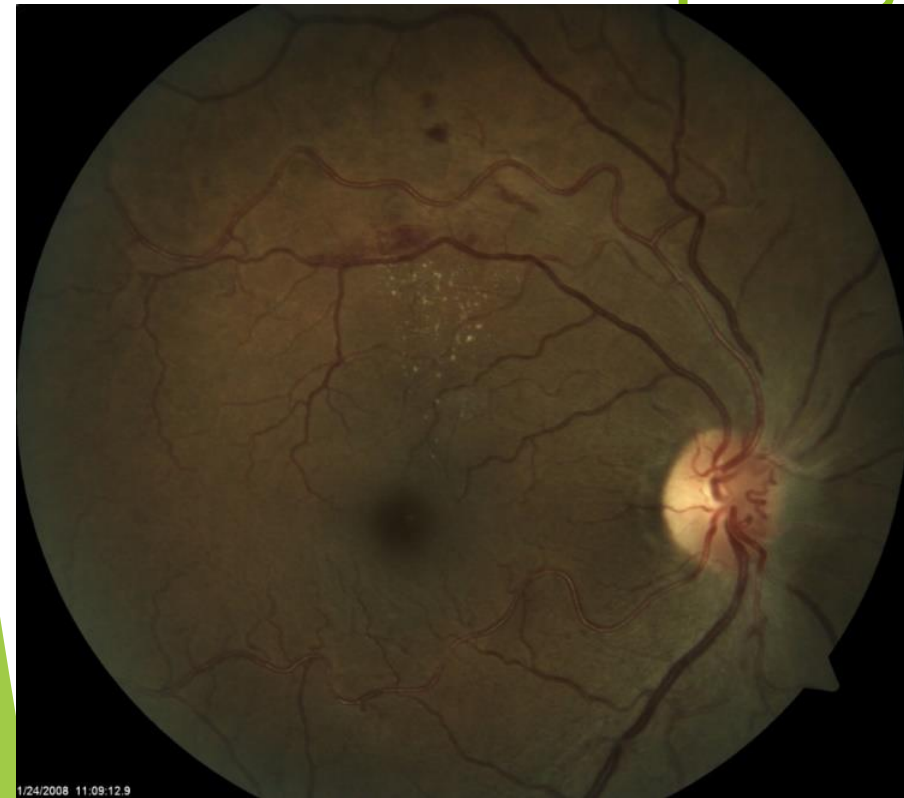
Hypertensive Retinopathy

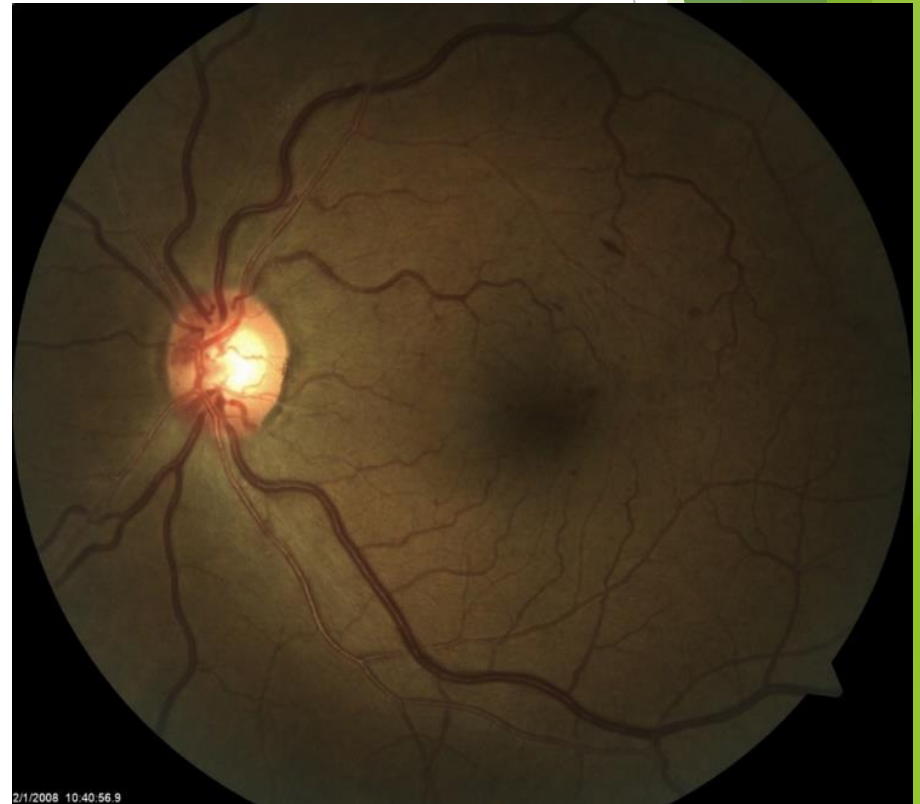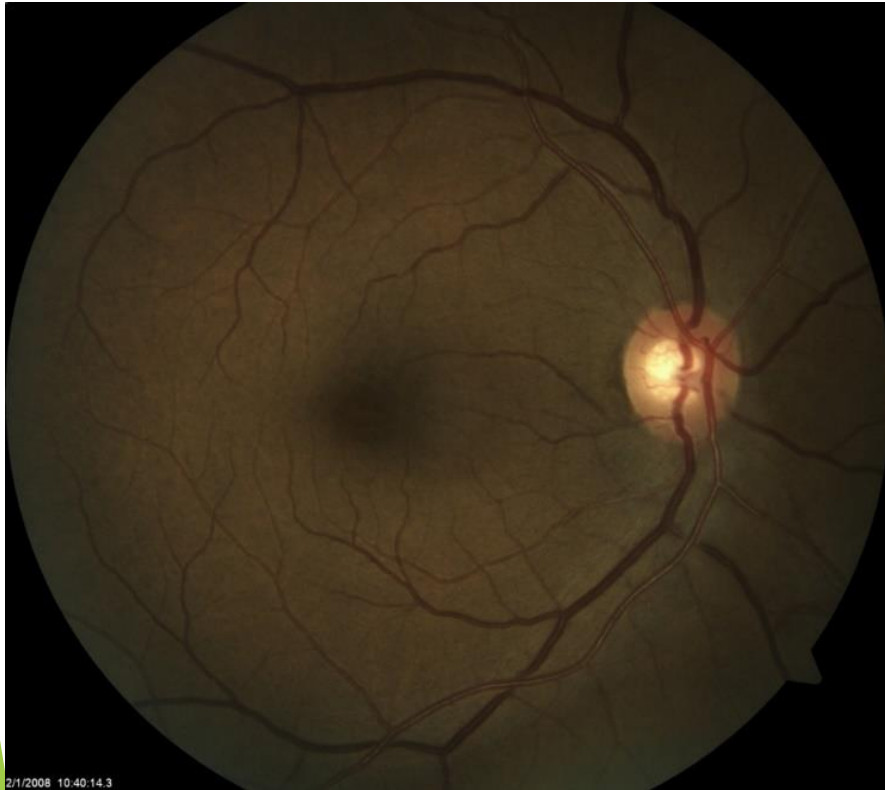- ▶ No ocular treatment; manage by controlling systemic disease



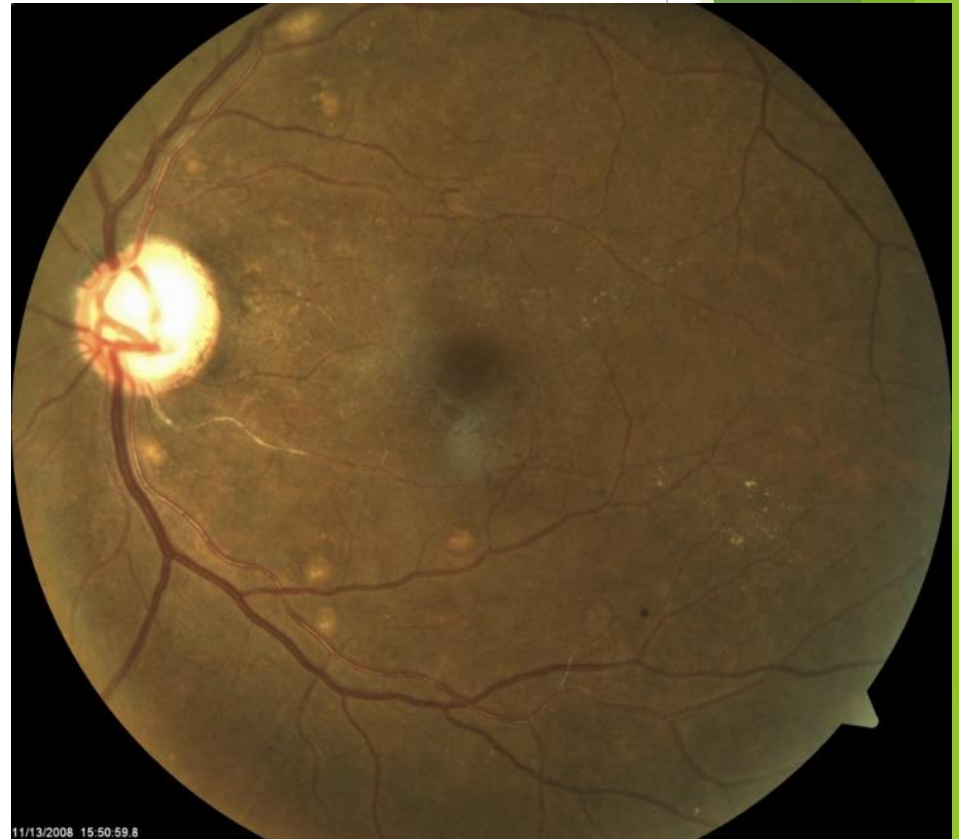
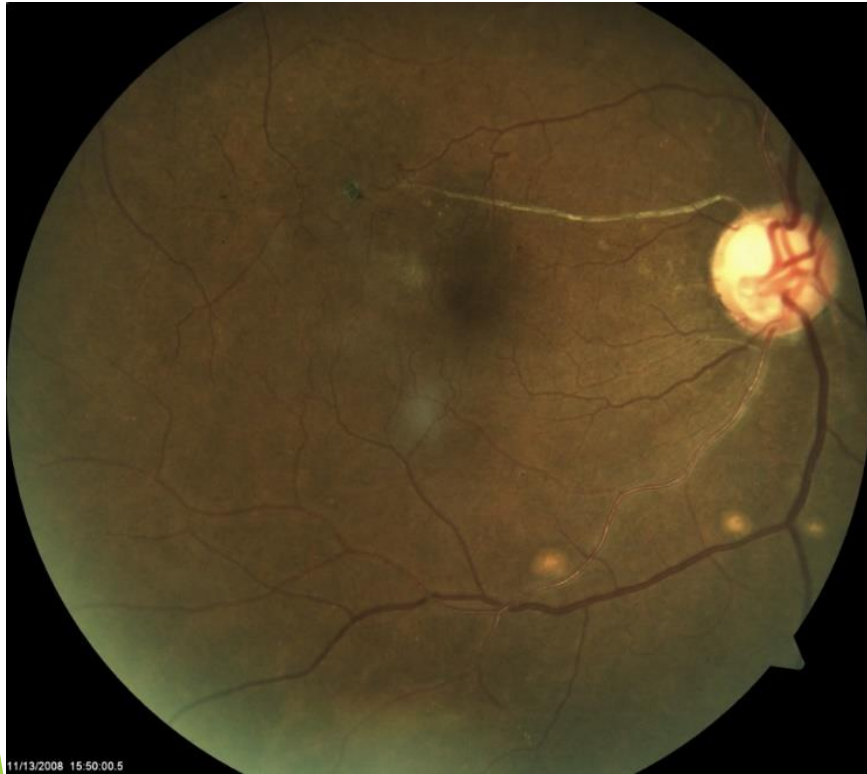HTN vasculopathy



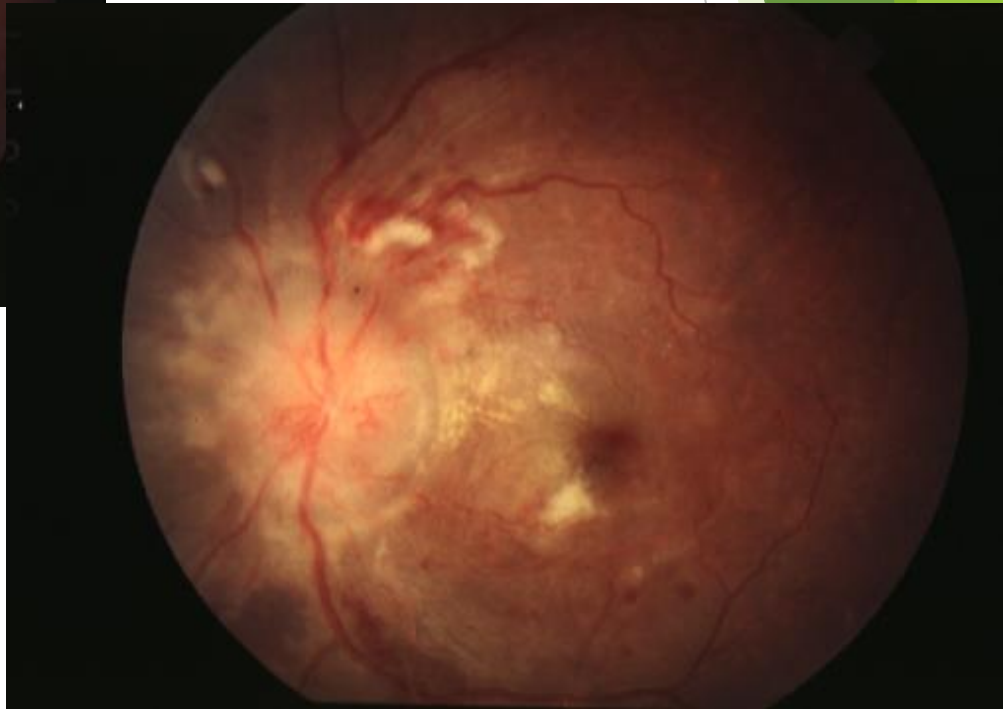
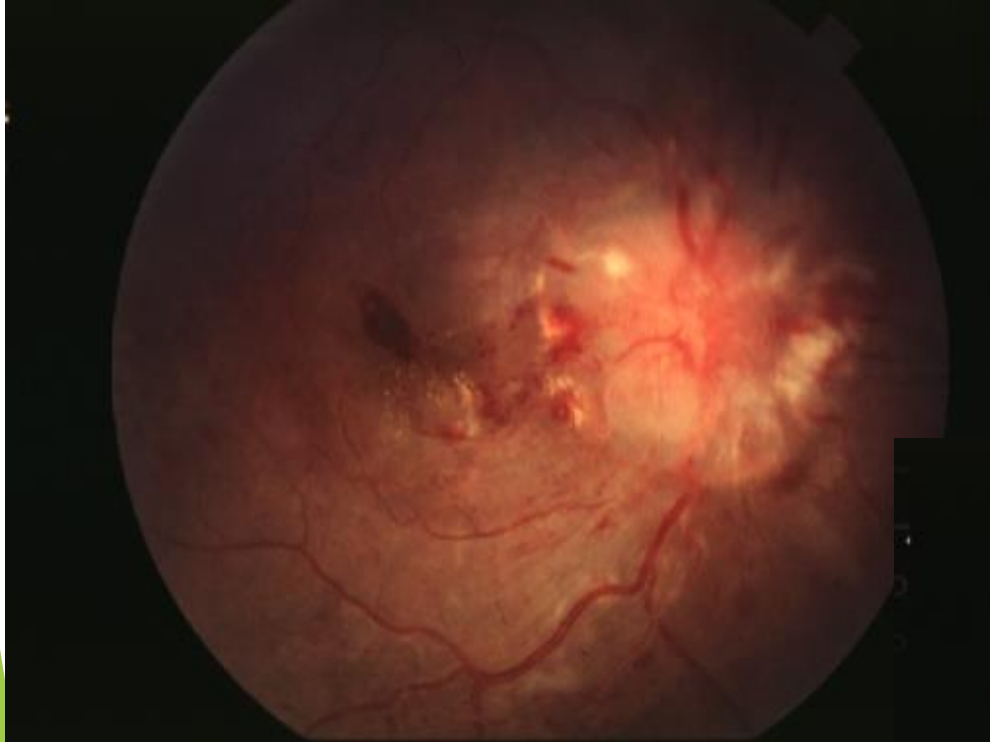HTN vasculopathy and BRVO



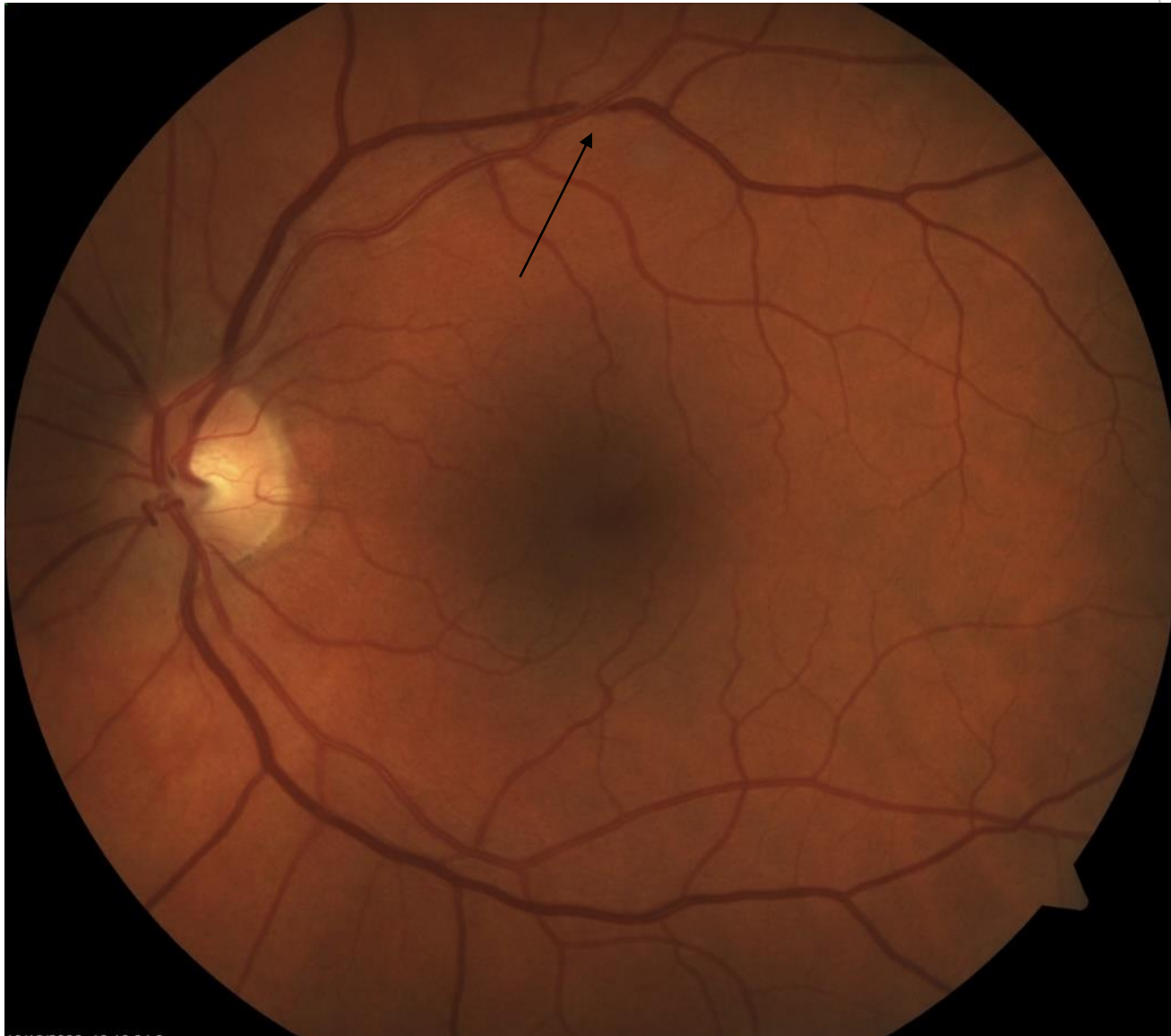HTN vasculopathy



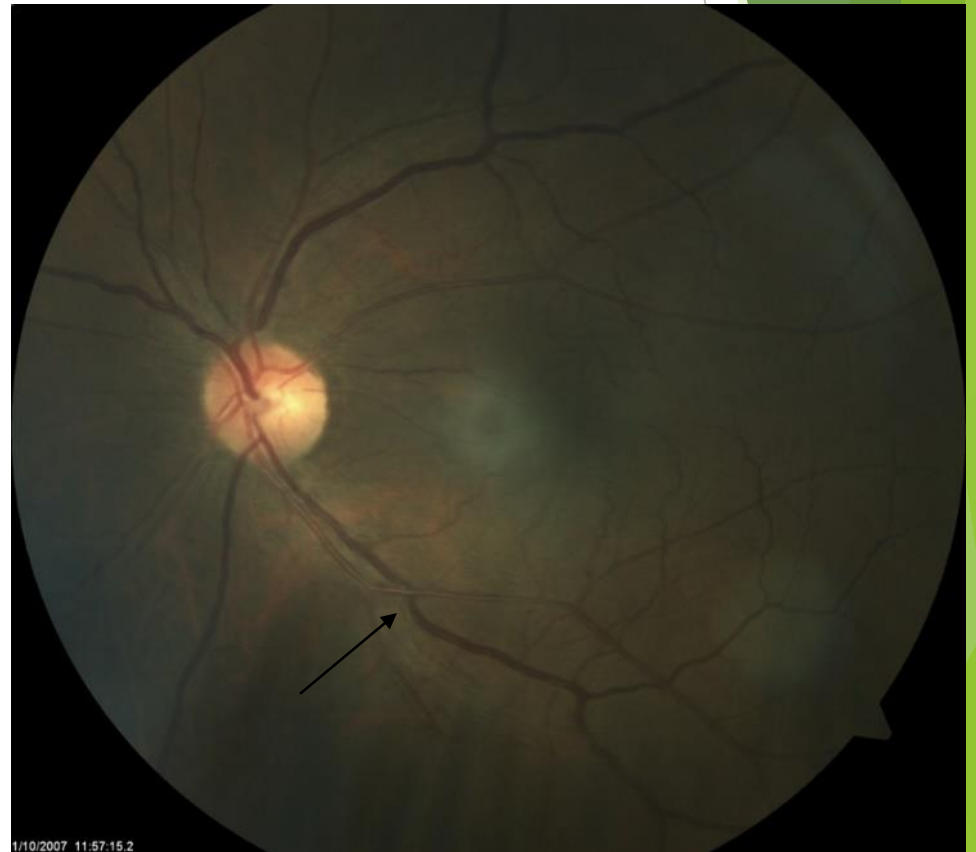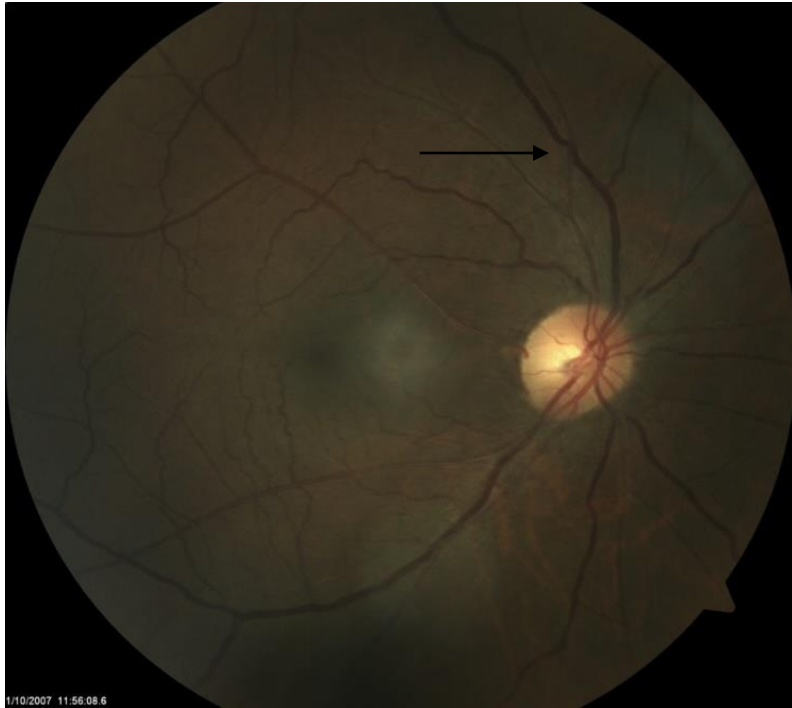Malignant HTN papilledema



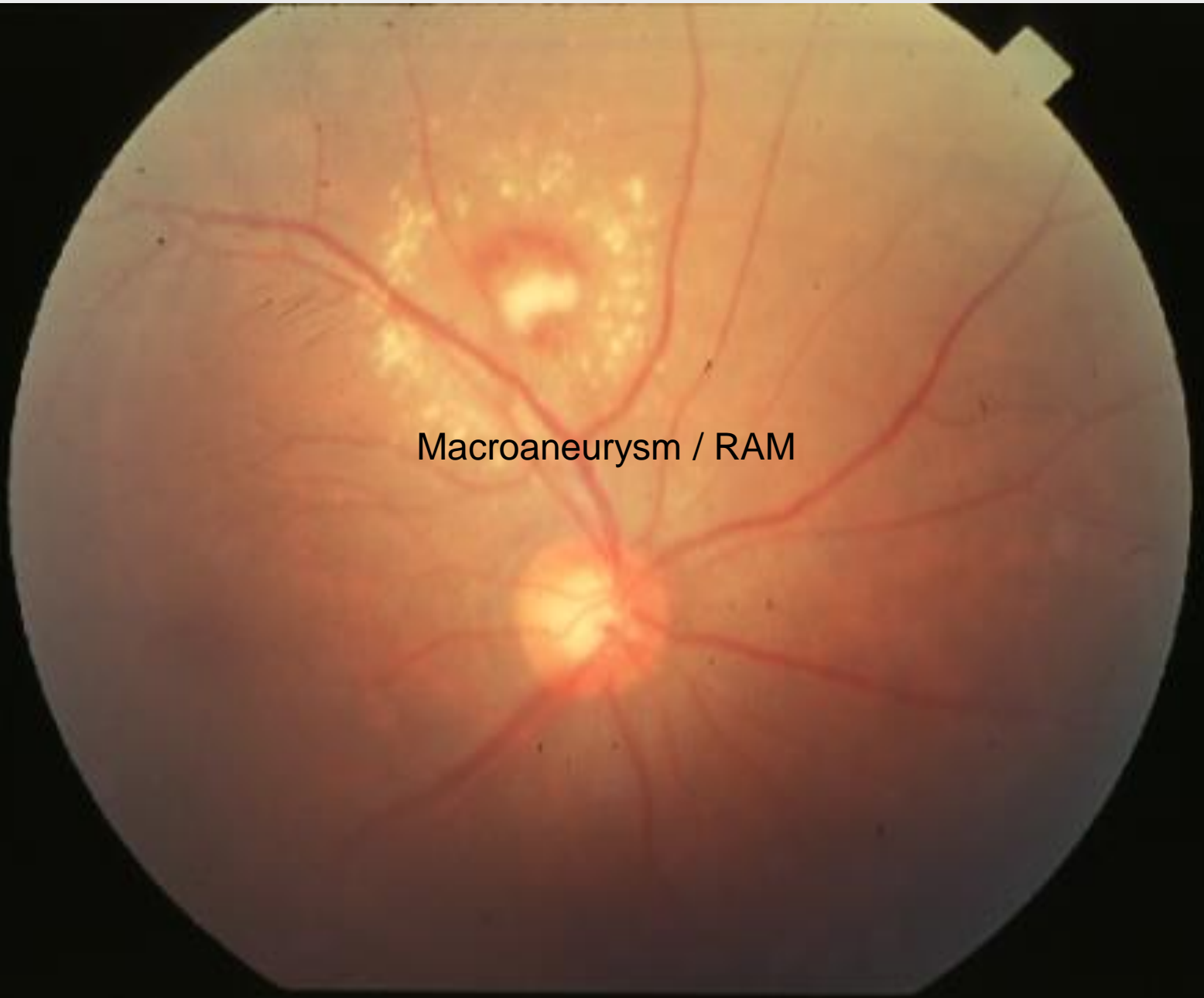
Crossing Change (Gunn's sign)



Crossing changes

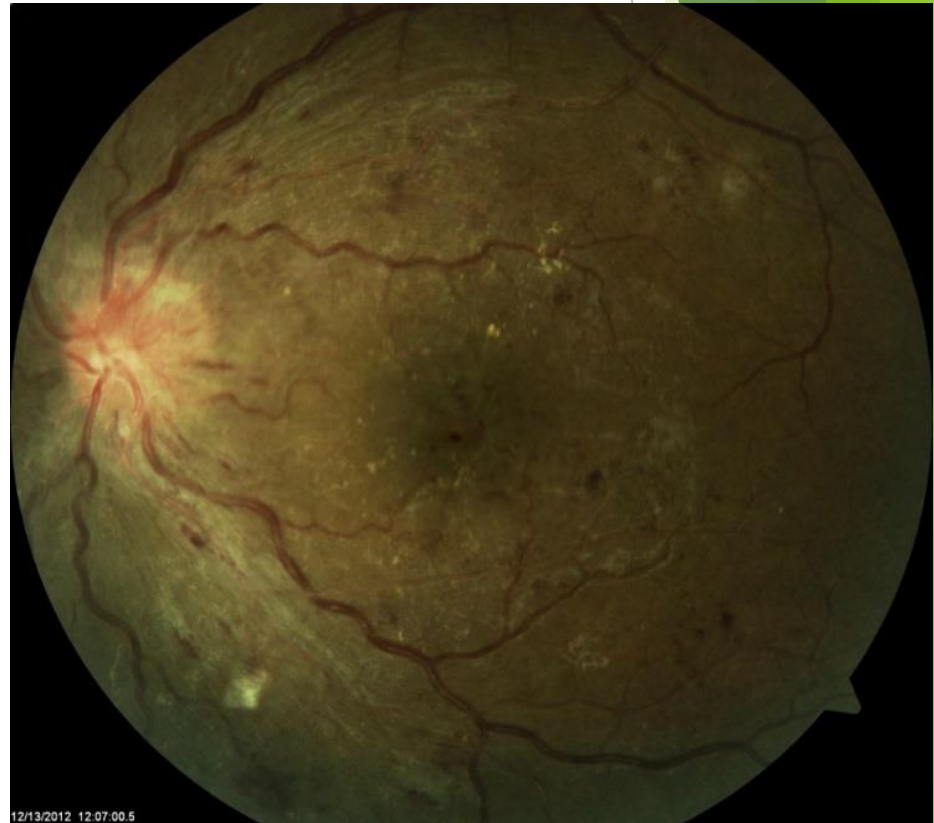
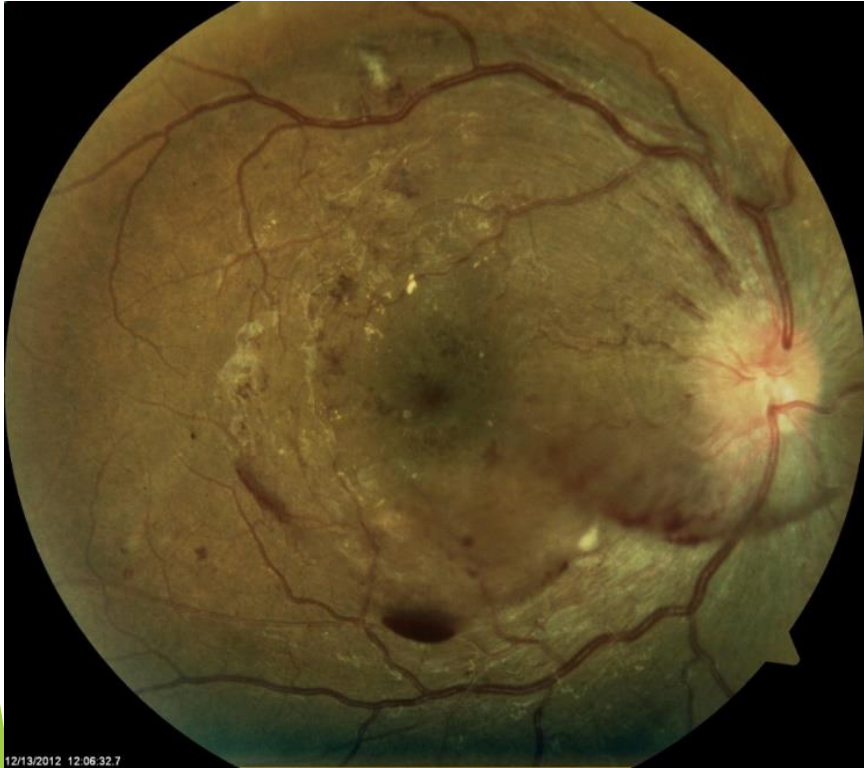
0.0.0.5



Macroaneurysm / RAM

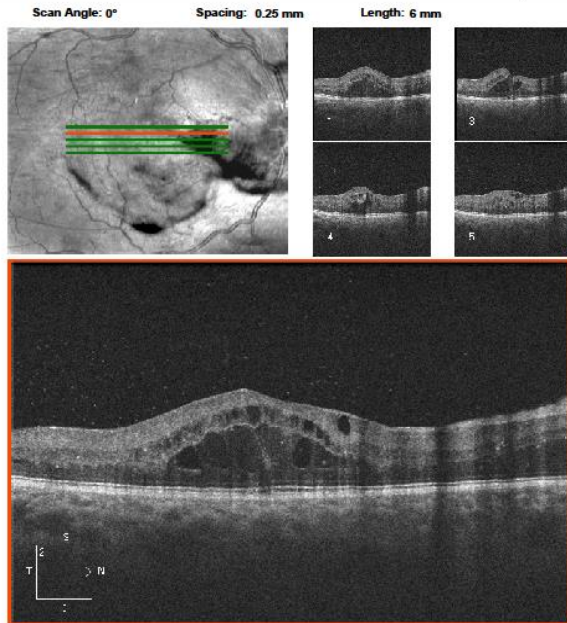
HTN Retinopathy BP 240 / 135



BP 240/135

High Definition Images: HD 5 Line Raster

OD OS



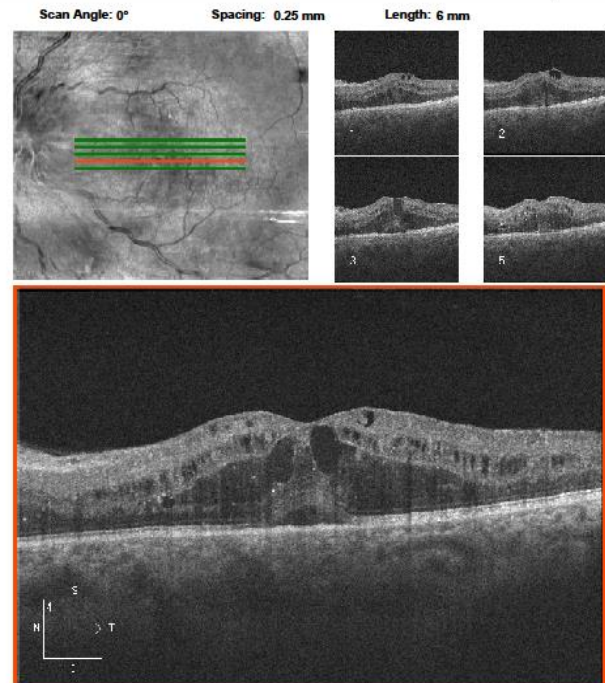
Comments
Acquired using enhanced depth mode

Doctor's Signature

SW Ver: 6.0.1.24
Copyright 2012
Carl Zeiss Medtec, Inc
All Rights Reserved
Page 1 of 1

High Definition Images: HD 5 Line Raster

OD OS



Comments
Acquired using enhanced depth mode

Doctor's Signature

SW Ver: 6.0.1.24
Copyright 2012
Carl Zeiss Medtec, Inc
All Rights Reserved
Page 1 of 1

Bp 240 / 135

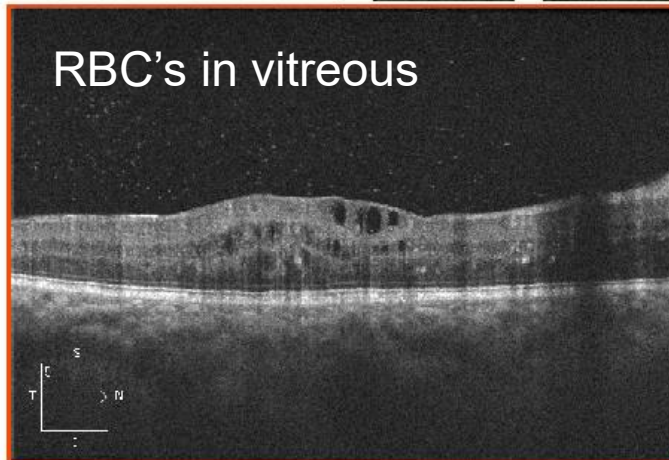
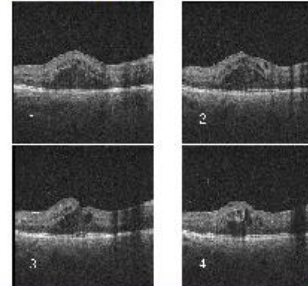
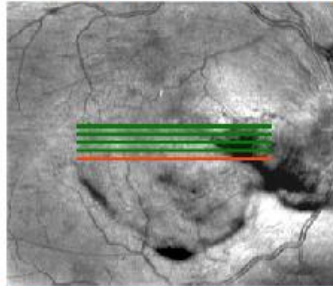
High Definition Images: HD 5 Line Raster

OD OS

Scan Angle: 0°

Spacing: 0.25 mm

Length: 6 mm

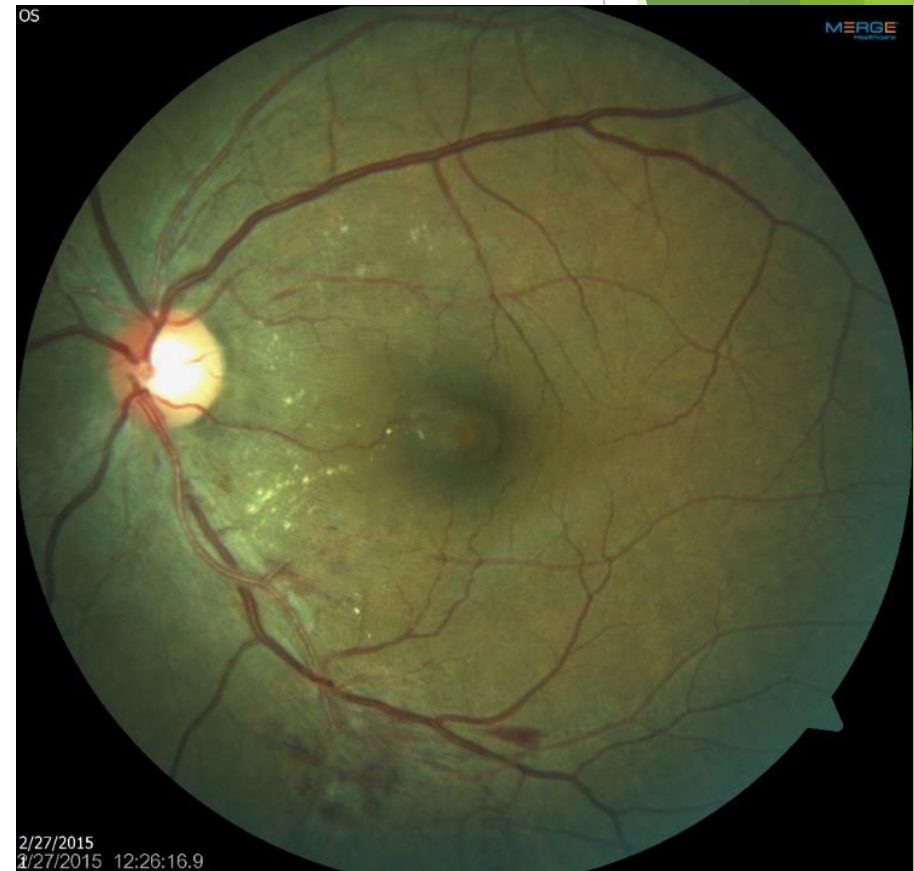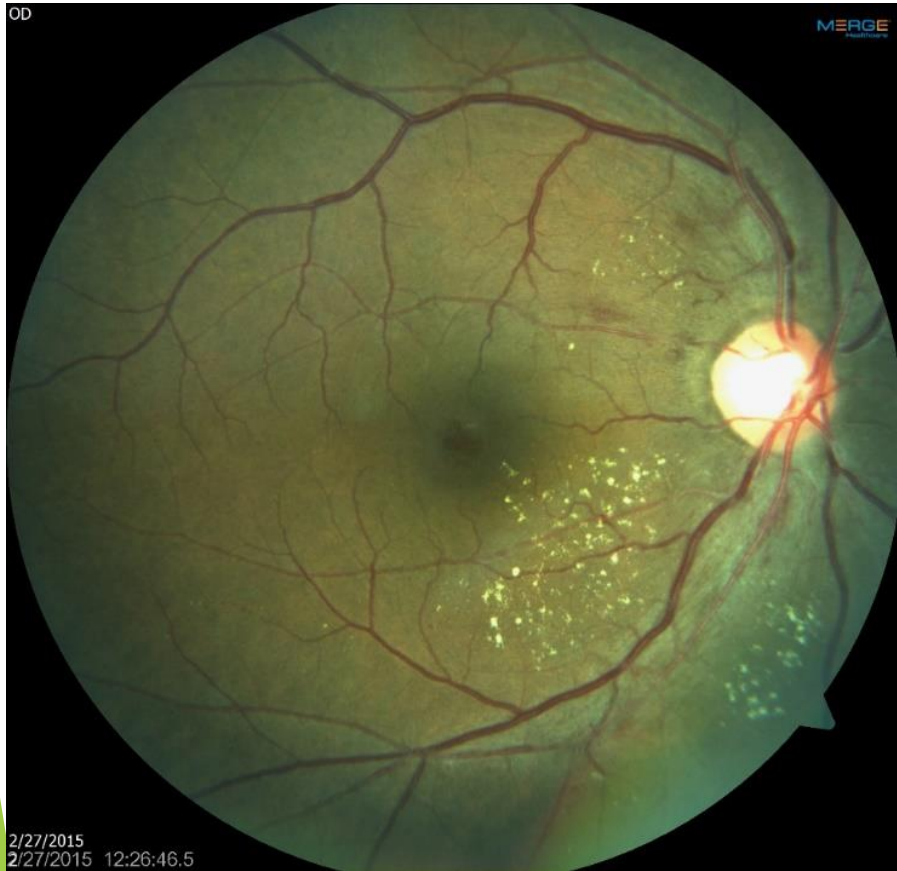


Comments
Acquired using enhanced depth mode

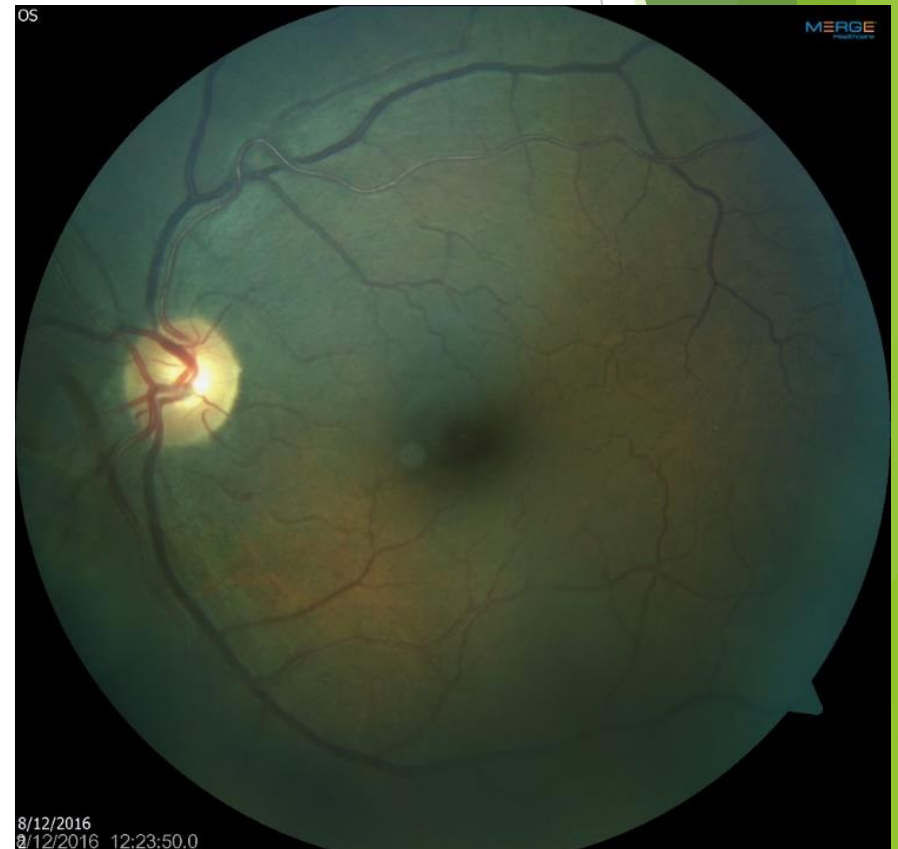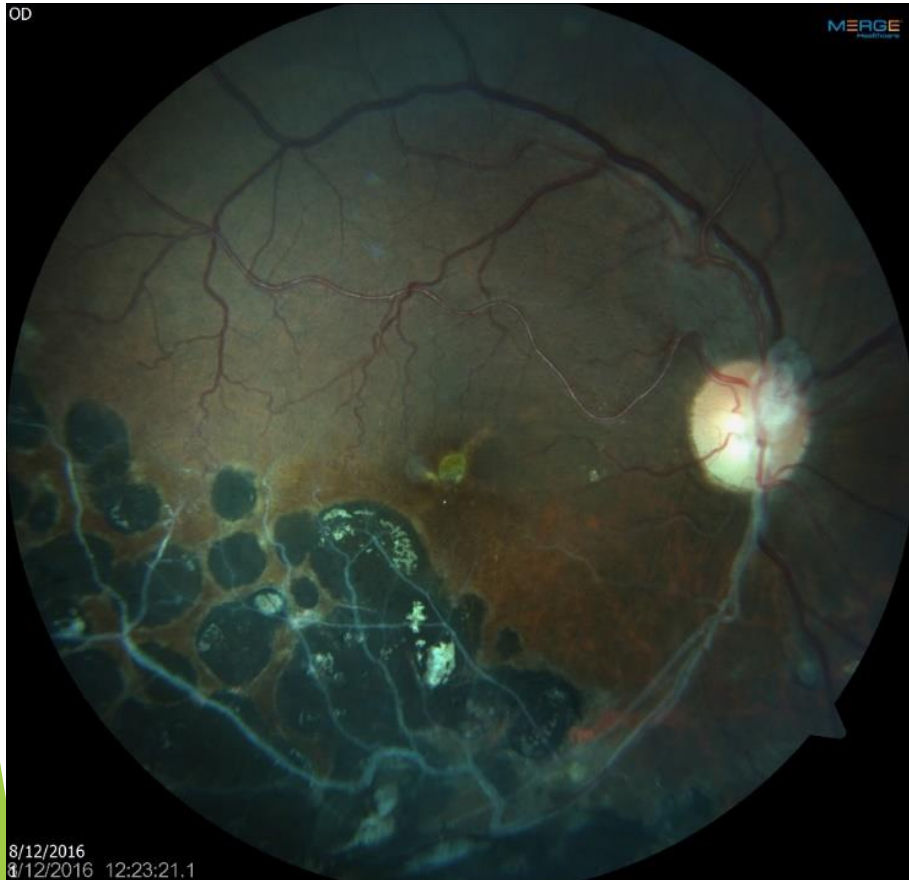Doctor's Signature

SW Ver: 6.0.1.24
Copyright 2012
Carl Zeiss Medtec, Inc
All Rights Reserved
Page 1 of 1

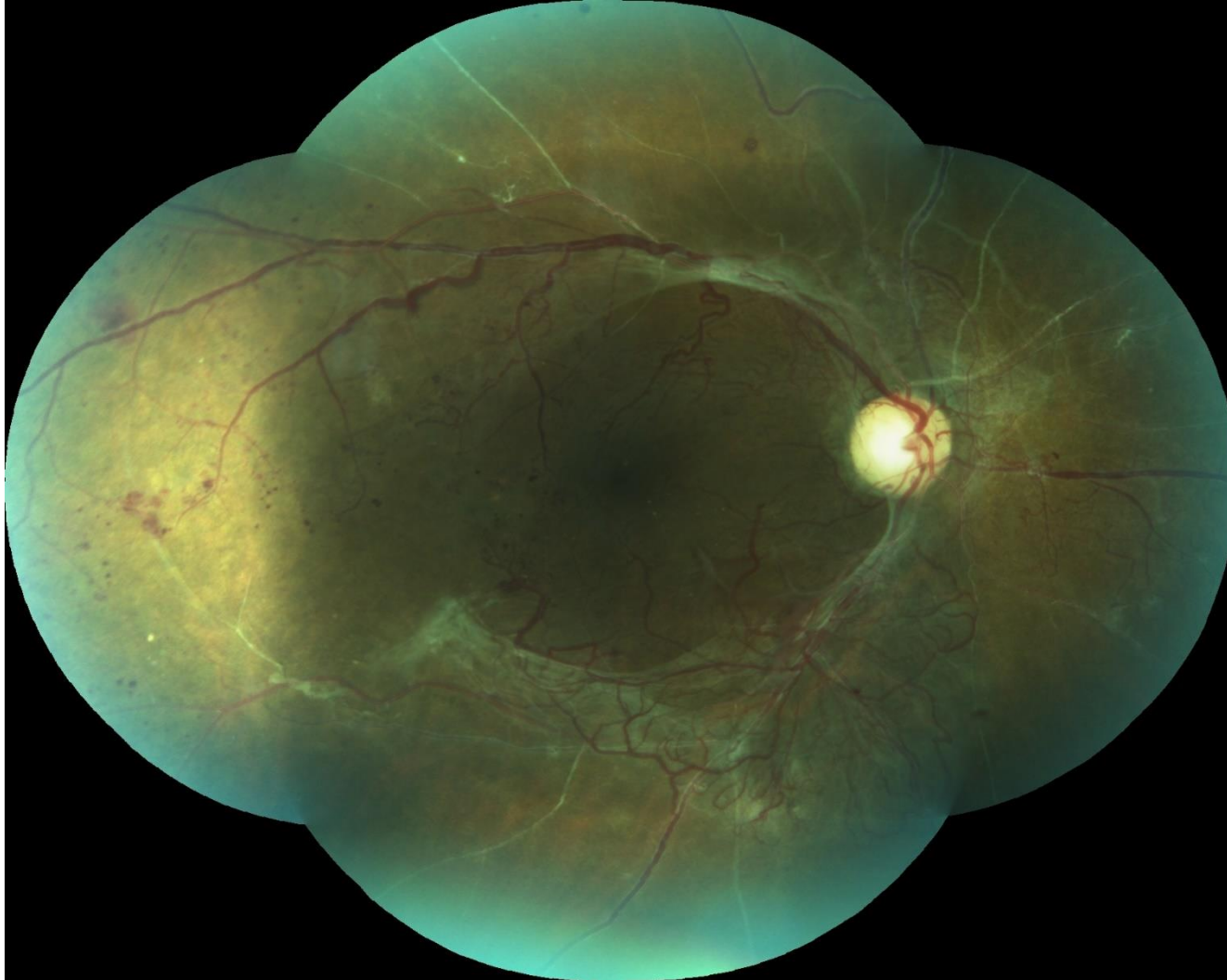
HTN retinopathy 20/20 OU



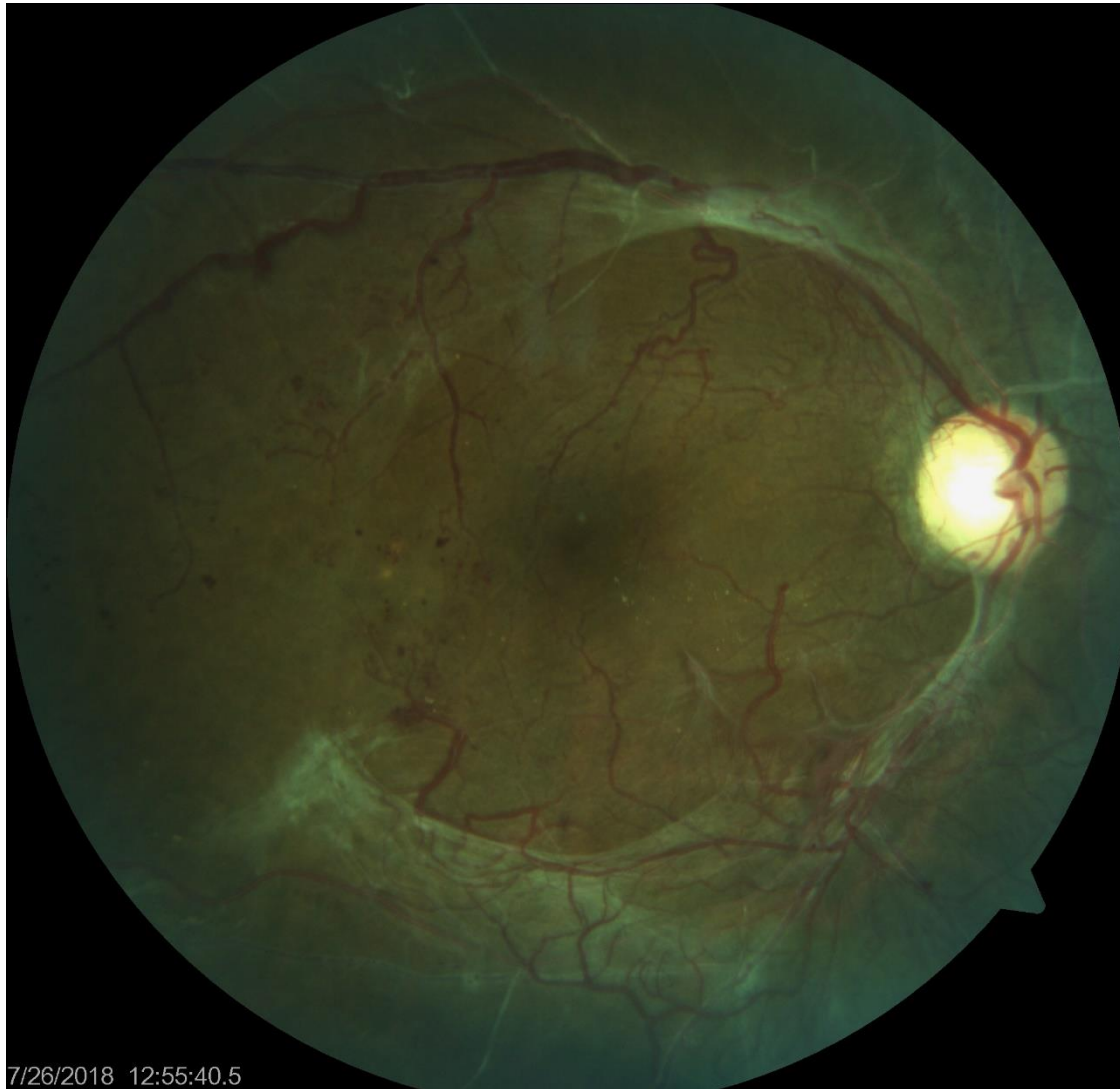HTN vasculopathy



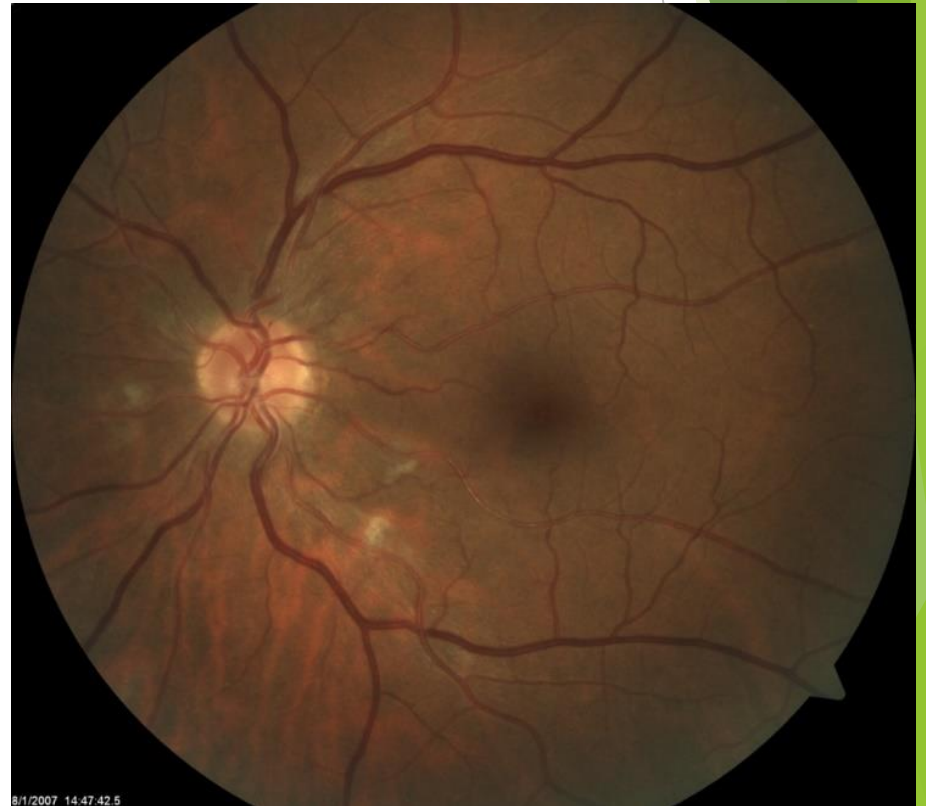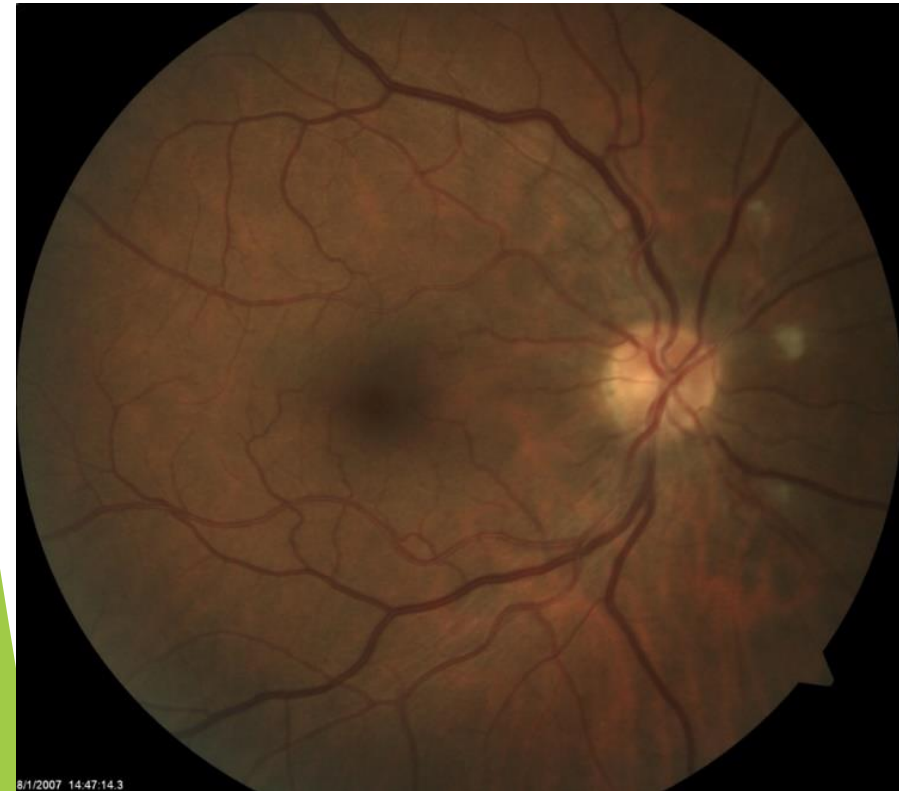HTN vasculopathy and PDR



HTN vasculopathy and PDR



CWS S/P MI with angioplasty



Eale's Disease

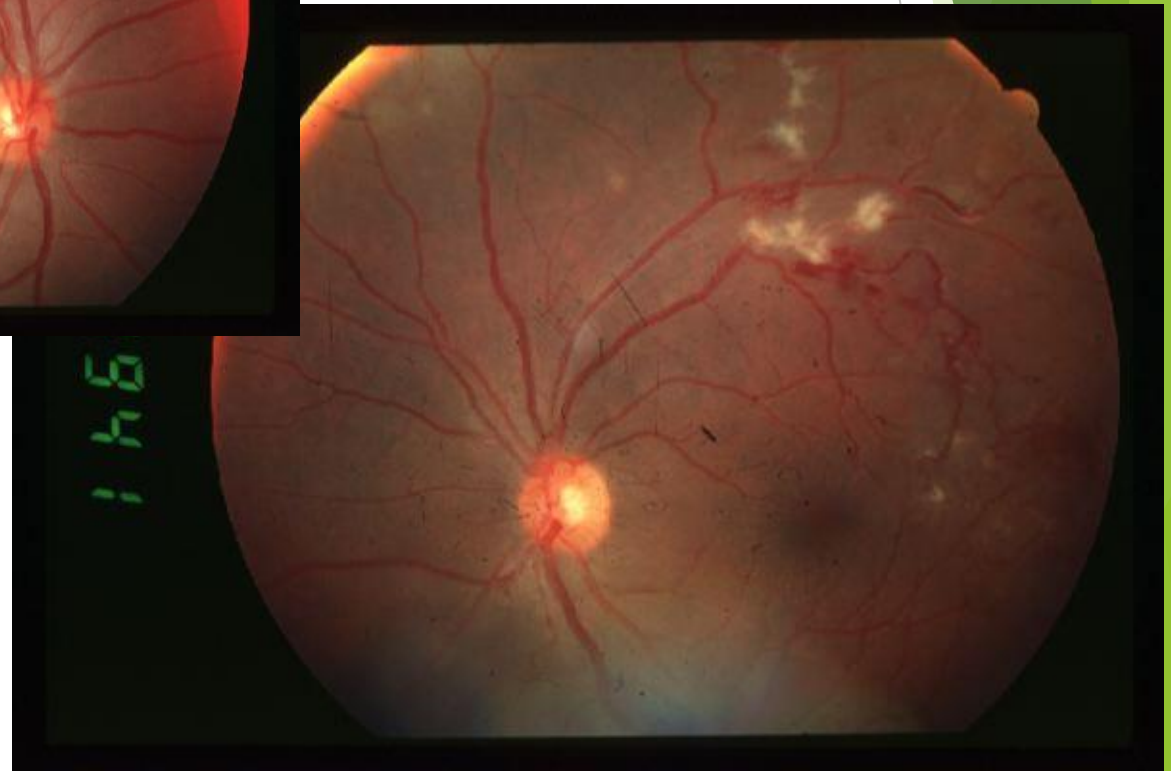
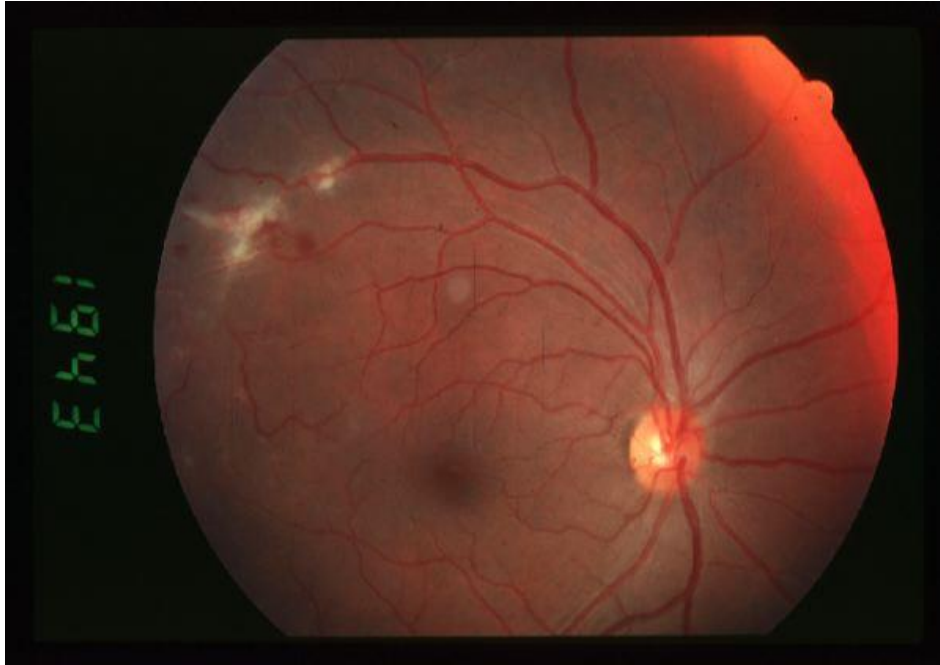- ▶ Idiopathic vasculopathy affecting healthy, young adults. India, Pakistan, and Afghanistan / Middle East
- ▶ Usually strikes patients in their twenties or thirties. M>F ? TB protein



Eale's Disease

- ▶ Retinal vascular sheathing and exudative sheathing in the periphery
- ▶ CME, vitreal cells, anterior chamber cells/flare, and peripheral retinal non-perfusion
- ▶ Neovascularization of the retina, disc, and iris are possible
- ▶ Treatment consists of PRP + / - anti VEGF

Eale's disease



Coat's Disease

- ▶ Idiopathic retinal condition consisting of telangiectatic and aneurysmal vessels with significant exudation
- ▶ Adolescent and adult forms
- ▶ Males 3x females ; 80-95% unilateral
- ▶ Leukocoria, poor vision, strabismus
- ▶ * What are the other main causes of leukocoria in children?

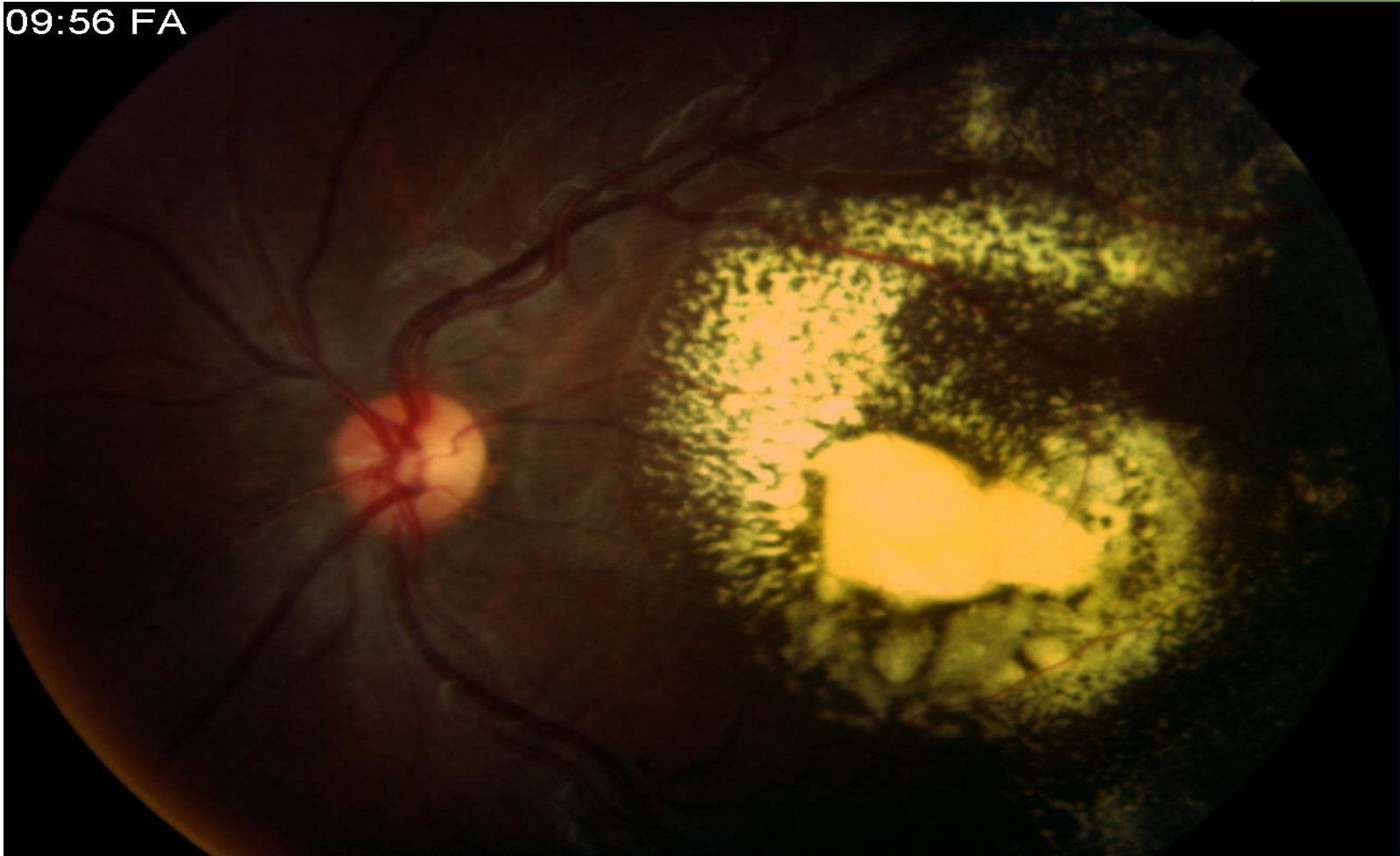
Coat's Disease



- ▶ Cholesterol issues in adult cases
- ▶ Clinical picture variable
- ▶ IVFA / OCTA most helpful tool in making diagnosis
- ▶ Progressive with exacerbations and remissions
- ▶ Tx with photocoagulation, possibly combined with anti-VEGF or kenalog

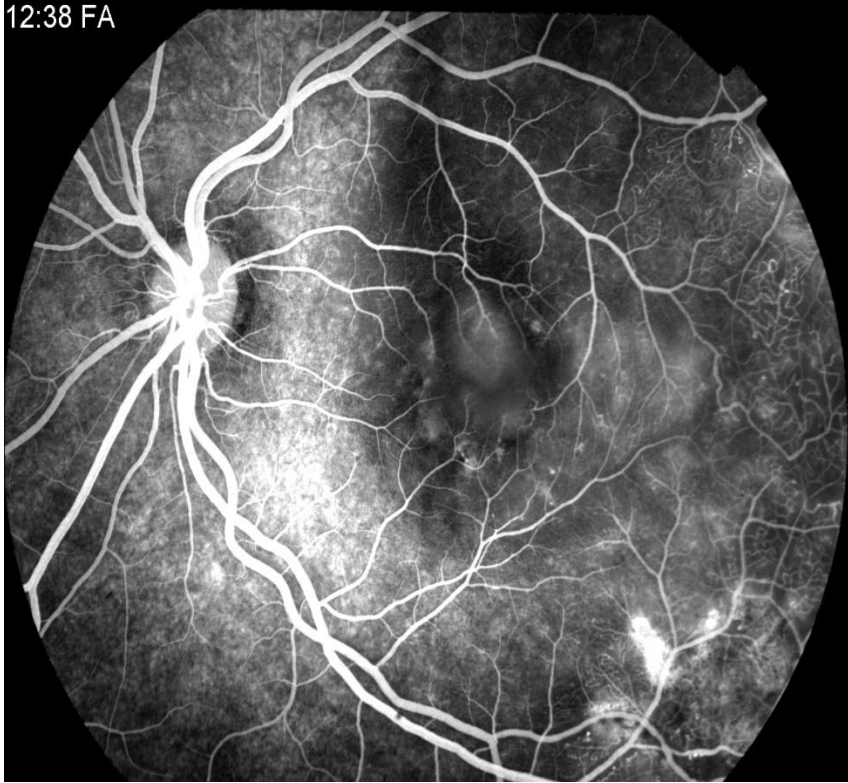
Coat's disease (images courtesy Dr. Dan Neely)

09:56 FA

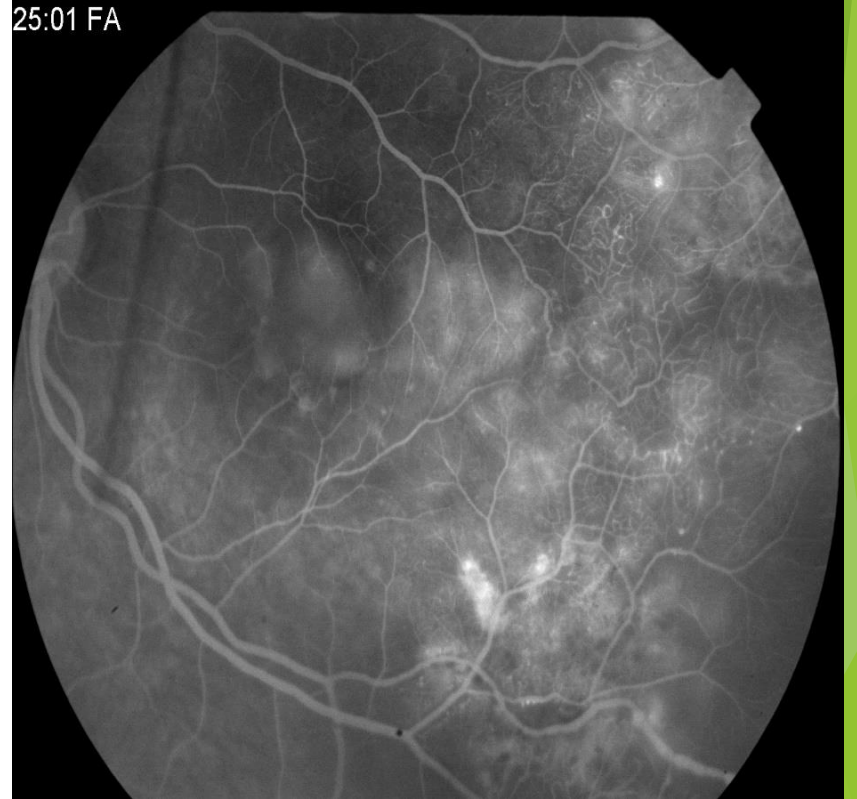


Coat's IVFA

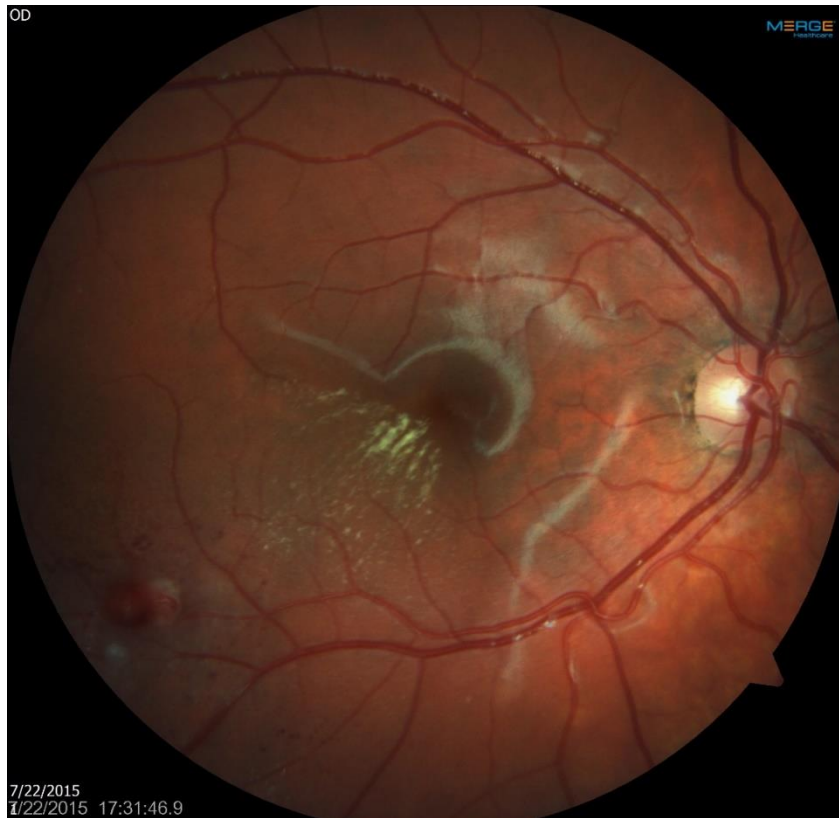
12:38 FA



25:01 FA

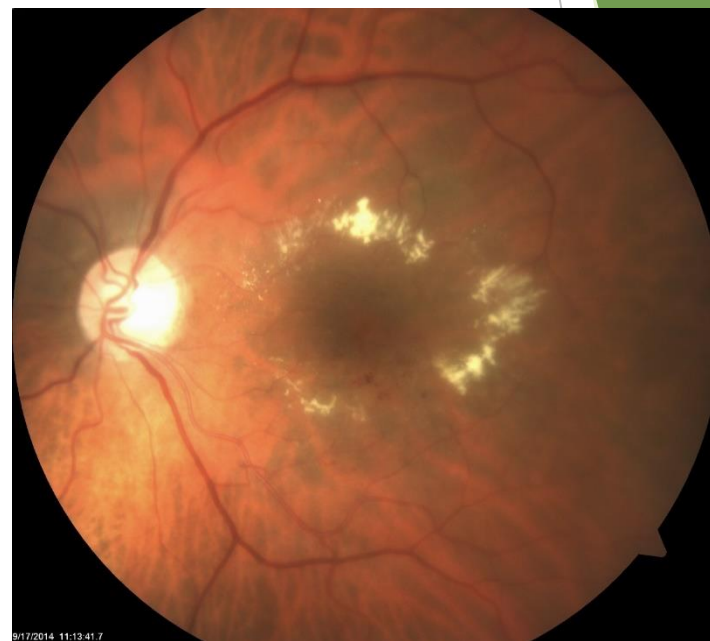


Coat's disease

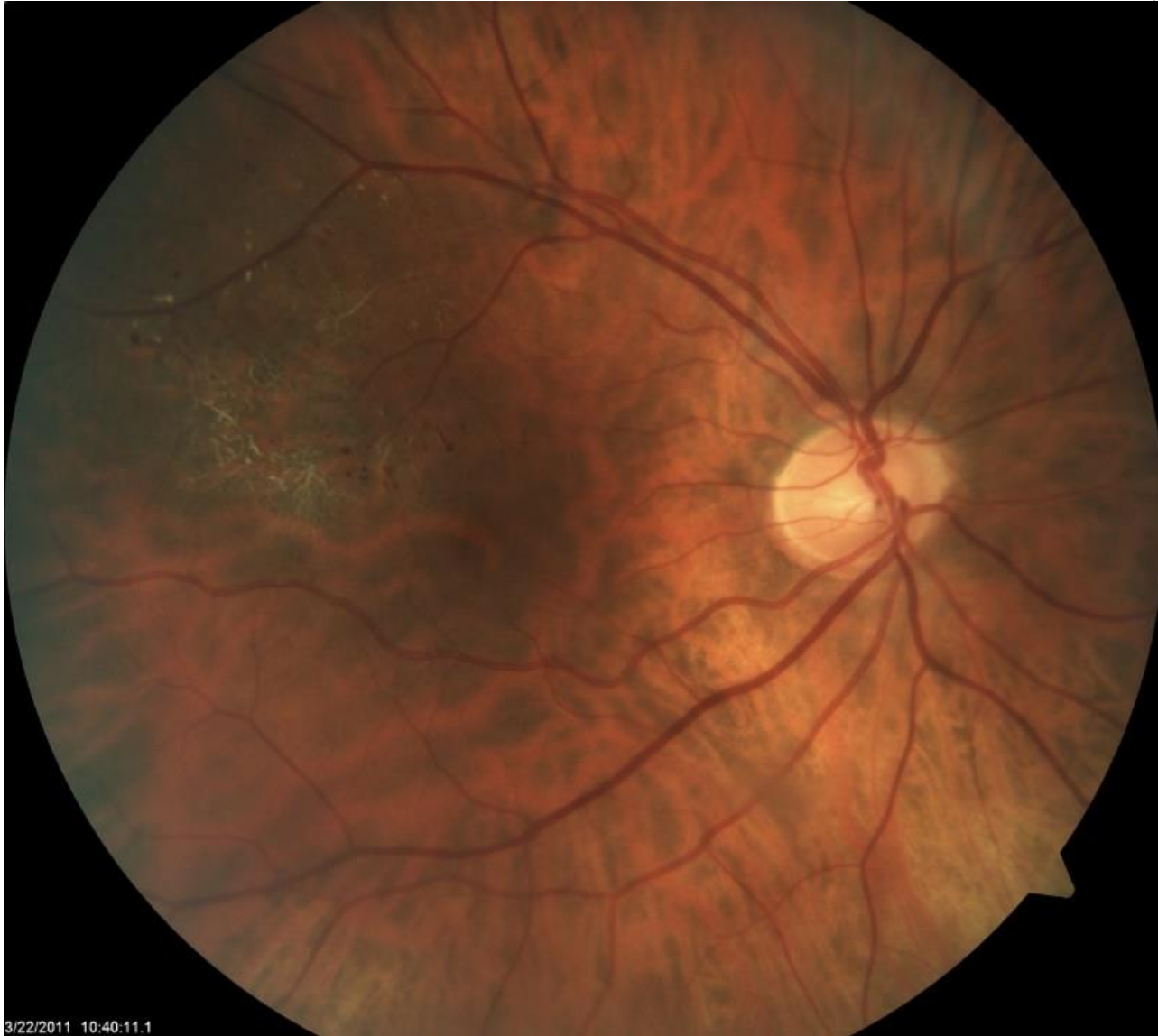

Macular Telangiectasia Type I

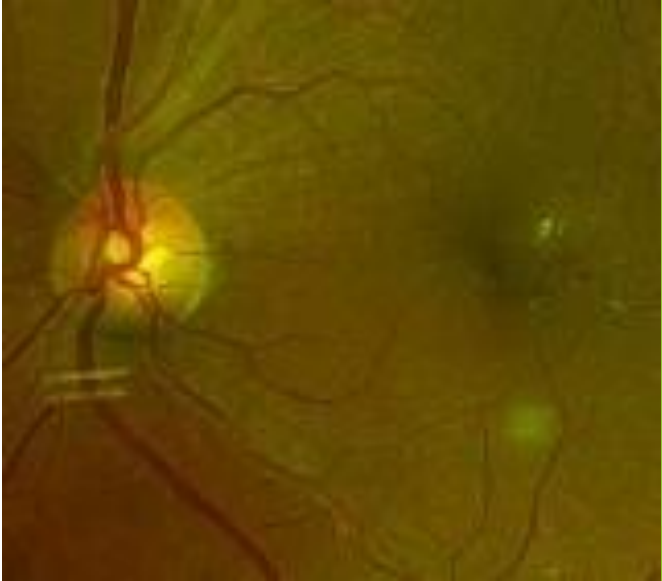
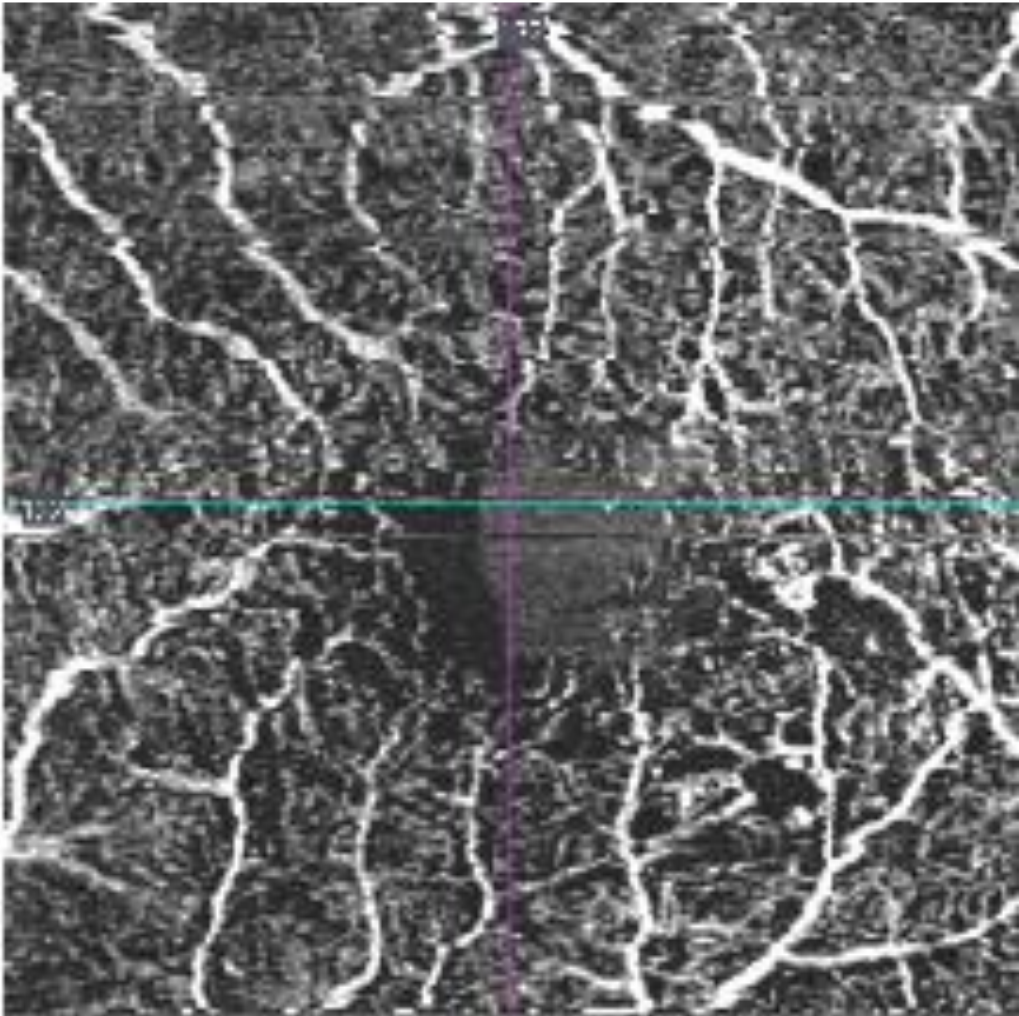
- ▶ Unilateral
- ▶ Mostly males, no racial predilection
- ▶ Mean onset 40 years old
- ▶ Prominent, visible telangiectatic capillaries
- ▶ Capillary drop out on OCTA
- ▶ Lipid exudation
- ▶ Macular edema
- ▶ Exacerbations and remissions
- ▶ IVFA, OCT / OCTA to confirm exudative edema
- ▶ Treat with laser photocoagulation, +/- anti VEGF or steroids



Macular Telangiectasia Type I



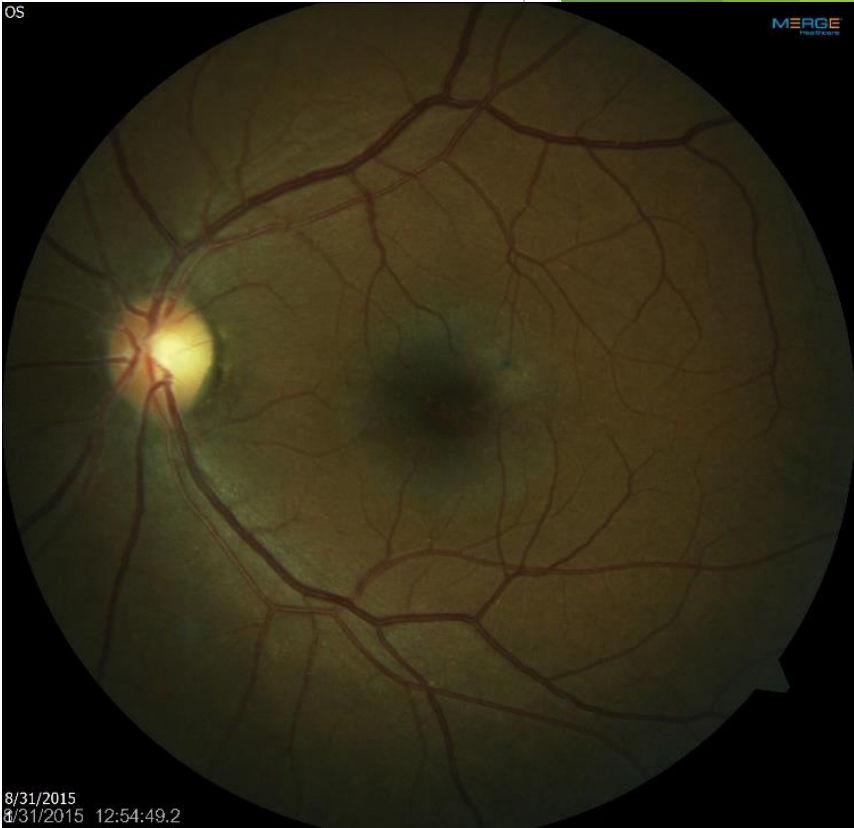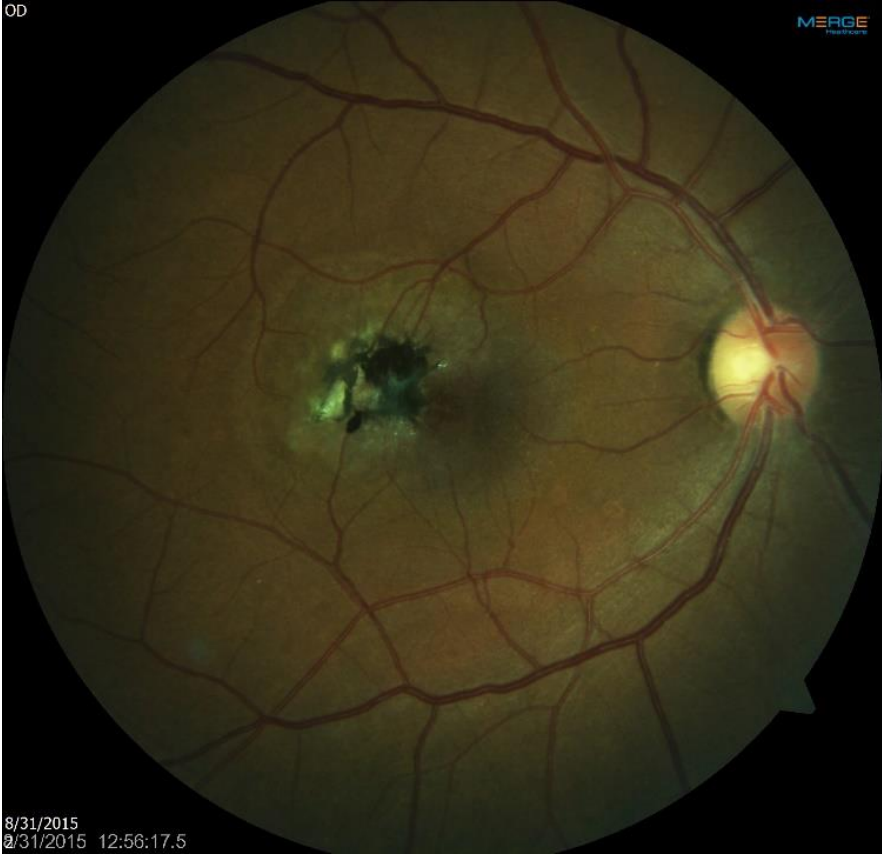
Mac Tel Type I



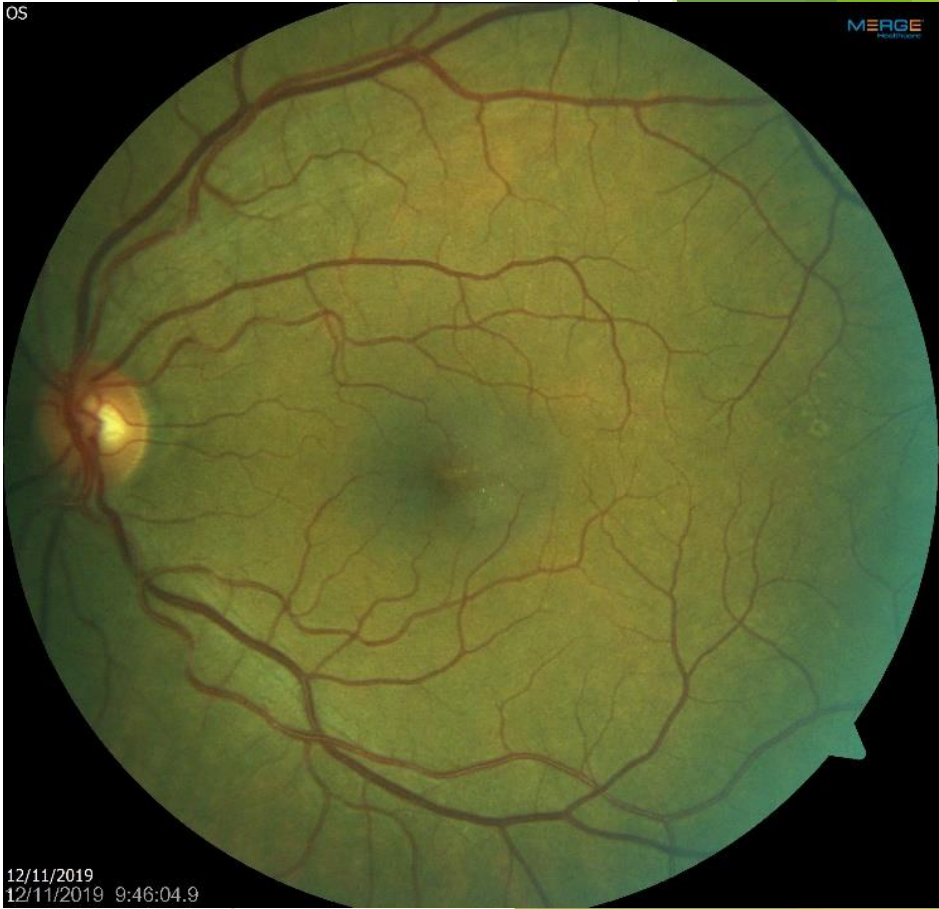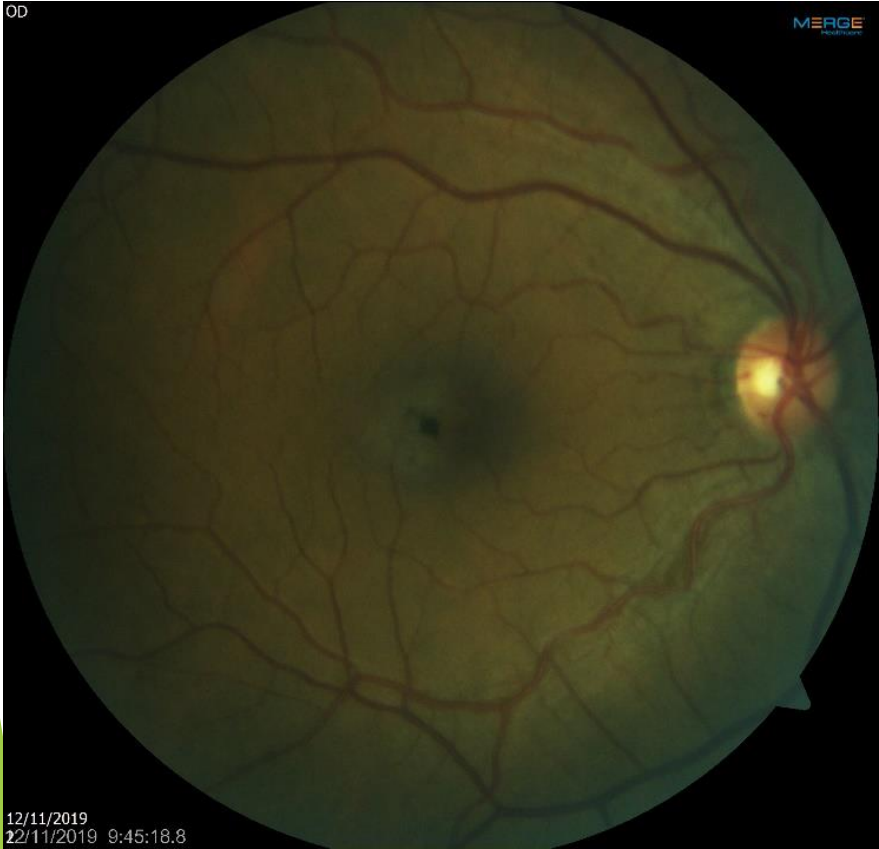Macular Telangiectasia Type II

- ▶ No gender or racial predilection
- ▶ Mean age of onset 55 years old, bilateral
- ▶ Mueller cell depletion
- ▶ Little to no exudation
- ▶ Parafoveal graying of the retina, parafoveal telangiectasias, crystalline deposits, macular edema
- ▶ ILM drape on OCT
- ▶ Two subtypes: proliferative (1/3) and non-proliferative (2/3)
- ▶ Proliferative develop SRNVM and subsequent scarring
- ▶ Limited treatment options for non-proliferative
- ▶ Anti-VEGF for proliferative

Macular telangiectasia Type II



Macular Telangiectasia Type II

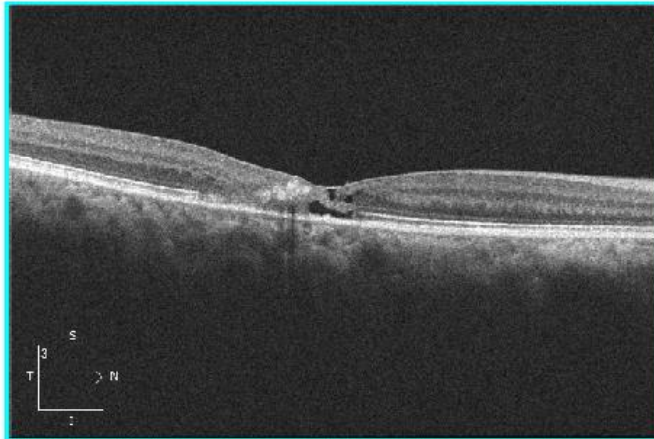
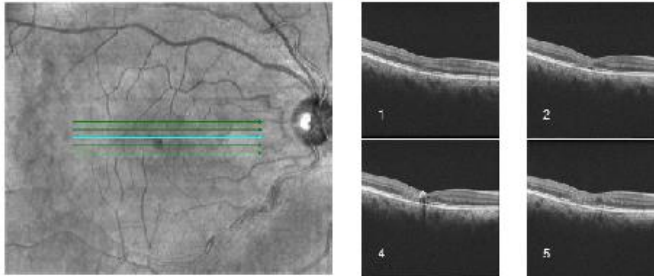


ILM Drape Mac Tel Type II

Name: _____
ID: _____ Exam Date: _____ CZMI
DOB: _____ Exam Time: 12:51 PM
Gender: _____ Serial Number: 4000-10970
Technician: _____ Signal Strength: 9/10

High Definition Images: HD 5 Line Raster **OD** **OS**

Scan Angle: 0° Spacing: 0.25 mm Length: 6 mm

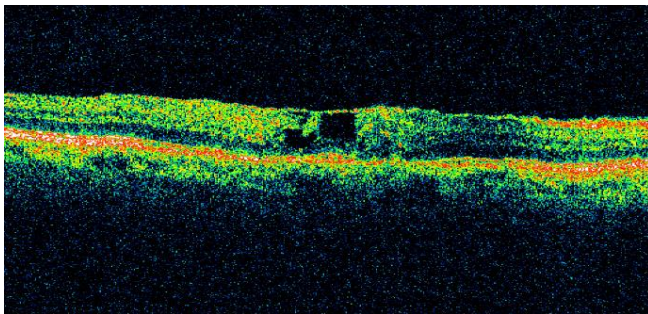


Comments: _____
Doctor's Signature: _____

SW Ver: 8.1.0.117
Copyright 2015
Carl Zeiss Meditec, Inc
All Rights Reserved
Page 1 of 1

ILM Drape in Mac Tel II

Also get right angle vessels in OCTA / IVFA



High Definition Images: HD 5 Line Raster OD OS

Scan Angle: 0° Spacing: 0.25 mm Length: 6 mm

A large OCTA/IVFA image showing right angle vessels in Mac Tel II. The image displays a cross-section of the retina with various layers highlighted in different colors (red, green, blue, yellow) against a black background. The ILM drape is visible as a distinct layer. The image is framed with a cyan border. A small inset image shows a top-down view of the scan area with three horizontal lines indicating the scan location. To the right of the inset are two columns of smaller images, labeled '2' and '4', showing different cross-sections of the retina. A coordinate system is visible in the bottom left corner of the main image, with 'S' for superior and 'T' for temporal.

Comments

Doctor's Signature

SW Ver: 6.0.2.81
Copyright 2012
Carl Zeiss Meditec, Inc
All Rights Reserved
Page 1 of 1

Macular Telangiectasia Type 2

- Right-angle venules
- Capillary ectasia

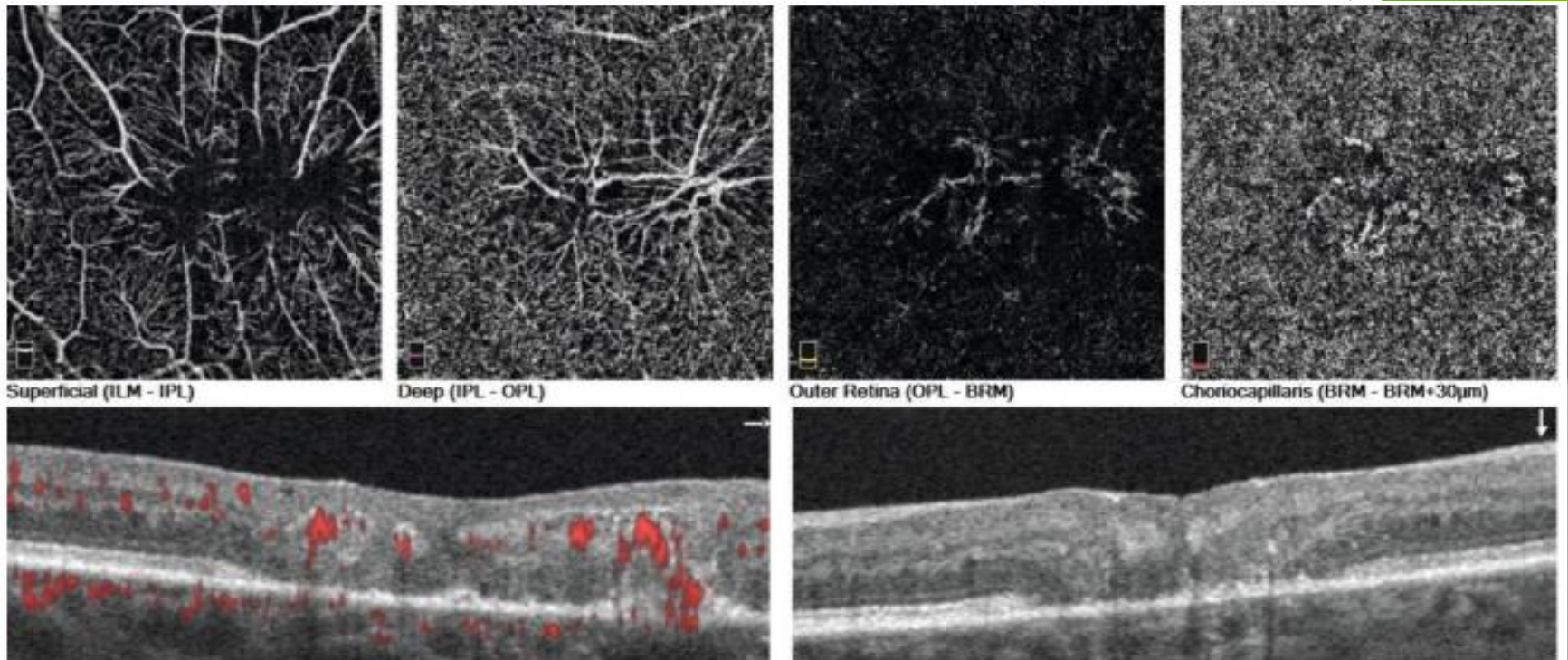
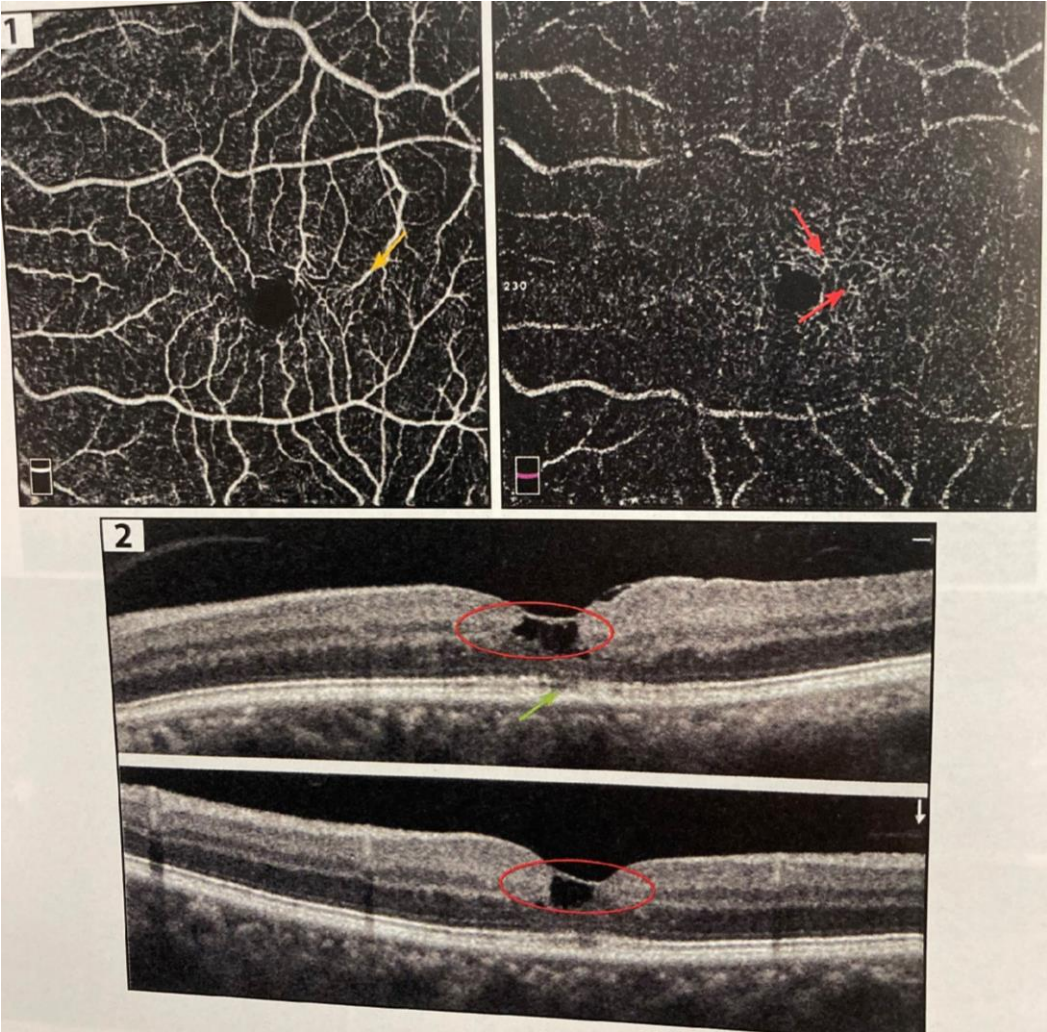


Photo: Optovue



Macular telangiectasia Type II



ILM drape

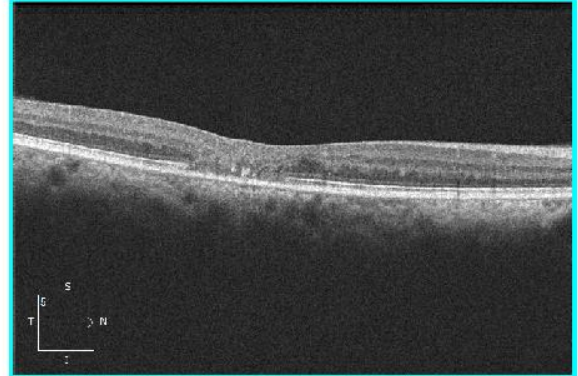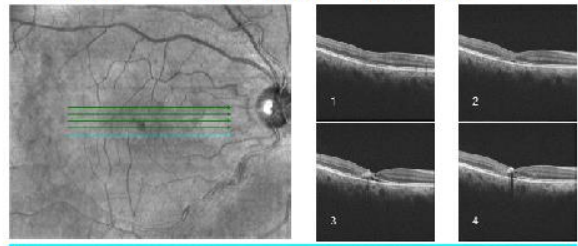
Photo: Julie Rodman, OD

ONL / Photoreceptor loss in Mac Tel II

Name:
 ID:
 Exam Date: 12:51 PM
 Exam Time: 12:51 PM
 Serial Number: 4000-10970
 Signal Strength: 9/10
 CZMI

High Definition Images: HD 5 Line Raster OD OS

Scan Angle: 0° Spacing: 0.25 mm Length: 6 mm



Comments

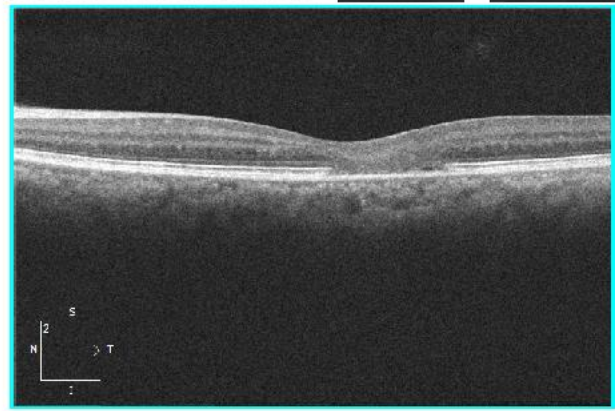
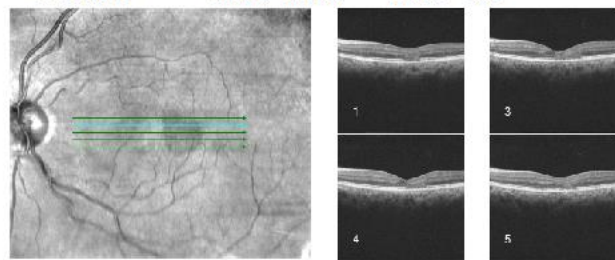
Doctor's Signature

SW Ver: 8.1.0.117
 Copyright 2015
 Carl Zeiss Meditec, Inc
 All Rights Reserved
 Page 1 of 1

Name:
 ID:
 Exam Date: 12:53 PM
 Exam Time: 12:53 PM
 Serial Number: 4000-10970
 Signal Strength: 10/10
 CZMI

High Definition Images: HD 5 Line Raster OD OS

Scan Angle: 0° Spacing: 0.25 mm Length: 6 mm



Comments

Doctor's Signature

SW Ver: 8.1.0.117
 Copyright 2015
 Carl Zeiss Meditec, Inc
 All Rights Reserved
 Page 1 of 1

Macular Telangiectasia Type

III

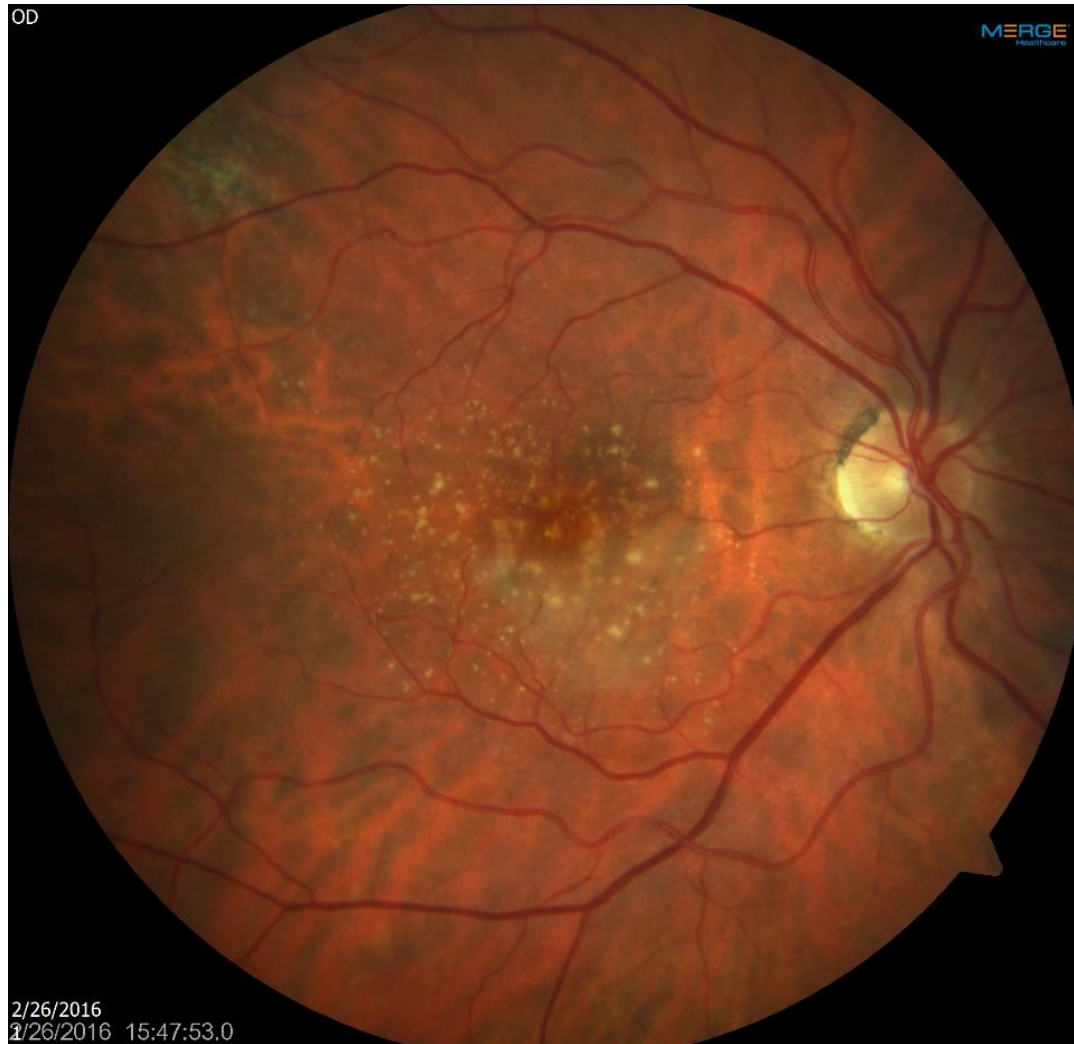- ▶ Very rare
- ▶ Bilateral
- ▶ Perifoveal capillary obliteration and telangiectasias
- ▶ Minimal exudation
- ▶ Associated with systemic or cerebral disease.
- ▶ Poorly understood



Middle maculopathy

- ▶ Paracentral acute middle maculopathy (PAMM)
- ▶ Older acute macular neuroretinopathy (AMN)
- ▶ PAMM affects middle retina (INL) and is an infarct of the intermediate capillary plexus
- ▶ AMN affects the outer retina (OPL/ONL/PIL line area) and is an infarct of the deep capillary plexus
- ▶ Can be younger supposedly healthy patients
- ▶ Can have a flu like prodrome
- ▶ Unilateral or bilateral
- ▶ Sudden onset of central or paracentral scotoma
- ▶ Slow resolution of defect, but may be permanent
- ▶ Can be seen with diabetes and other vascular or retinal vascular conditions / vasculitis
- ▶ No treatment other than underlying disease management

Middle Maculopathy (PAMM)



Middle Maculopathy (PAMM)

Gender: Female
Doctor:

Serial Number: 4000-10970
Signal Strength: 6/10

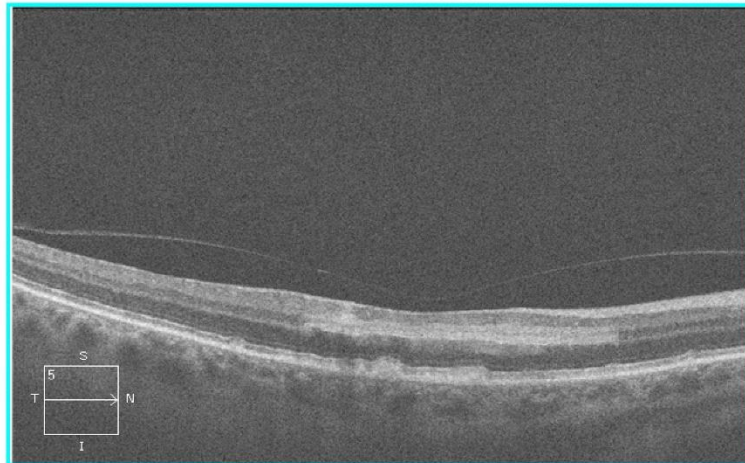
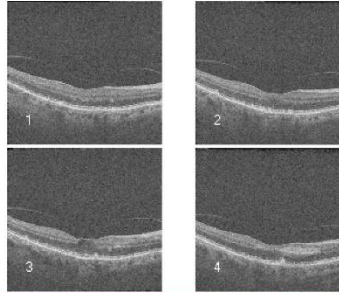
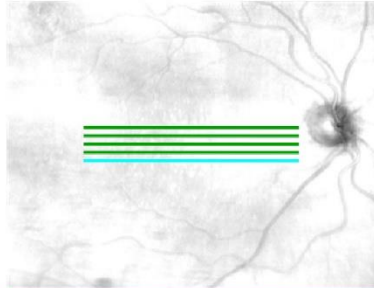
High Definition Images: HD 5 Line Raster

OD OS

Scan Angle: 0°

Spacing: 0.25 mm

Length: 6 mm



Comments

Doctor's Signature

SW Ver: 6.0.2.81
Copyright 2012
Carl Zeiss Meditec, Inc
All Rights Reserved
Page 1 of 1

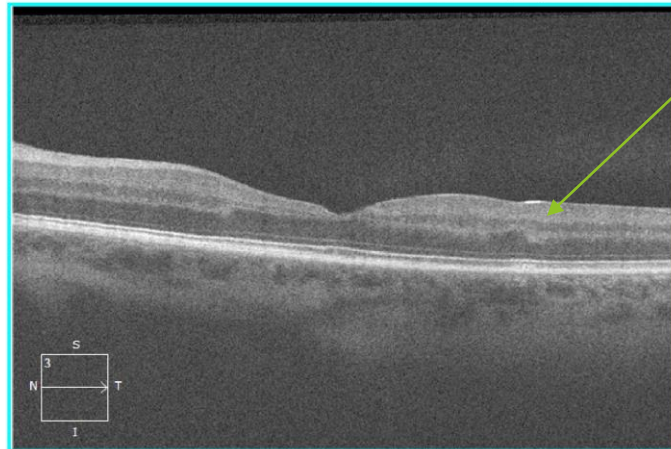
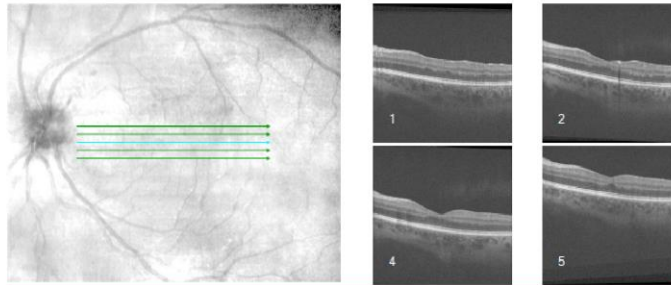
Old PAMM

Gender: Male Serial Number: 4000-10970
Technician: Operator, Cirrus Signal Strength: 8/10

High Definition Images: HD 5 Line Raster

OD OS

Scan Angle: 0° Spacing: 0.25 mm Length: 6 mm



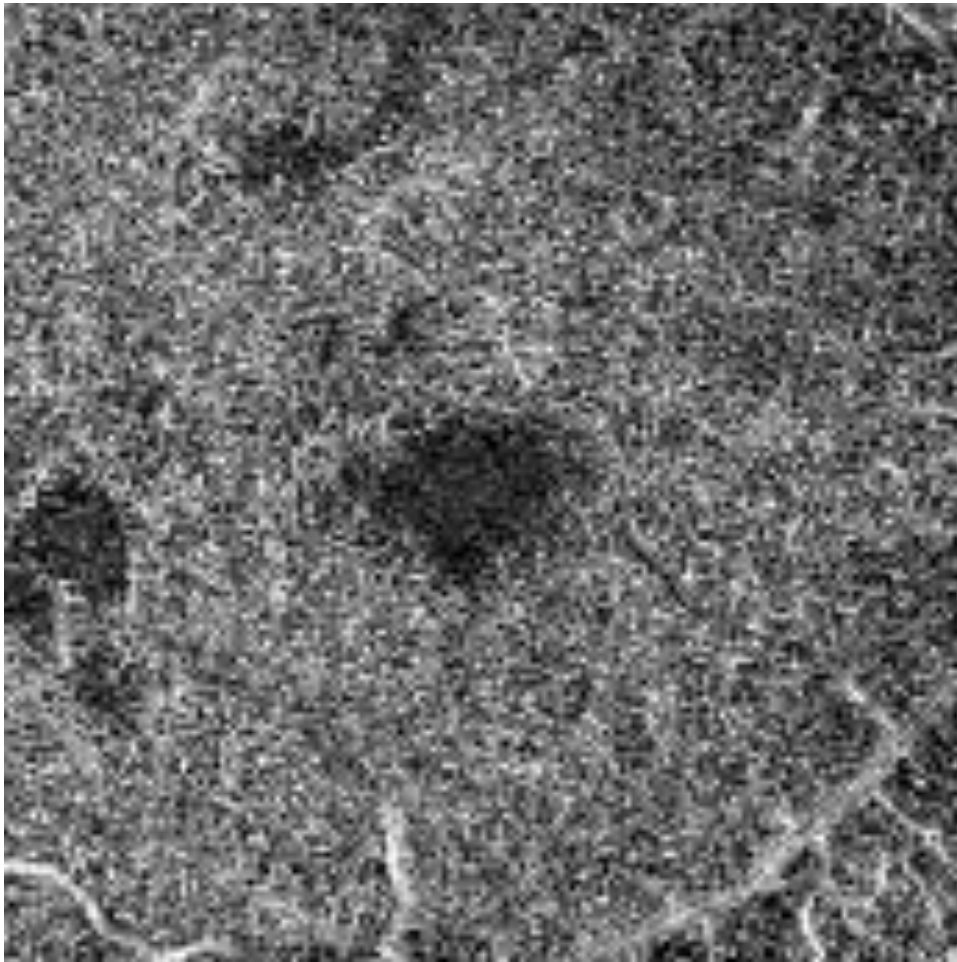
INL thinning with OPL elevation

Comments

Doctor's Signature

SW Ver: 8.1.0.117
Copyright 2015
Carl Zeiss Meditec, Inc
All Rights Reserved
Page 1 of 1

PAMM deep capillary plexus OCTA



PAMM

- ▶ 2019 study of 45 BRVO patients, 21 CRVO patients, and 57 matched normals showed resolved PAMM lesions in the fellow eye of 71% of CRVO patients, 71% of BRVO patients, and in at least one eye of 19% of the matched normals (all of which had systemic HTN)
- ▶ *Acta Ophthalmologica 2019 Maltsev, DS et al*
- ▶ So the presence of resolved PAMM lesions may indicate a higher risk of RVO

Artery Occlusions

- ▶ Embolus (frequent) vs. local thrombosis (rare)
- ▶ Other factors include vasospasm, necrosis, GCA (10%), and hyperhomocystinemia
- ▶ Can affect the ophthalmic artery, cilioretinal arteries, and retinal arteries
- ▶ Hollenhorst plaque : 3X mortality
- ▶ Risk after facial filler injections (particulate material forced backward through the vascular system into the ophthalmic artery / central retinal artery)
- ▶ 2.3 x risk of CRAO in patients with diabetes

Types of embolic plaques

- ▶ Hollenhorst (cholesterol) ; about 80% of retinal emboli
- ▶ Calcific; about 6 % of retinal emboli
- ▶ Fibrino-platelet; about 14% of retinal emboli

- ▶ H-H plaque mortality:
 - ▶ 15 % @ 1 year
 - ▶ 29 % @ 3 years
 - ▶ 54% @ 7 years

CRAO

- ▶ CRAO characterized by sudden, painless, profound loss of vision. VA count fingers or worse in 75-90%
- ▶ Possible amaurosis fugax
- ▶ Retina can appear normal for first hour or so

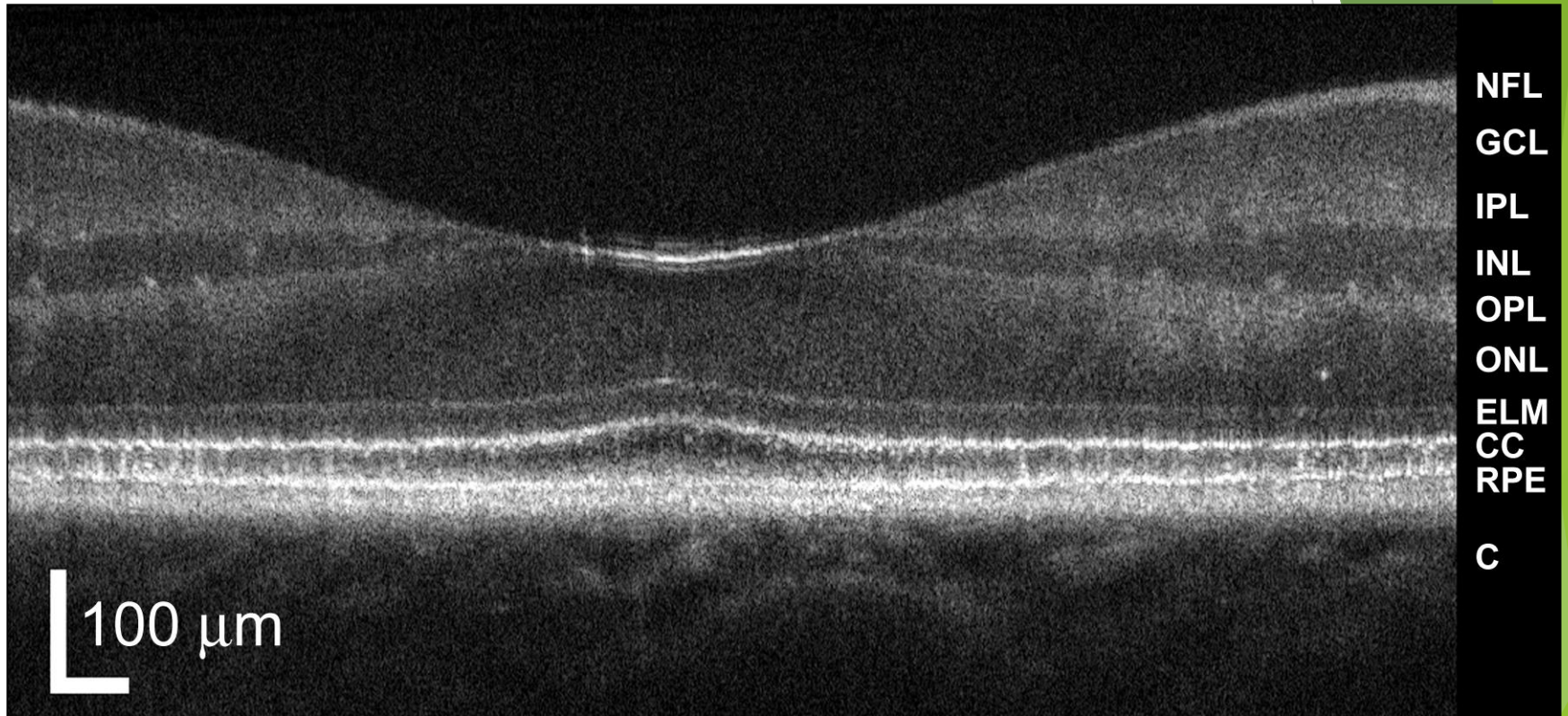
CRAO

- ▶ Emboli visible in only 20% of cases (carotid, heart valves)
- ▶ Within hours the retina (posterior pole) becomes white and opaque due to ischemic NFL edema.
- ▶ Cherry red spot due to lack of ganglion cells in the foveola
- ▶ Box-car changes in retinal vessels due to lack of blood flow

Cherry Red Spot



Spectral Domain OCT



Courtesy of Dan Hammer, PSI

CRAO

- ▶ Over the course of about one month, the retinal appearance returns to normal
- ▶ Residual optic atrophy / vessel attenuation long term
- ▶ 25-40% of cases have some sparing of the macular area due to cilioretinal artery perfusion

CRAO

- ▶ Sparing can result in reasonable visual recovery
- ▶ Without cilioretinal vessel perfusion or short-term blockage, VA does not make a meaningful recovery in most cases
- ▶ NVI, NVD, NVE are very rare complications
- ▶ Why is that? Because the retina dies so quickly, it can not send out a signal for VEGF

CRAO


- ▶ Giant cell arteritis, drops in perfusion pressure, ONH drusen, sickle cell are non-embolic causes
- ▶ Life expectancy of 5.5 years compared to 15.4 years for age matched
- ▶ Treatment is notoriously ineffective
- ▶ Digital massage, IOP lowering (paracentesis), rebreathing in paper bag
- ▶ What are we really doing? Trying to dislodge the embolus.
- ▶ Possibly TPA?
- ▶ ? ND-YAG lysis of emboli
- ▶ ? Hyperbaric Oxygen

Intravenous TPA

- ▶ Very controversial
- ▶ Some deaths from cerebral and hepatic hemorrhaging with Streptokinase in various trials
- ▶ Short window to be effective: likely must be within 4.5 hours of symptom onset. Practically, this is very unlikely to occur
- ▶ One meta-analysis of available trials and studies showed that patients starting with VA of 20/200 or worse, the chance of improving to 20 / 100 or better was.....
- ▶ 17.7% without intervention
- ▶ 7.4% with traditional massage / paracentesis, etc.
- ▶ 50% with IV TPA within the first 4.5 hours
- ▶ Many questions remain, however
- ▶ Very controversial, risky

CRAO: Hyperbaric Oxygen therapy

- ▶ 2018 Meta Analysis of 7 RCT's, 251 patients
- ▶ Oxygen therapy delivered early = 5.61 X chance of improved vision
- ▶ 100% hyperbaric O₂ delivered soon after event for 9 or more total hours best



Types

- ▶ Believed to be four sub types of CRAO.....each with a unique natural history (SS Hayreh)
 - ▶ I) NA-CRAO
 - ▶ II) NA-CRAO with C-R artery sparing
 - ▶ III) Transient NA-CRAO
 - ▶ IV) Arteritic CRAO

CRAO

- ▶ Chance of any degree of visual recovery depends entirely upon sub-type and presence or absence of complete occlusion
 - ▶ Transient NA-CRAO and NA-CRAO with CR artery sparing may improve
 - ▶ NA-CRAO improvement is rare but can occur if occlusion was not complete
 - ▶ Arteritic CRAO very, very rarely improves
- ▶ Improvement possible over first seven days or so

BRAO

- ▶ BRAO's occur less frequently than do CRAO's (?) 68% have visible embolus
- ▶ A smaller embolus , usually temporal to the macula (80%)
- ▶ Appearance is similar but in a localized area
- ▶ Susac syndrome (triad of encephalopathy, BRAO's, and hearing loss) most common in young women.

BRAO

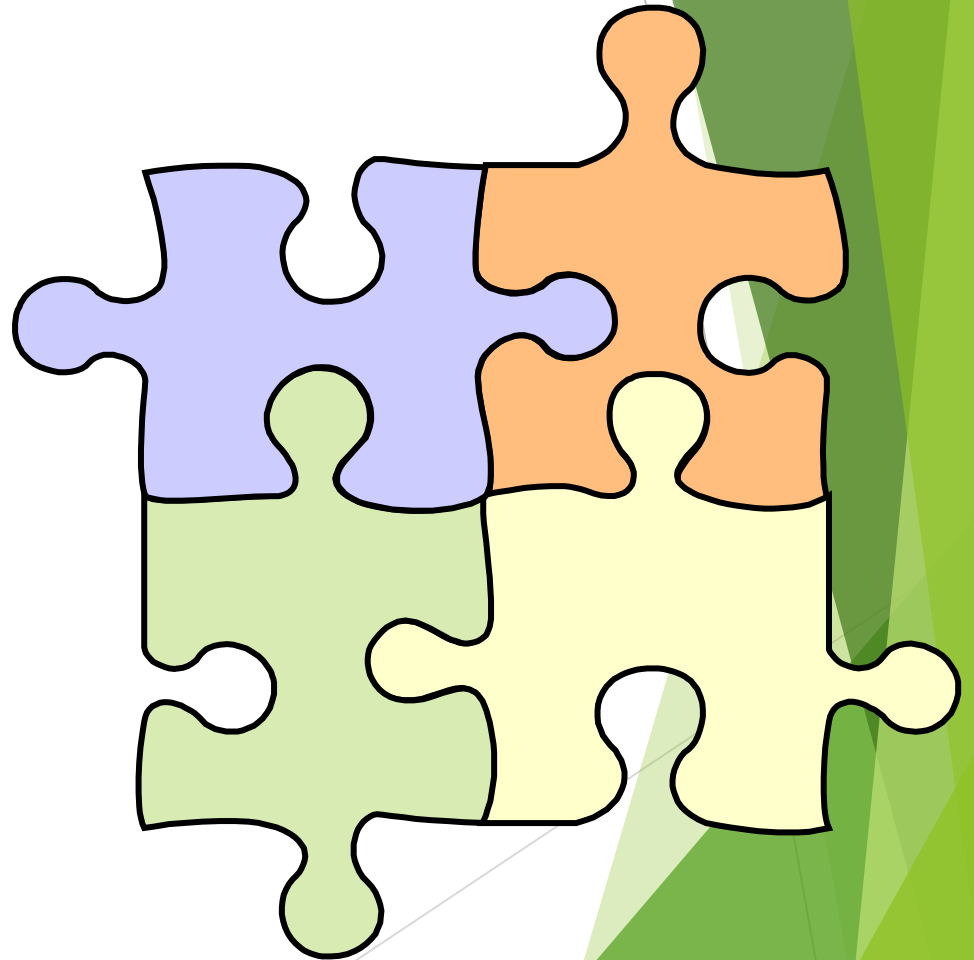
- ▶ VA usually good: scotoma!
- ▶ Survival rates are actually lower than for CRAO
- ▶ Cilioretinal and ophthalmic artery obstructions are also possible: think GCA!

BRAO / CRAO

- ▶ Ophthalmic artery obstruction mimics CRAO but vision is usually NLP, there is no cherry red spot, and the findings are more pronounced
- ▶ Get carotids (cholesterol) and heart valves (calcium) checked as indicated. Check for GCA
- ▶ Doppler of carotid checks neck only.....not sections in thorax and skull
- ▶ Presence of plaques may be more important than level of stenosis (microemboli)
- ▶ Why would that be? Because there is enough blood flow past the blockage to dislodge an embolus
- ▶ 60% of CRAO patients do not have high grade ipsilateral carotid stenosis. 30% do not even have mild stenosis
- ▶ High rate of atrial fibrillation (AF) with CRAO. Equal to rate seen in ischemic cerebral stroke, and much higher rate than matched normal patients. Need to evaluate through cardiologist with continual halter monitoring

Hollenhorst plaques

- ▶ What testing is indicated?
- ▶ Article by Varner with literature review yielded some surprises (Clinical Optometry 2013:5, 13-17)



Hollenhorst plaque

- ▶ HHP with No visual symptoms and known cardiovascular disease > No Doppler. Consider 81mg Aspirin
- ▶ HHP with visual symptoms > Doppler indicated
- ▶ HHP with no known cardiovascular disease > full cardiovascular work-up
- ▶ Carotid Auscultation for bruits not useful in patients with HHP but no visual symptoms

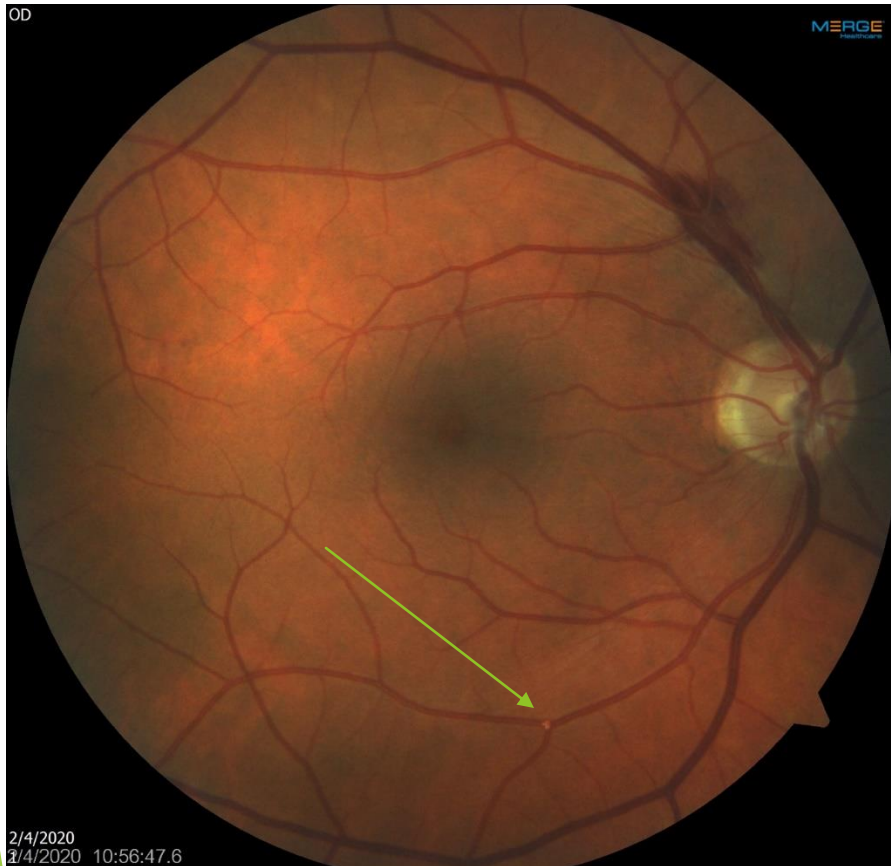What about acute (often “silent”) strokes with CRAO / BRAO

- ▶ One study found that 24% of patients with ocular TIA’s suffered an acute cerebral stroke at the same time. Often symptom free (“silent”)
- ▶ A second study looked at 33 patients with new onset CRAO or BRAO. 24% of them had concurrent acute (<14 days) cerebral strokes. Again, often “silent”
- ▶ Even more, newer reports as well finding the same thing

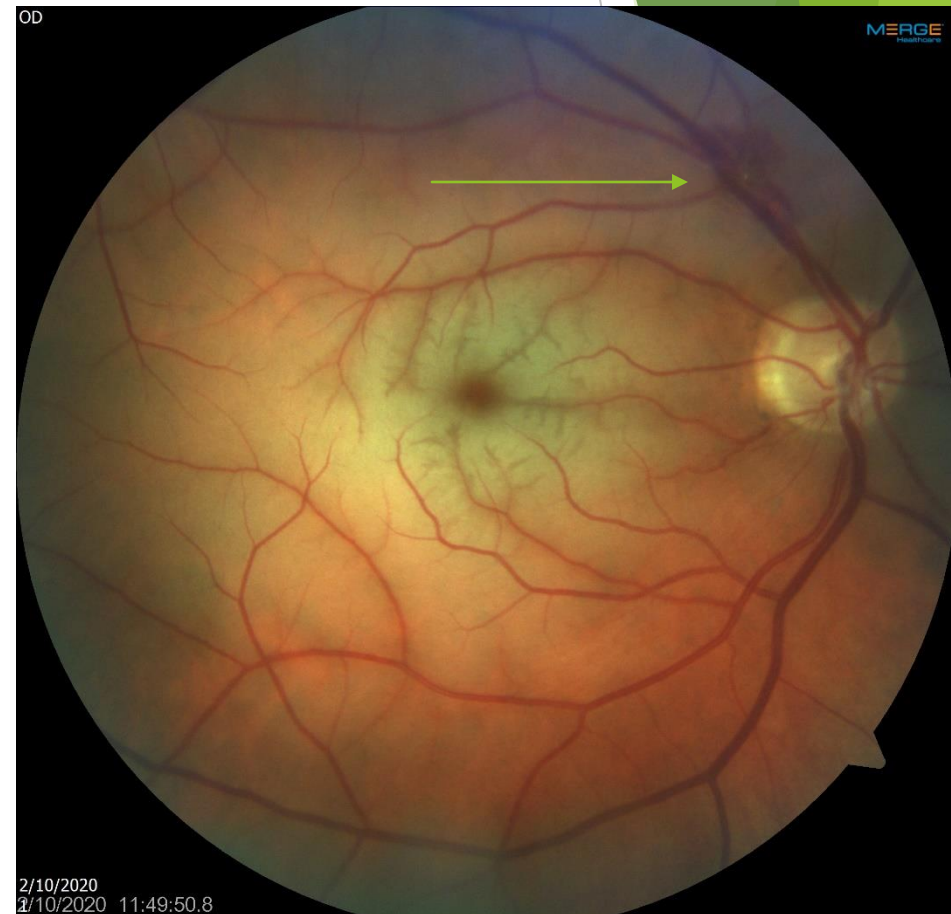Acute strokes with CRAO / BRAO

- ▶ Must run diffusion-weighted MRI, not standard T2-weighted MRI
- ▶ It better distinguishes acute infarcts from old lesions
- ▶ Recommendation from these studies, editorials, the American Heart Association and the National Stroke Association: Obtain emergent diffusion weighted brain MRI, preferably in a stroke center, on ALL patients with ocular TIA, BRAO, or CRAO
- ▶ Some controversy still, for several reasons (cost, what is then done, etc.)

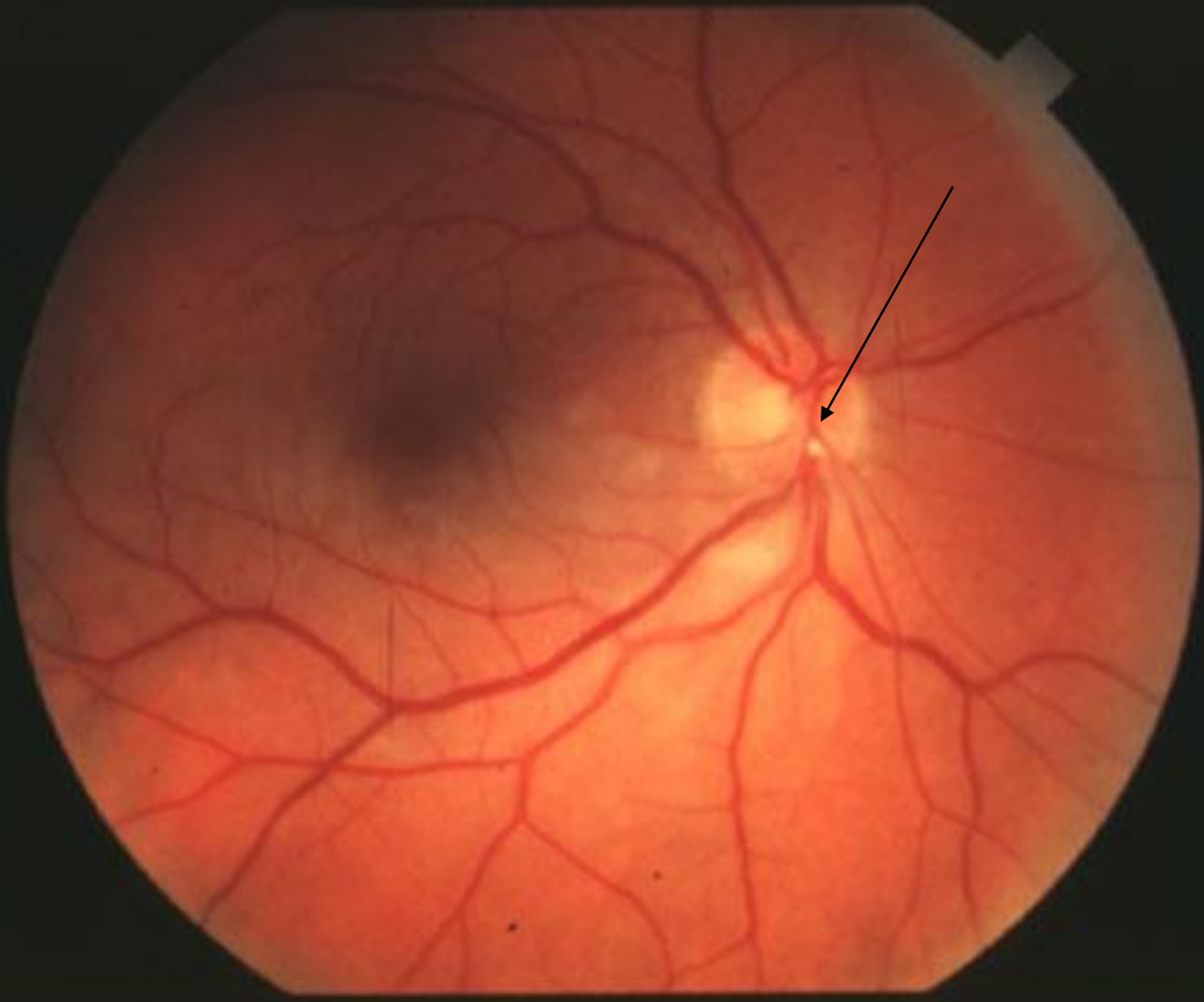
Hollenhorst Plaque-then CRAO



Six days later

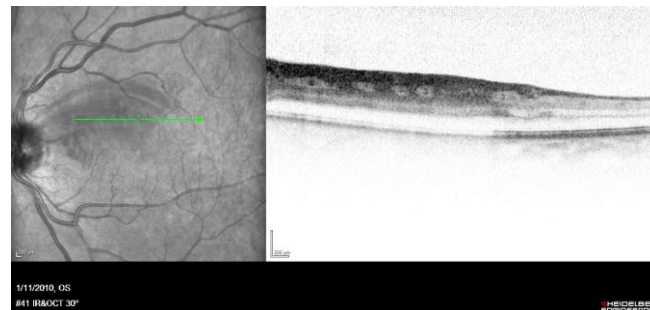
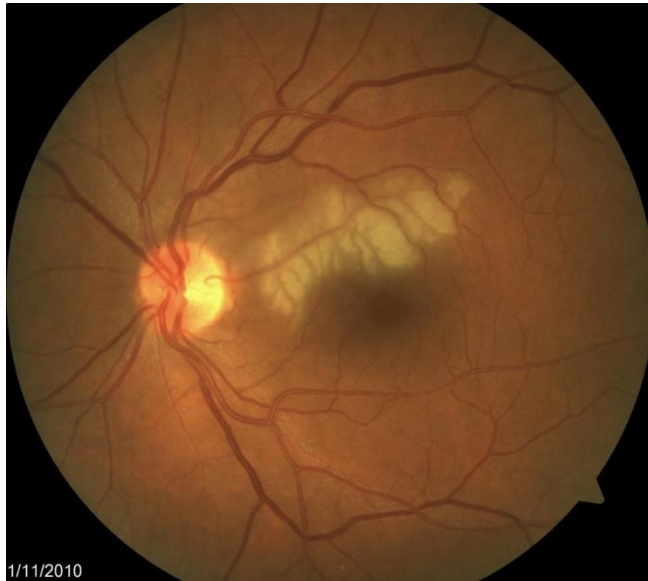

8607
A11

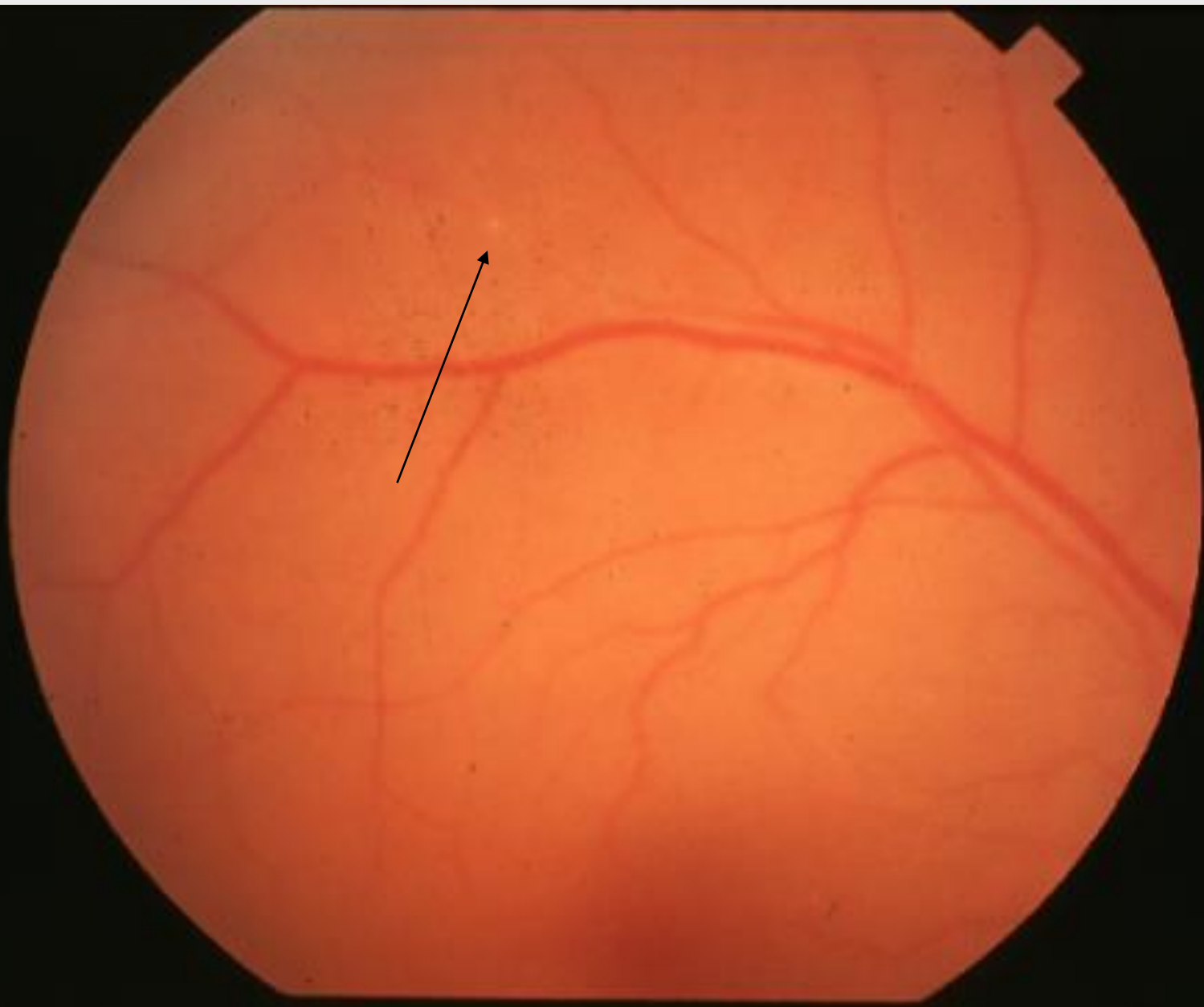


Cilioretinal Artery Occlusion

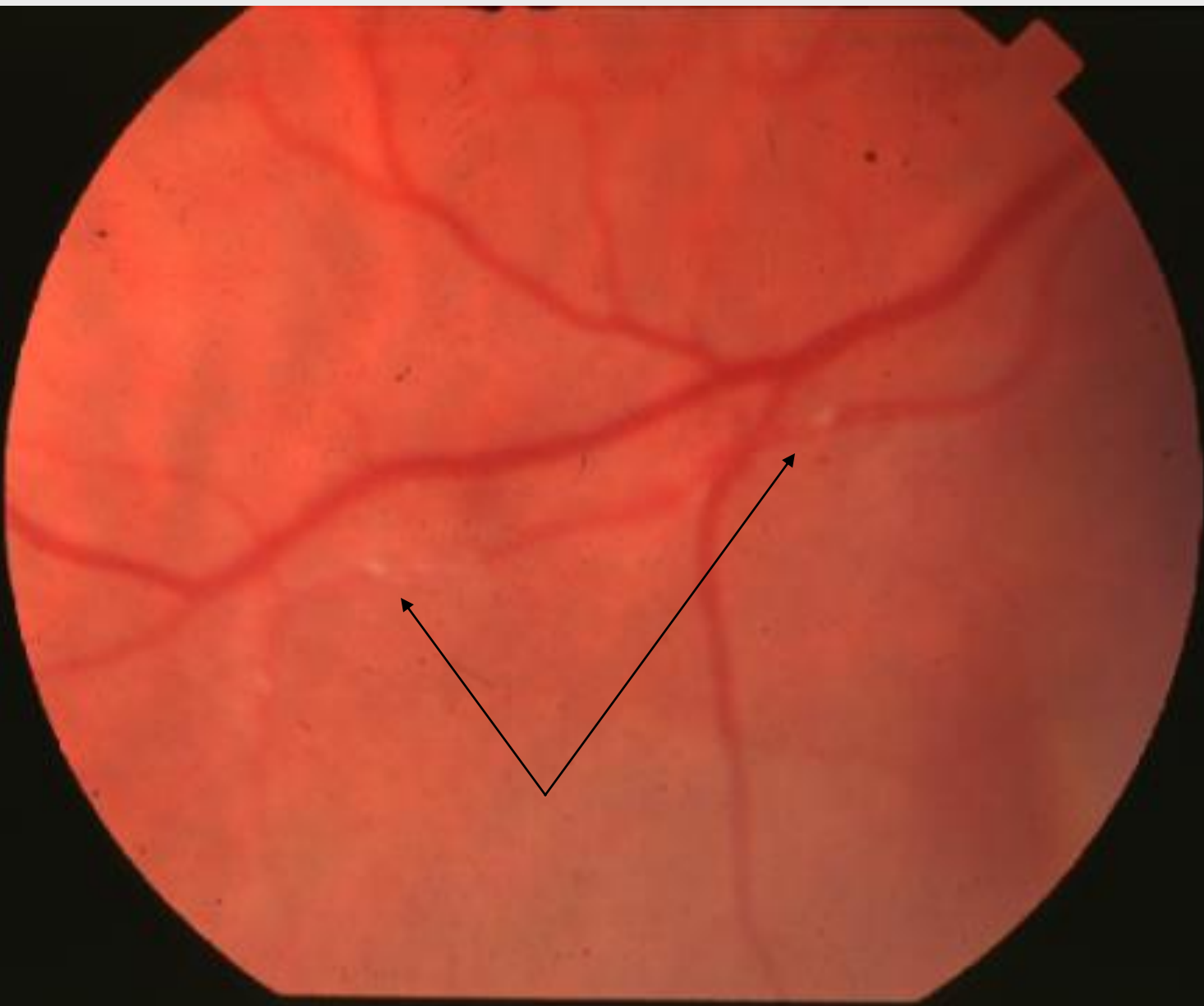
Courtesy Dr.
Mohammad
Rafieetary



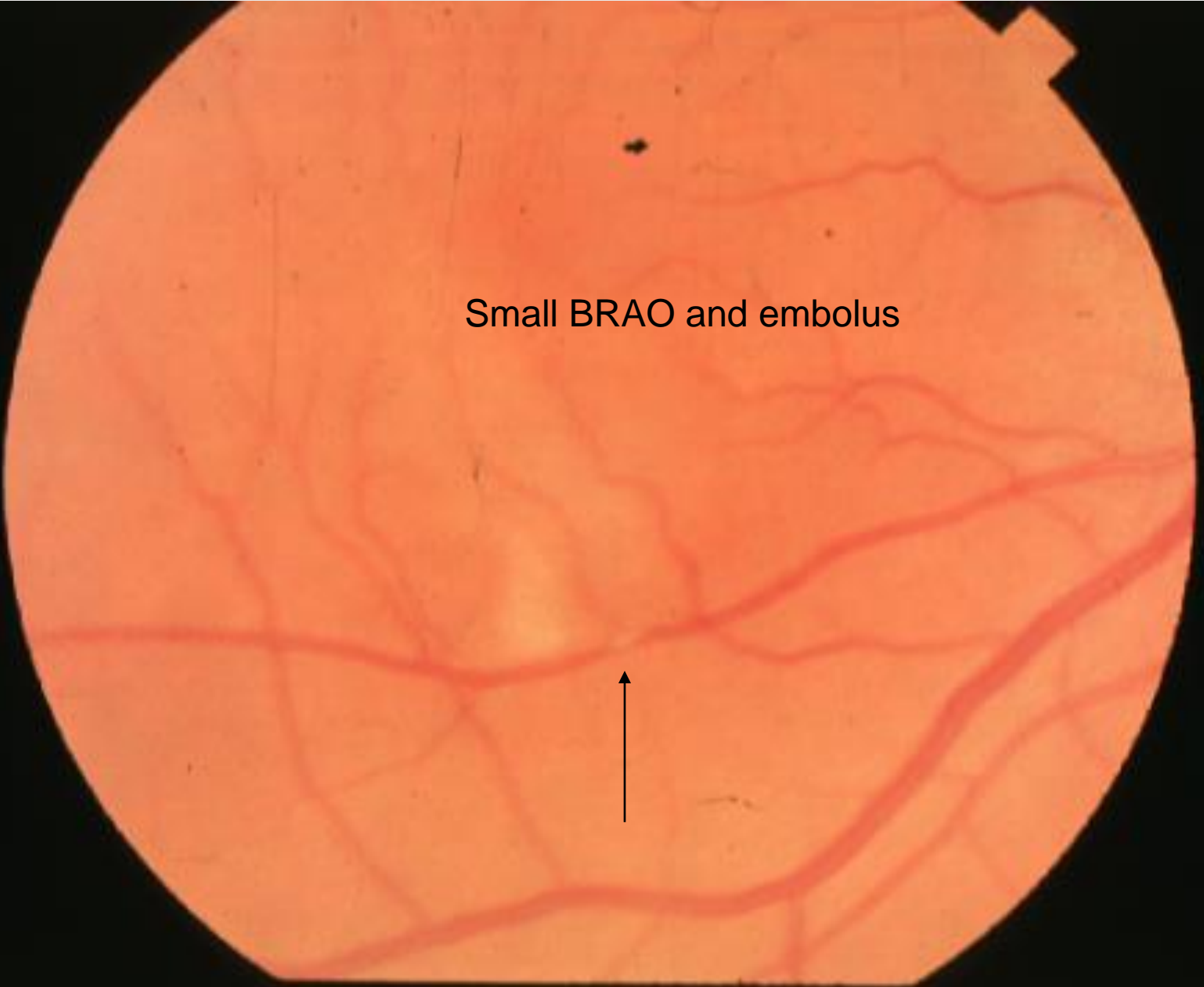
3 9 5 0



0.0.2.1



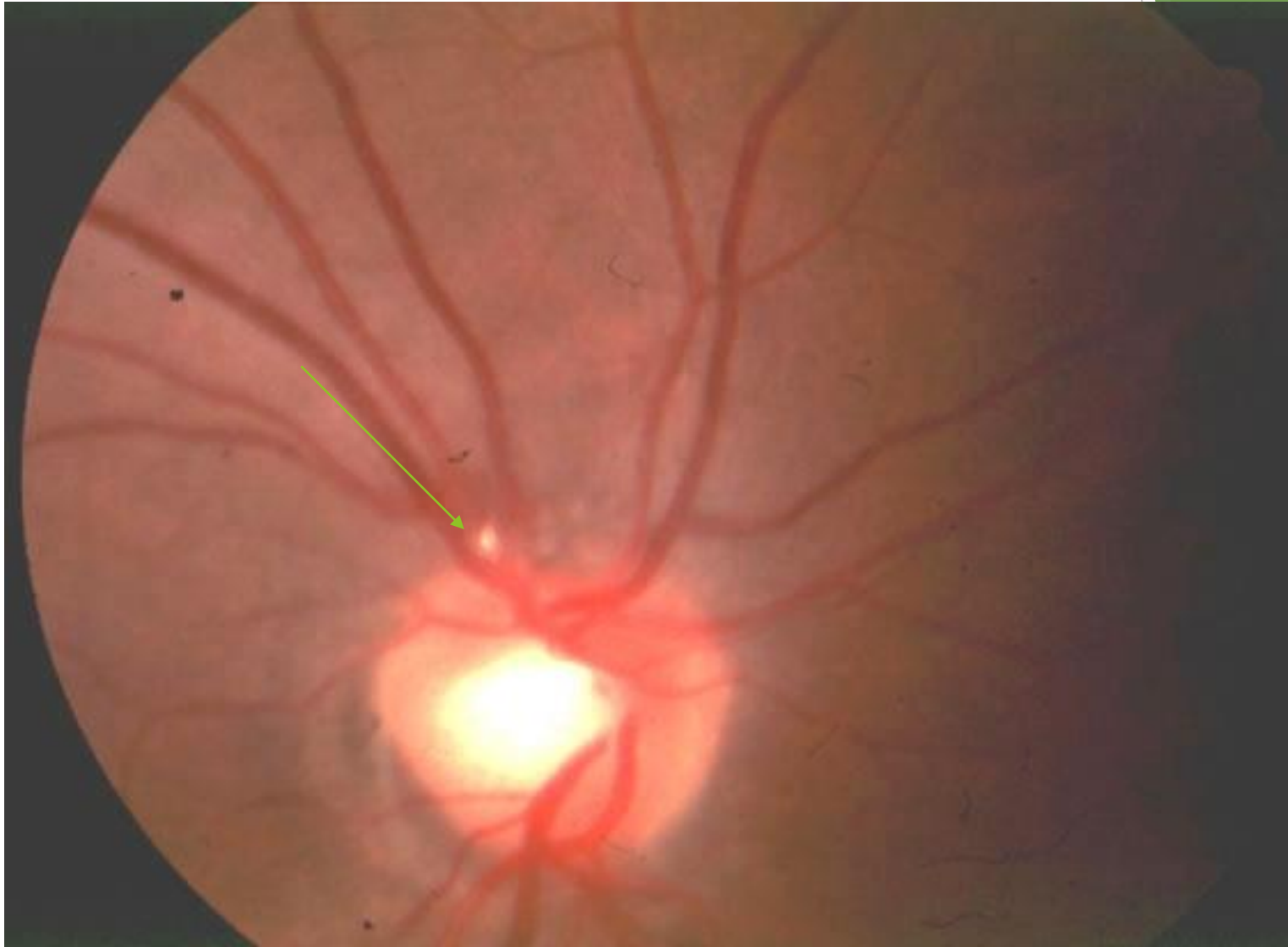
4.9.8.8



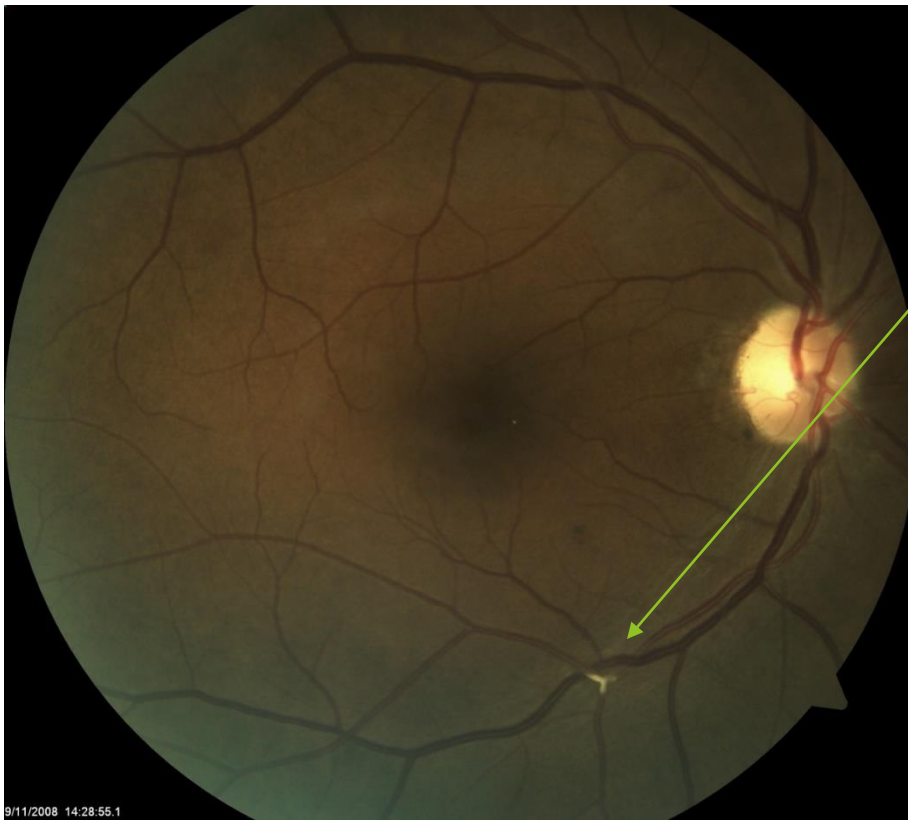
Small BRAO and embolus



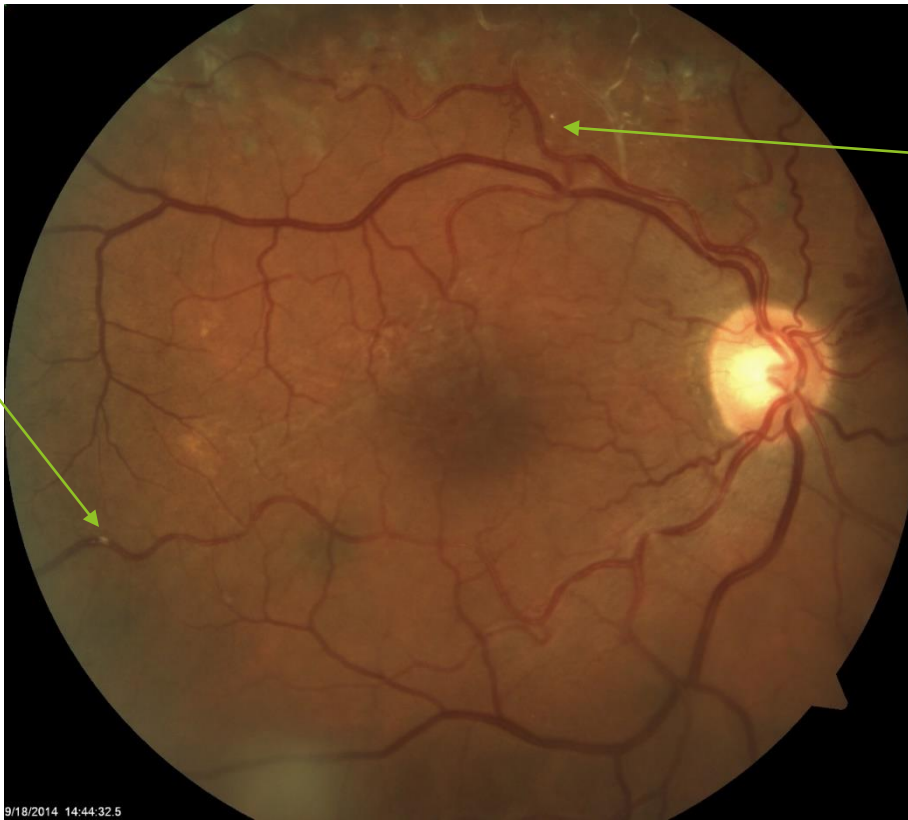
Calcium Embolus



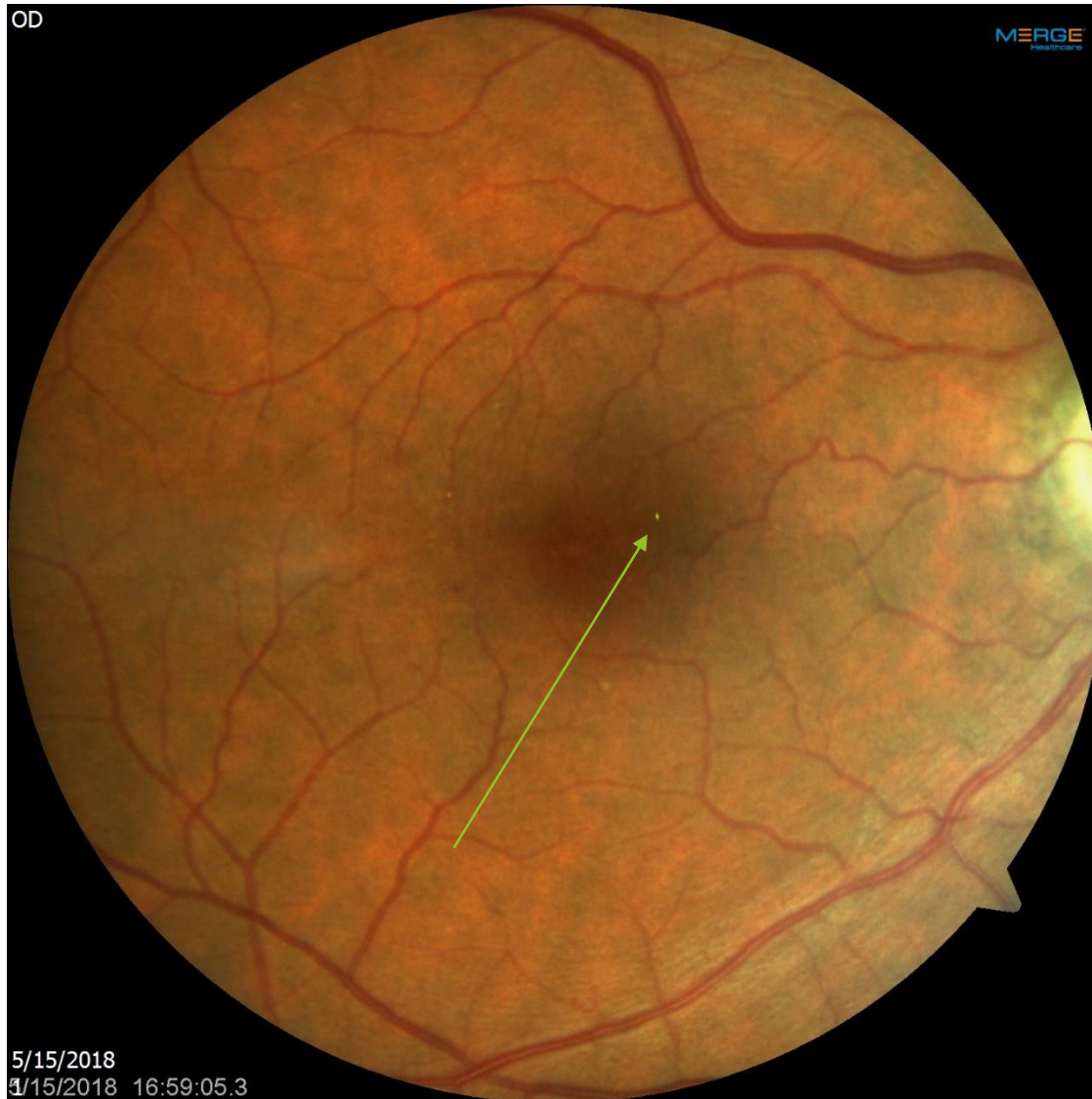Bifurcation fibrinoplatelet plaque



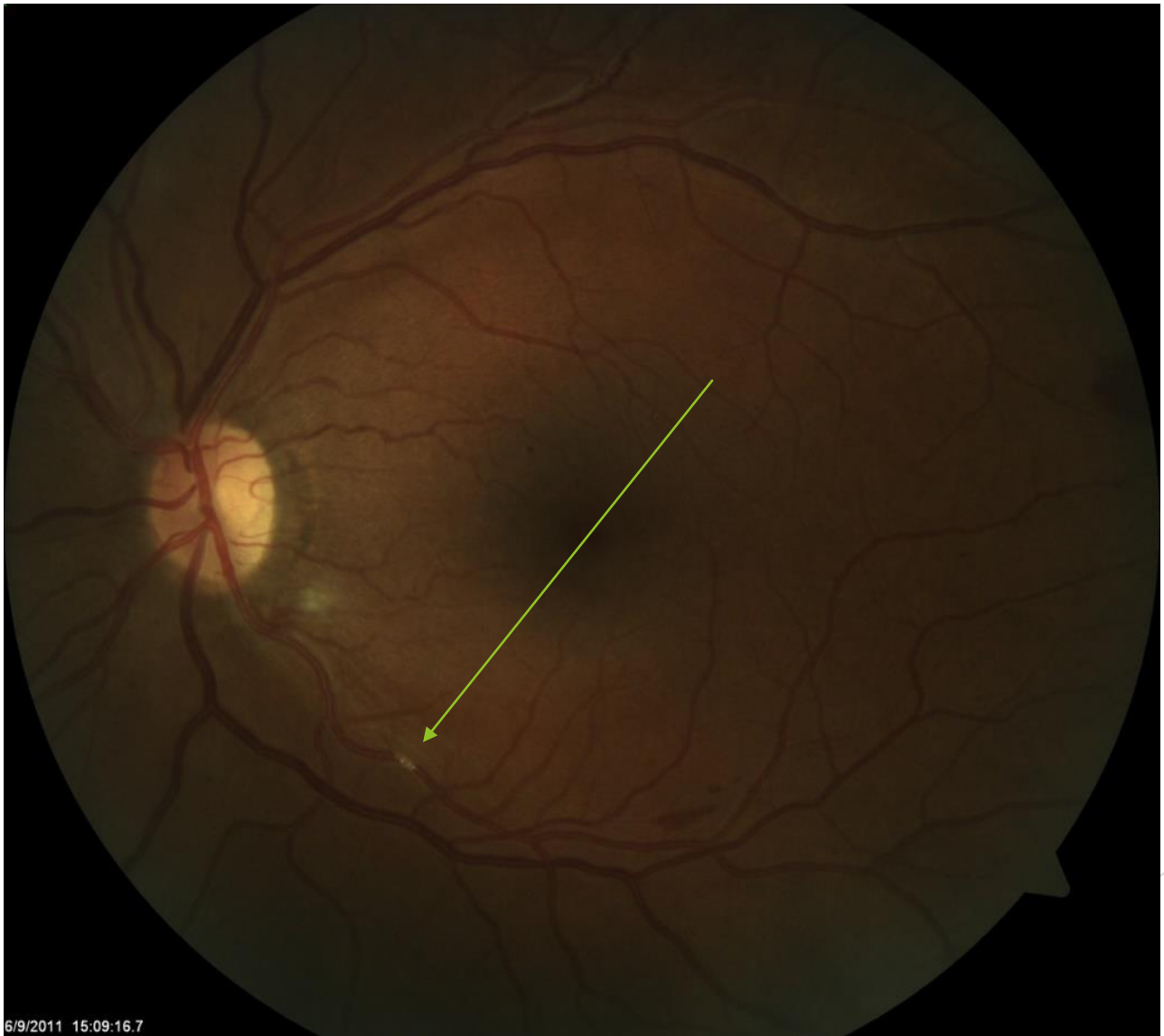
HH Plaque



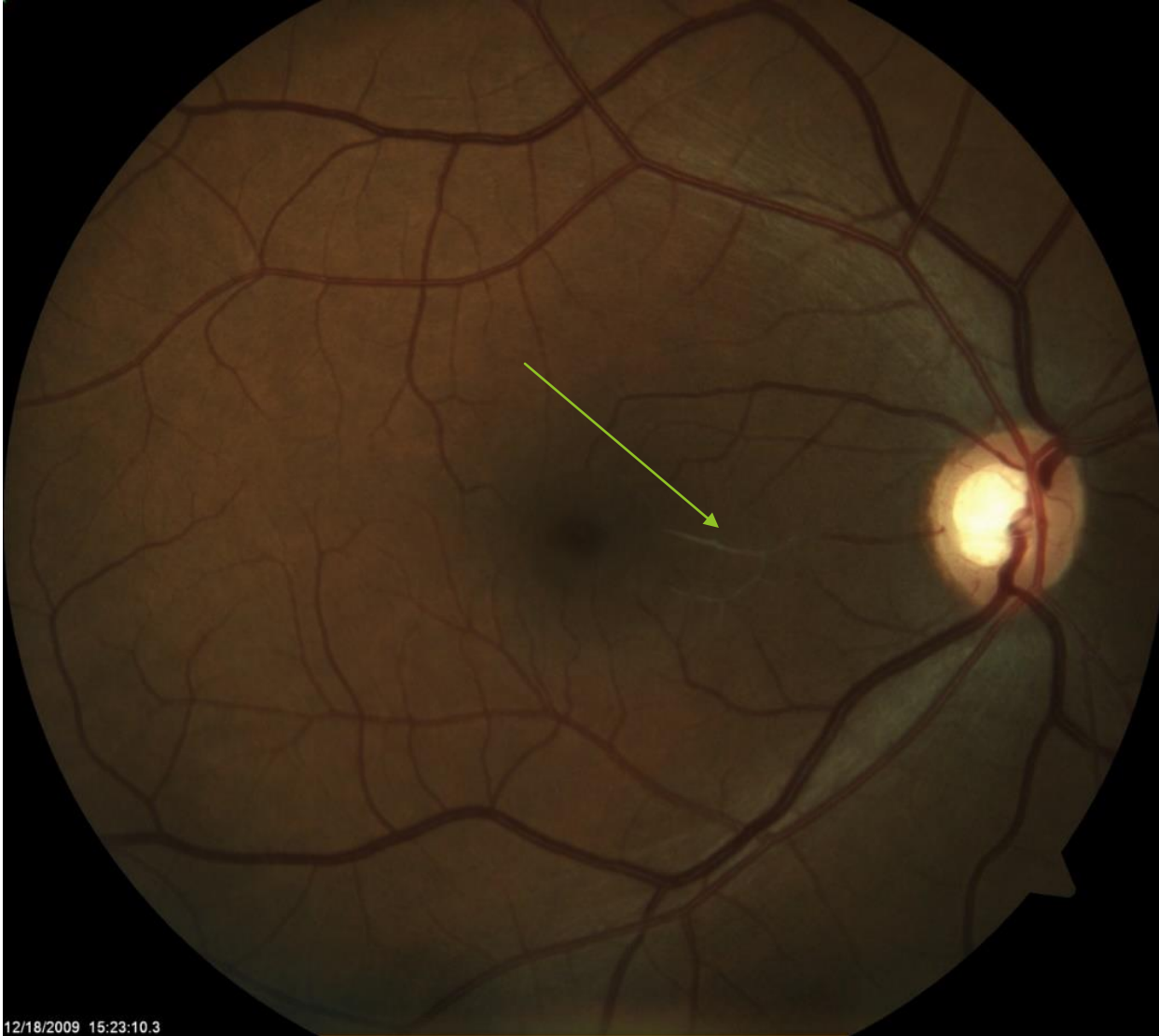
HH Plaque



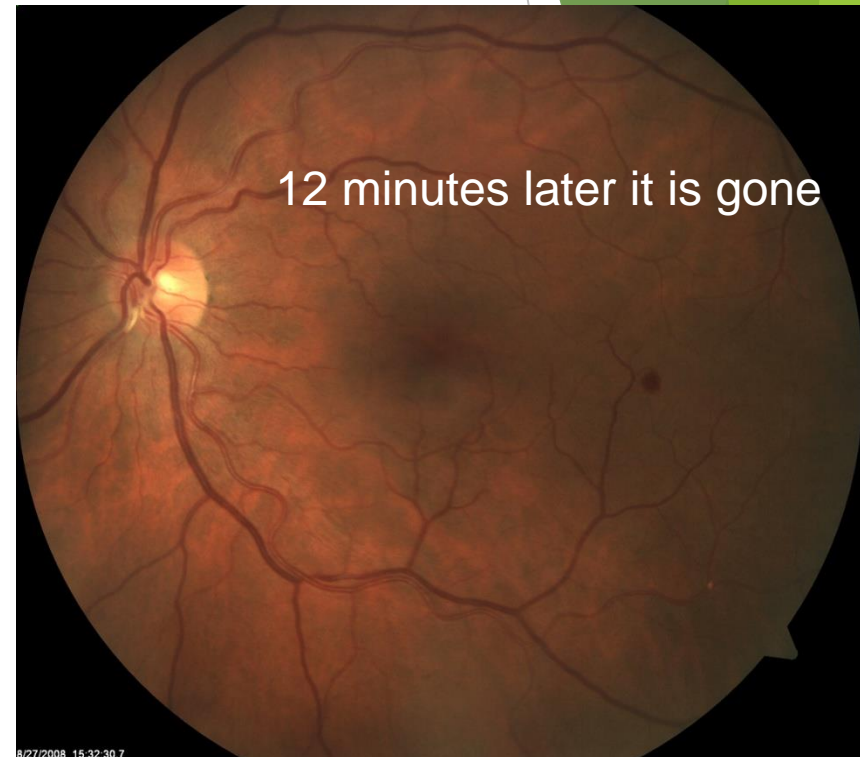
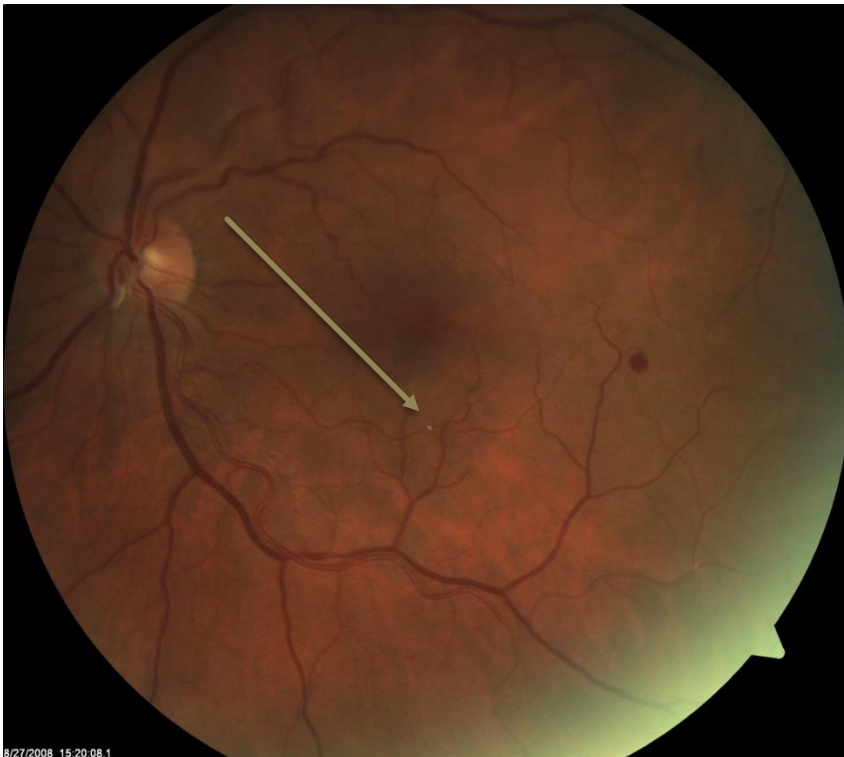
fibrinoplatelet plaque



Cilioretinal artery sclerosis



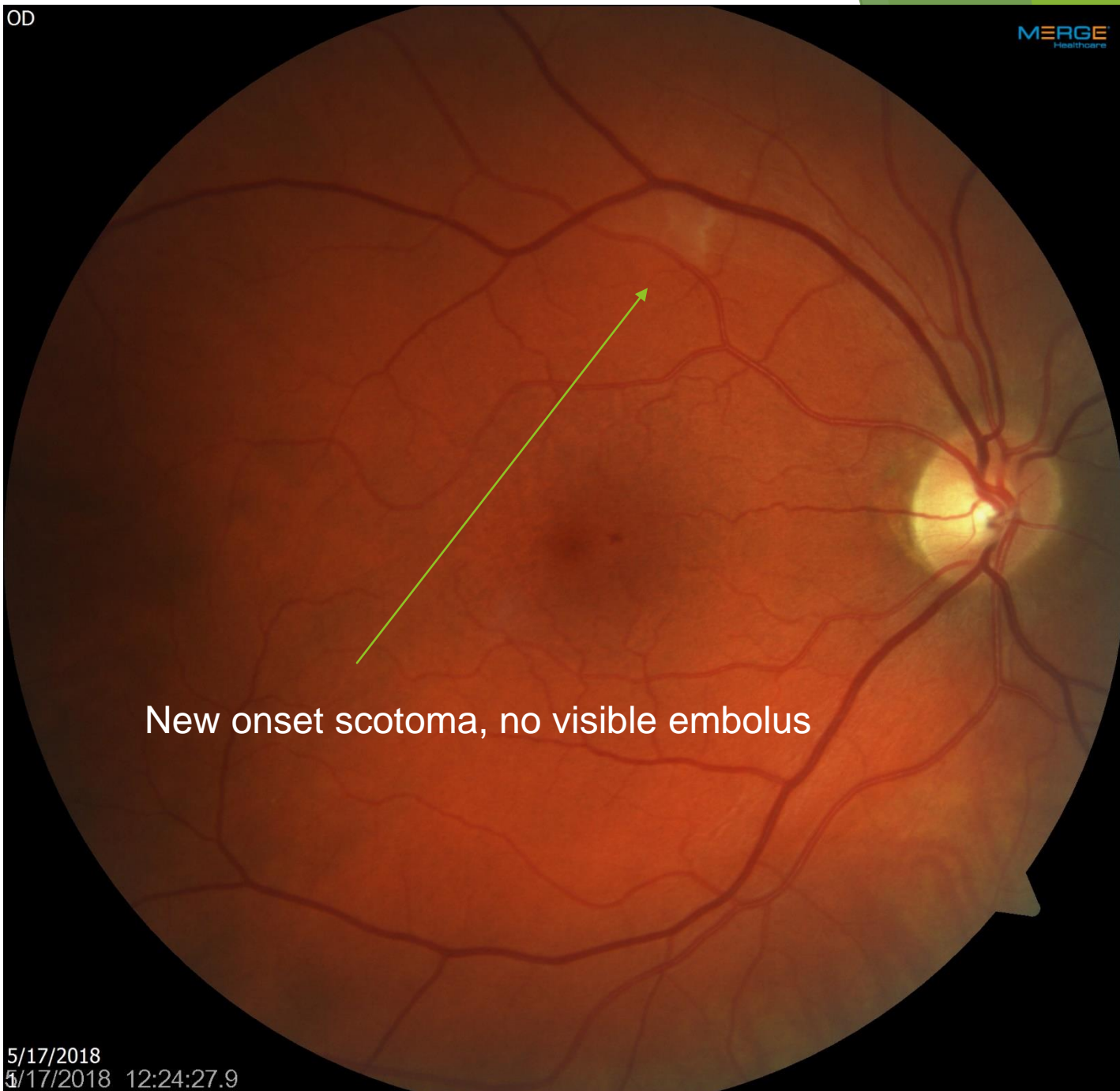
Now you see it.....



BRAO

OD

MERGE
Healthcare



New onset scotoma, no visible embolus

5/17/2018
5/17/2018 12:24:27.9

Retinal Vein Occlusions

- ▶ CRVO or BRVO
- ▶ Leading cause is hypertension (branch>central) but others include hypercoaguable states, thrombi, and atherosclerotic events. 20% associated with POAG. Link with OSA
- ▶ Second only to DBR in frequency
- ▶ Occlusion of vein leads to dilated and ruptured capillaries, often with edema

Retinal vein occlusion

- ▶ Large study published in September 2019 AJO looked at over 117,000 Korean patients with vein occlusions and found that, compared to matched patients without vein occlusions, they had.....
- ▶ Increased BMI and waist circumference
- ▶ Increased systolic and diastolic BP
- ▶ Higher fasting blood glucose
- ▶ Higher LDL, triglycerides, and total cholesterol
- ▶ Lower HDL (first time reported)

Virchow's triad for thrombosis in general:

- ▶ 1) Abnormalities of the vessel wall
- ▶ 2) Abnormalities in blood viscosity / coagulation
- ▶ 3) Abnormalities in blood flow / velocity

CRVO


- ▶ Most patients 50+
- ▶ 50+% have systemic association: linked to IOP
- ▶ Often increased Homocysteine levels, APA
- ▶ Presenting symptom is a sudden, painless loss of vision
- ▶ Two types: ischemic and non-ischemic.

Non-Ischemic CRVO

- ▶ Non-ischemic CRVO (up to 80% of cases) has a less severe presentation and better prognosis
- ▶ VA moderately reduced; often 20/60 to 20/100
- ▶ No APD typically
- ▶ 2/3 have 20 / 40 + final VA
- ▶ Less capillary non-perfusion on IVFA
- ▶ No neovascular complications

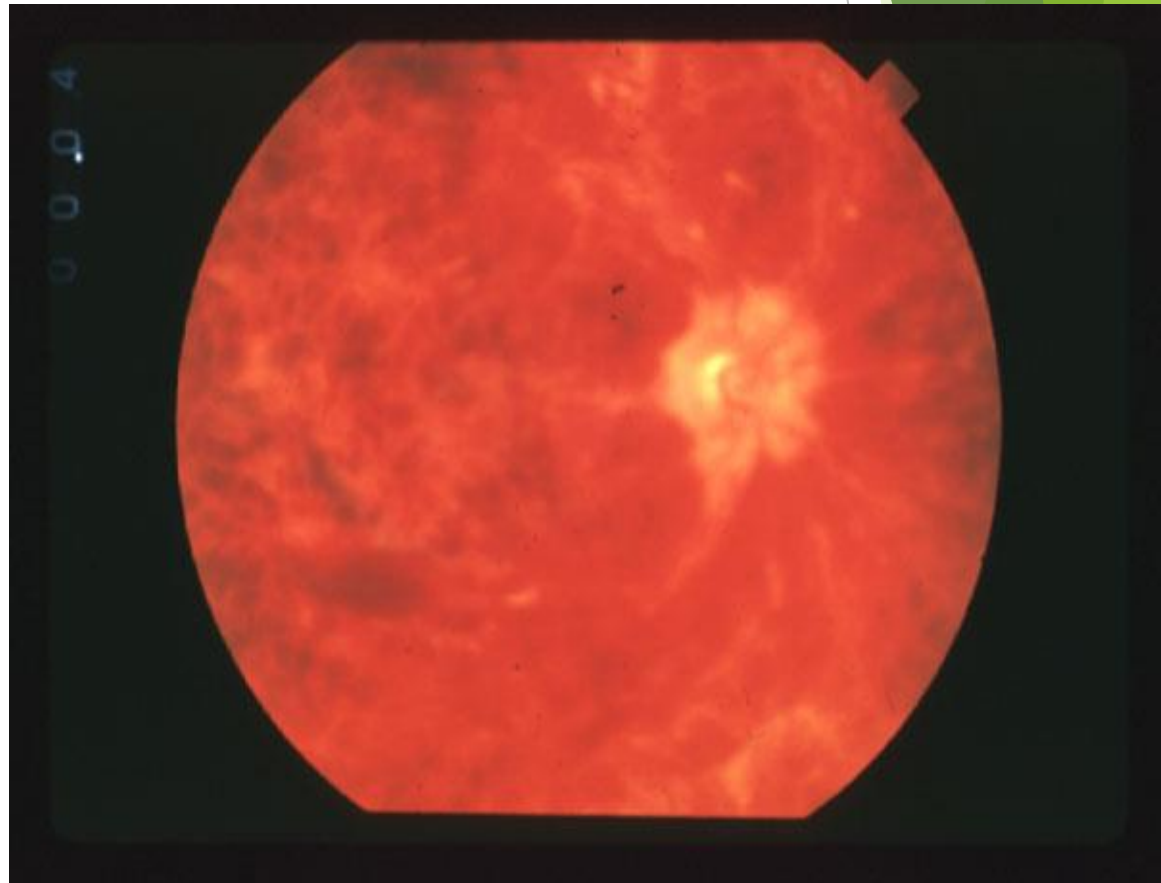
Ischemic CRVO

- ▶ Ischemic CRVO much more severe
- ▶ VA markedly reduced, usually 20/200 or worse



Ischemic CRVO

- ▶ + APD
- ▶ Massive hemes in all four quadrants



Ischemic CRVO

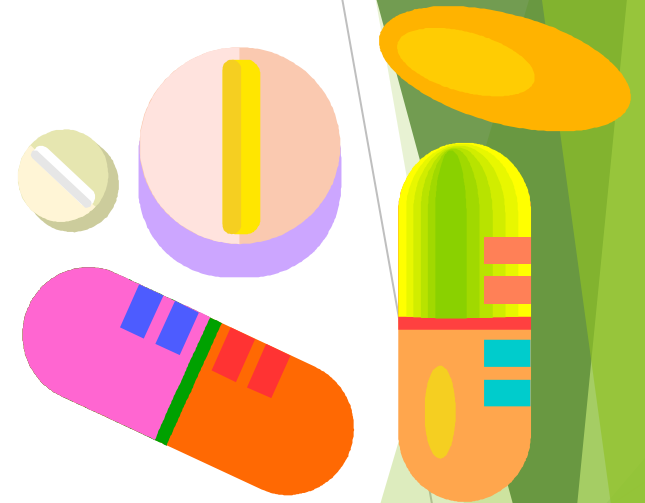- ▶ Severe macular edema, may get disc edema
- ▶ More CWS than non-ischemic
- ▶ IVFA / OCTA shows significant capillary dropout and non-perfusion
- ▶ Prominent middle limiting membrane (MLM) on SD-OCT at outer plexiform layer
- ▶ NVI very common, NVD and NVE less so???
- ▶ Only 40-45% NVI get NVG
- ▶ *How could NVD and NVE be less common than NVI? They are harder to see!

CRVO

- ▶ What do we do for the eye?
- ▶ Many more options than we used to have

Treatment

- ▶ ? Doppler of carotids in all cases: Carotid occlusion highly associated with CRVO (especially ischemic), but not causative



Surgical interventions

- ▶ Radial optic neurotomy
- ▶ Chorioretinal venous anastamoses
- ▶ Vitrectomy / ILM peel
- ▶ Cannulation of the vein with t-PA injection
- ▶ All historically tried and mostly abandoned

Intravitreal kenalog

- ▶ SCORE study
- ▶ Observation vs. 1mg/ml kenalog vs. 4mg / ml kenalog
- ▶ After six months:
 - ▶ Steroid injection 5 times more likely to get substantial VA improvement compared to observation
 - ▶ Watch for steroid side effects
 - ▶ Now also have steroid implants

Intravitreal Avastin / Lucentis / Eylea

- ▶ CRUISE study (Lucentis)

At six months, gain of.....

- ▶ .3mg/ml injection vs. .5mg/ml injection vs. sham injection

13 letters on EDRS chart

15 letters

1 letter !

Laser therapy

- ▶ PRP still has a role if neovascularization develops
- ▶ Grid-focal laser really has no role typically in CRVO management
- ▶ Anti-VEGF injections have become the standard therapy, typically on a treat and extend basis: Avastin / Lucentis / Eylea / Beovu (which of these is by far the most cost effective? Avastin!)
- ▶ Several studies comparing the various agents to each other: basically they all work

RETAIN Study

- ▶ 34 BRVO and 32 CRVO patients receiving Lucentis shots followed over four years.
- ▶ At the four year mark.....
- ▶ Average vision gain achieved at six months was still present at four years
- ▶ But 50% of BRVO and 56% of CRVO patients were still getting shots four years out

SCORE II study

- ▶ CRVO and HRVO
- ▶ Injection at enrollment and every month thereafter
- ▶ Either 1.25 mg of Avastin or 2.0 mg of Eylea
- ▶ At 6 months.....
- ▶ Avastin and Eylea showed equal improvement in VA
- ▶ Eylea showed a greater reduction in central macular edema on OCT (but no better VA)
- ▶ Younger age, worse initial vision were correlated with more improvement in VA

In general.....

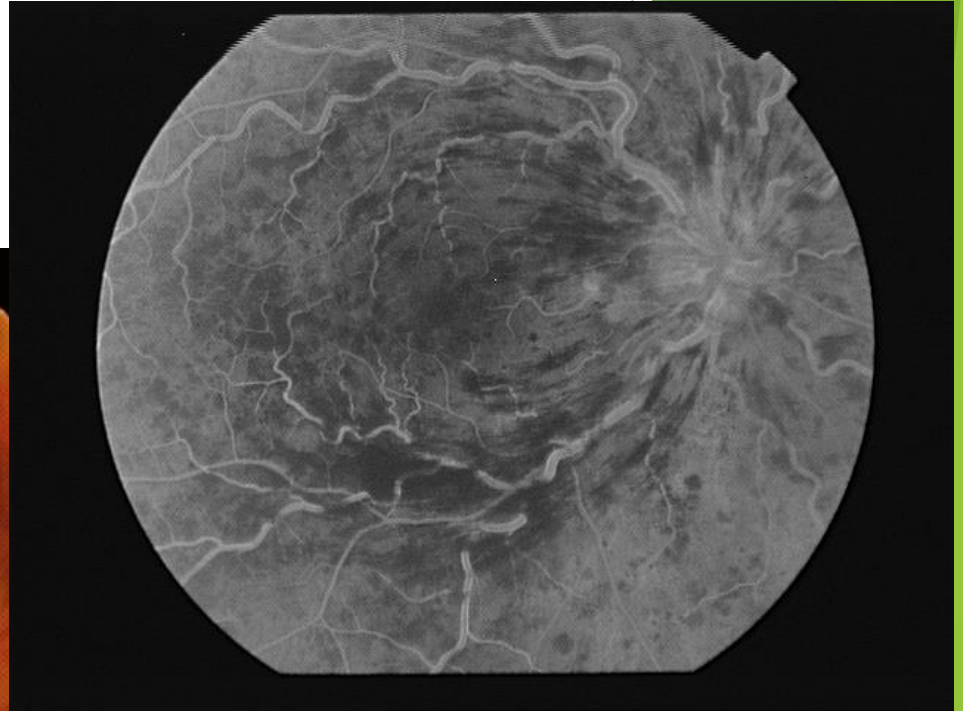
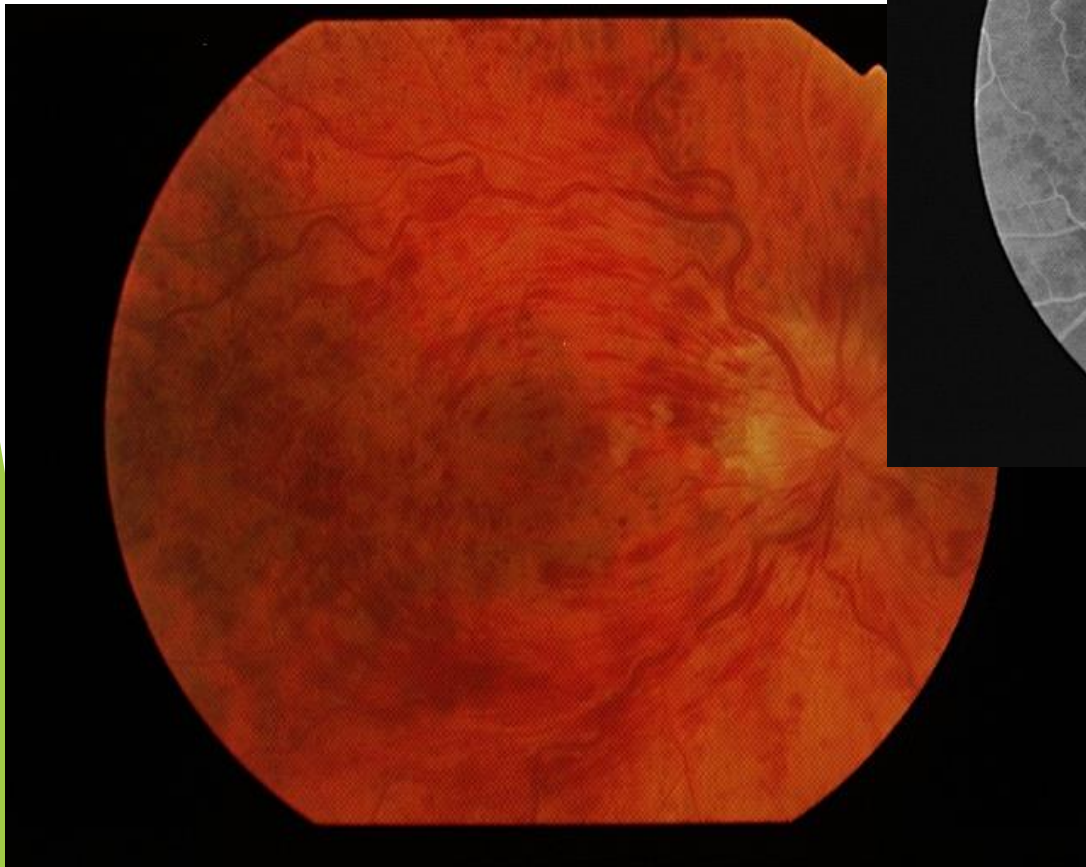
- ▶ PRP advantage with neo.....
- ▶ Can permanently “fix” the problem by decreasing oxygen demand below the needed threshold
- ▶ PRP disadvantage....
- ▶ ERM formation
- ▶ Night vision loss
- ▶ Peripheral vision loss
- ▶ Longer treatment session

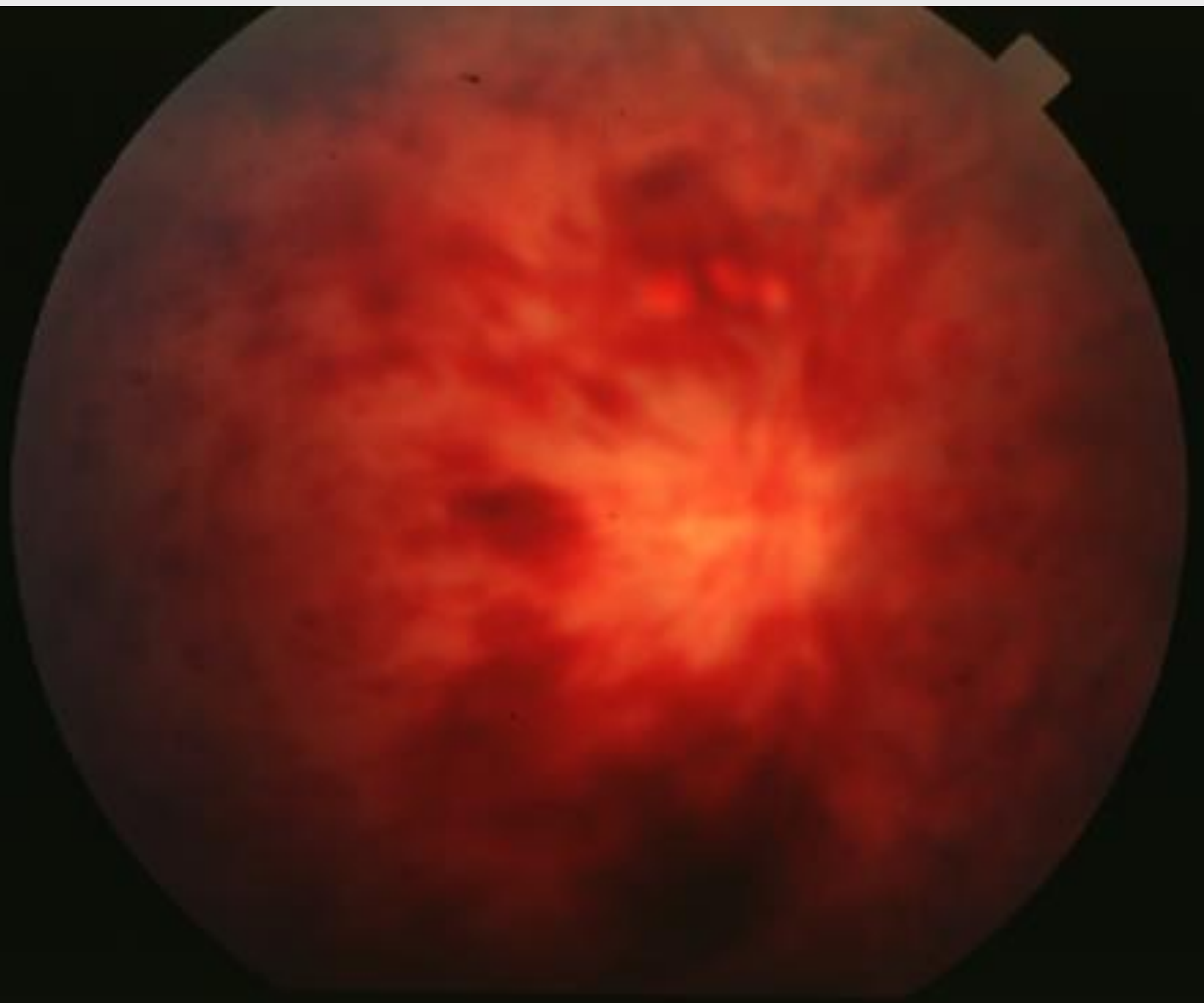
In general.....

- ▶ Anti-VEGF injection advantages.....
- ▶ Very low rate of side effects (endophthalmitis, elevated IOP with repeat injections)
- ▶ Work well, often very well
- ▶ Anti-VEGF injection disadvantages....
- ▶ Repeated injection after injection so issues with cost, transportation, “visit fatigue”, etc. Can need dozens of shots, less permanent

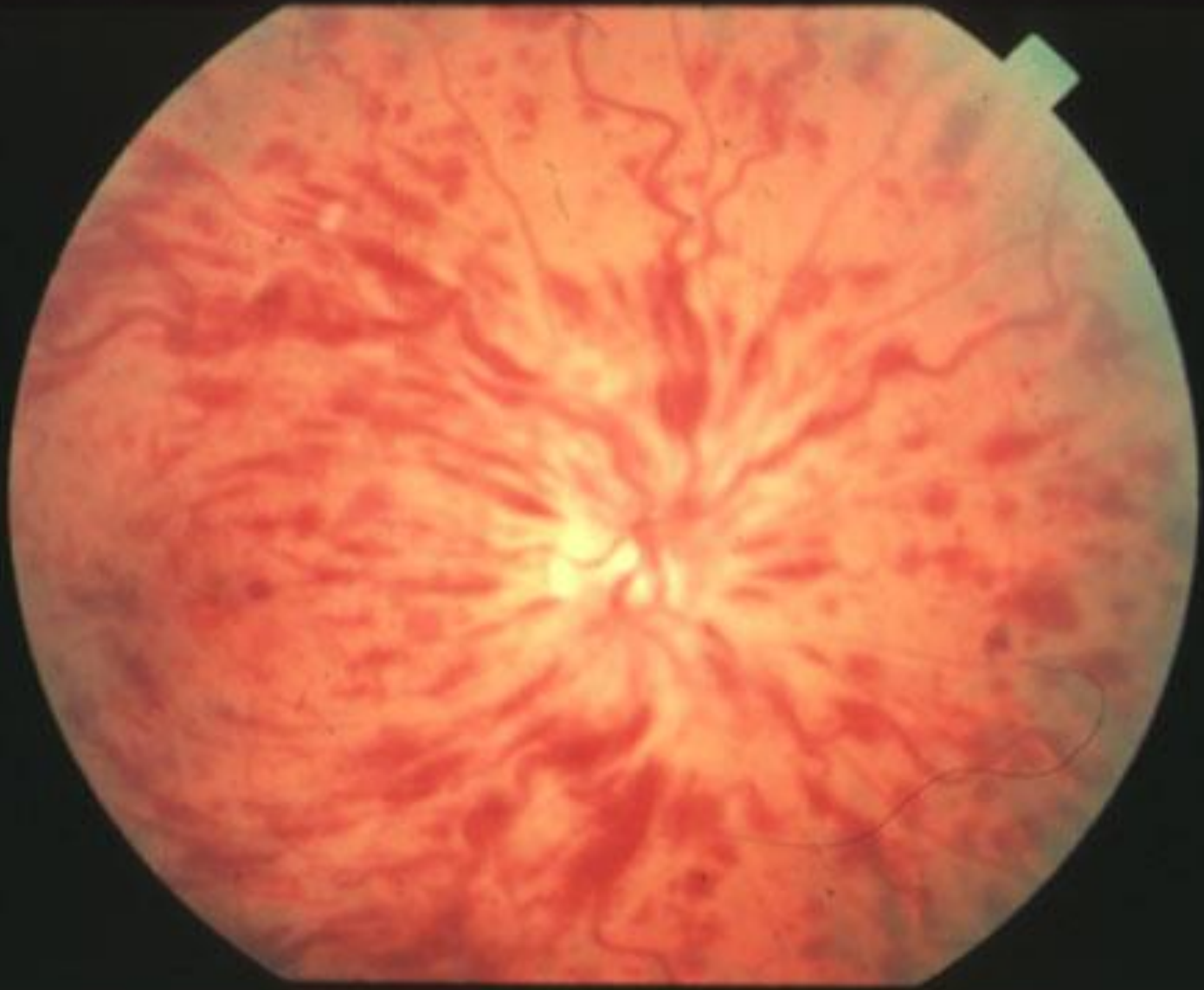CRVO

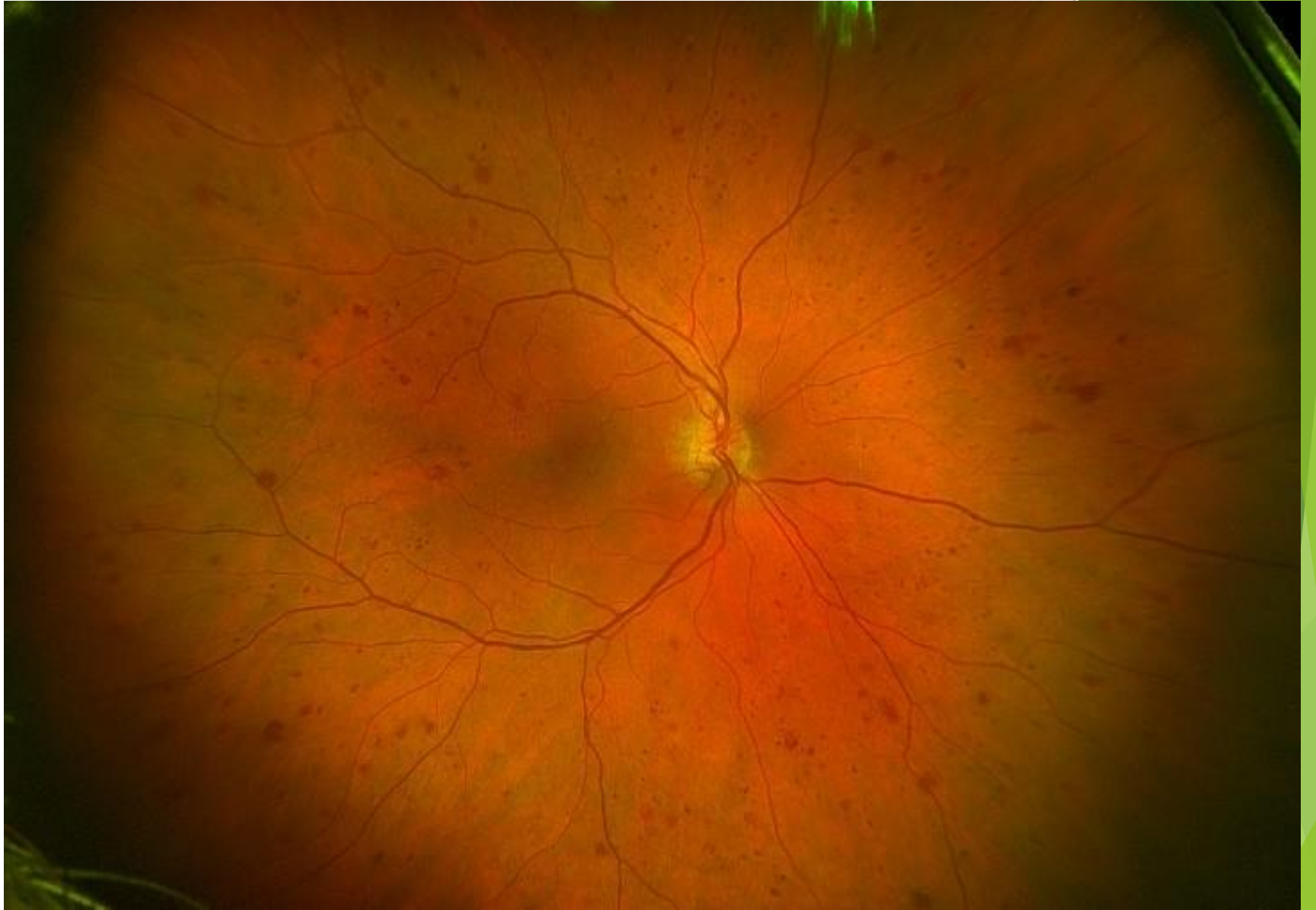▶ Non-ischemic



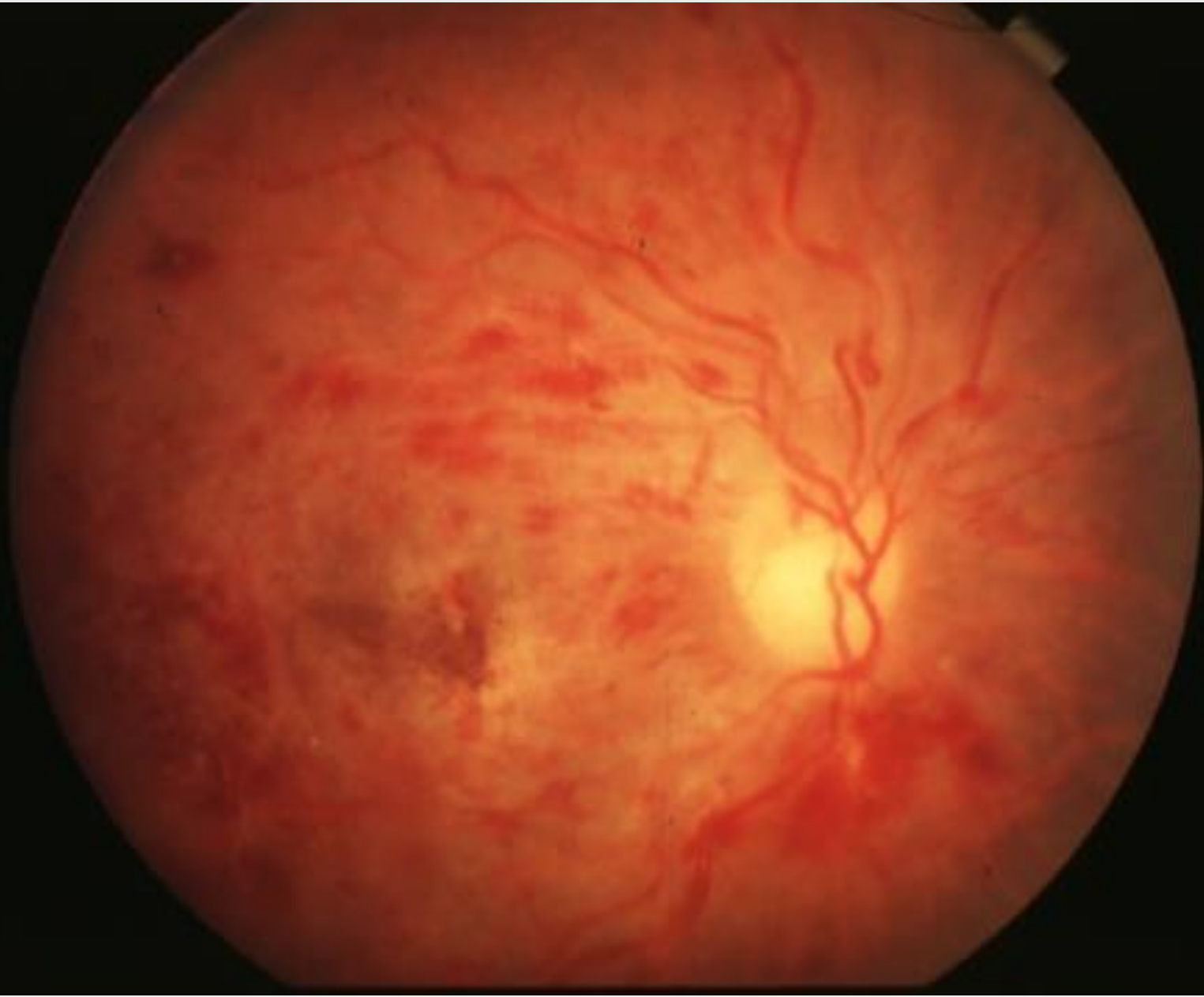

0064

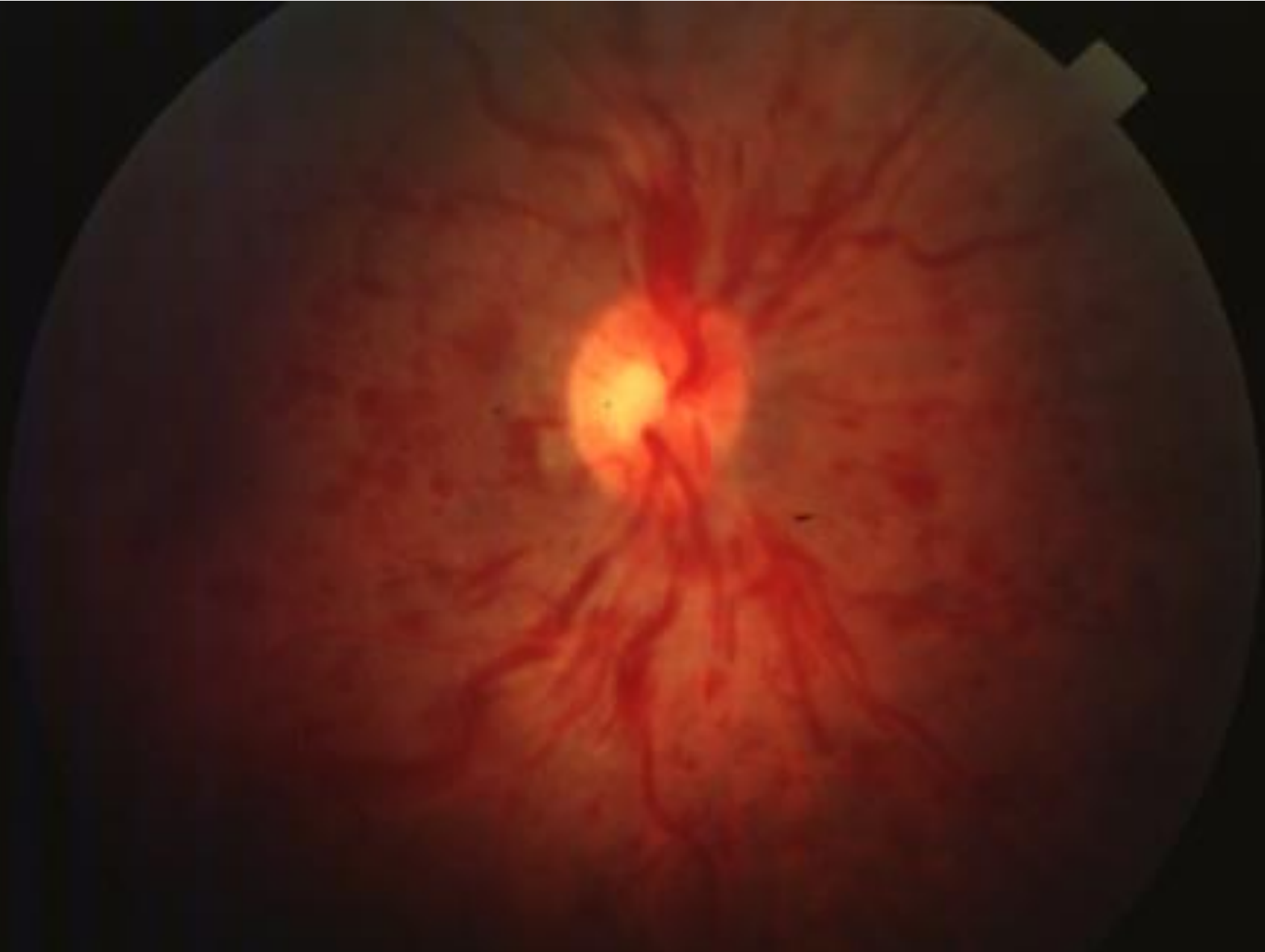




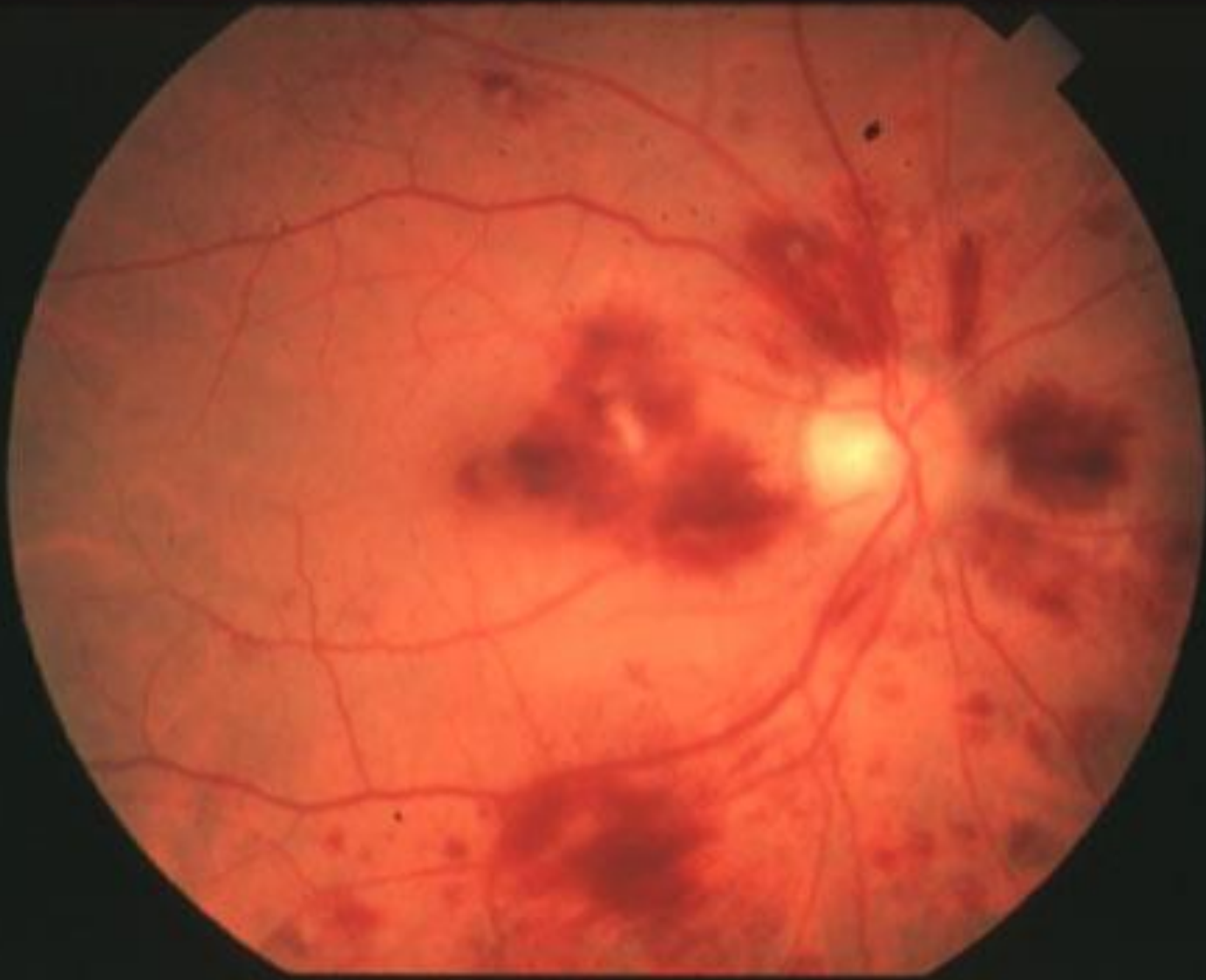6.2.3.3



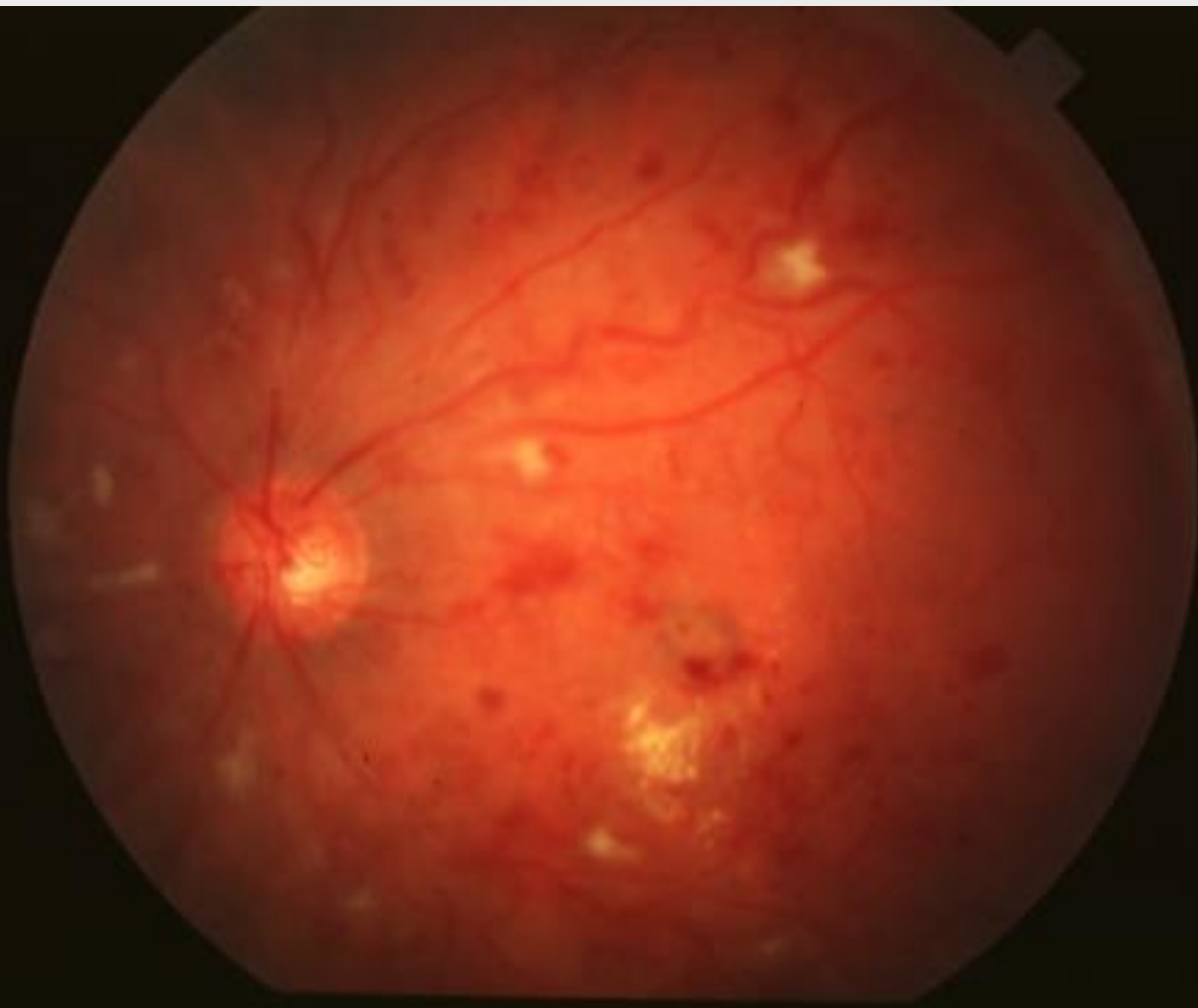
0.2-3.2



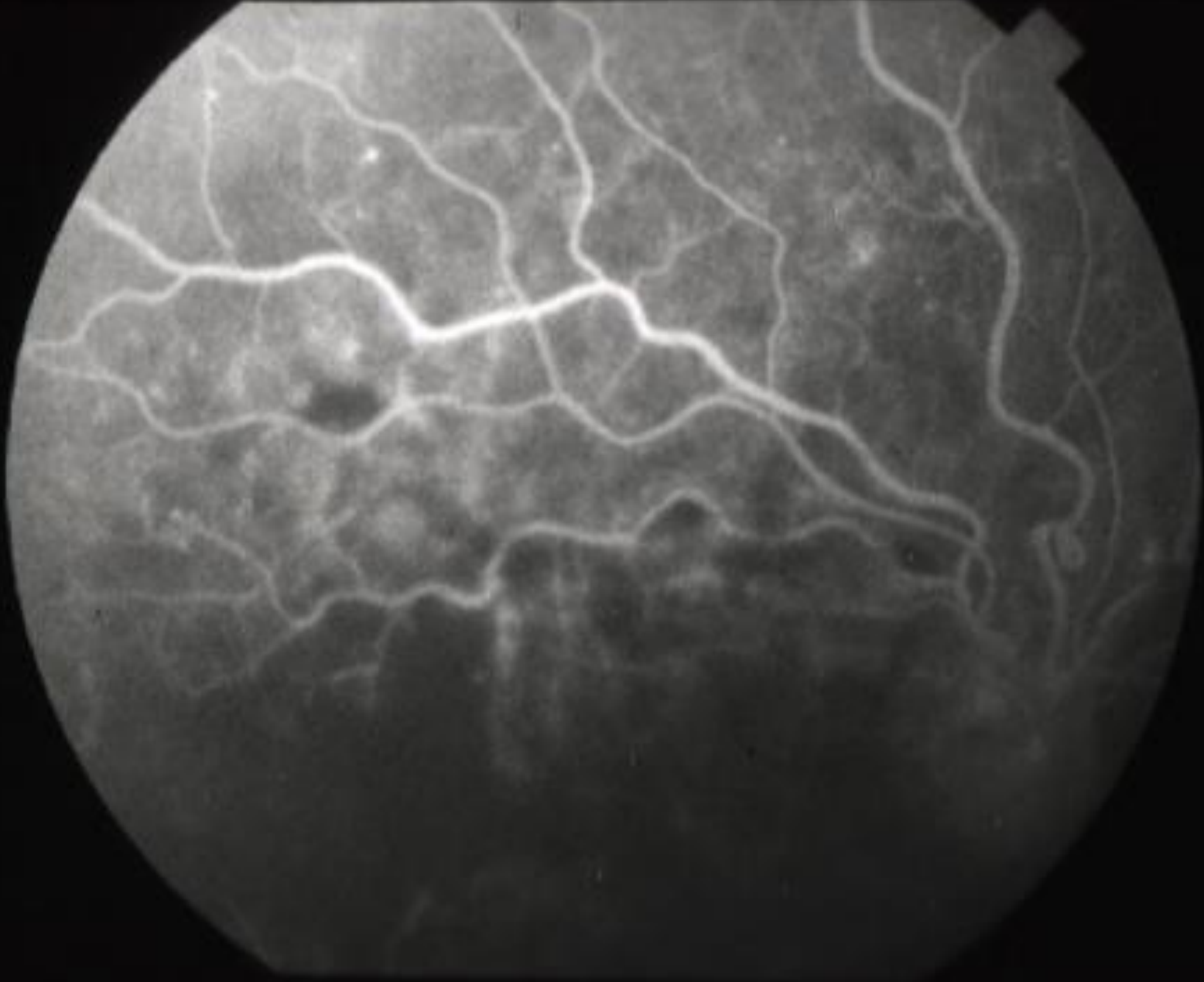
0.050



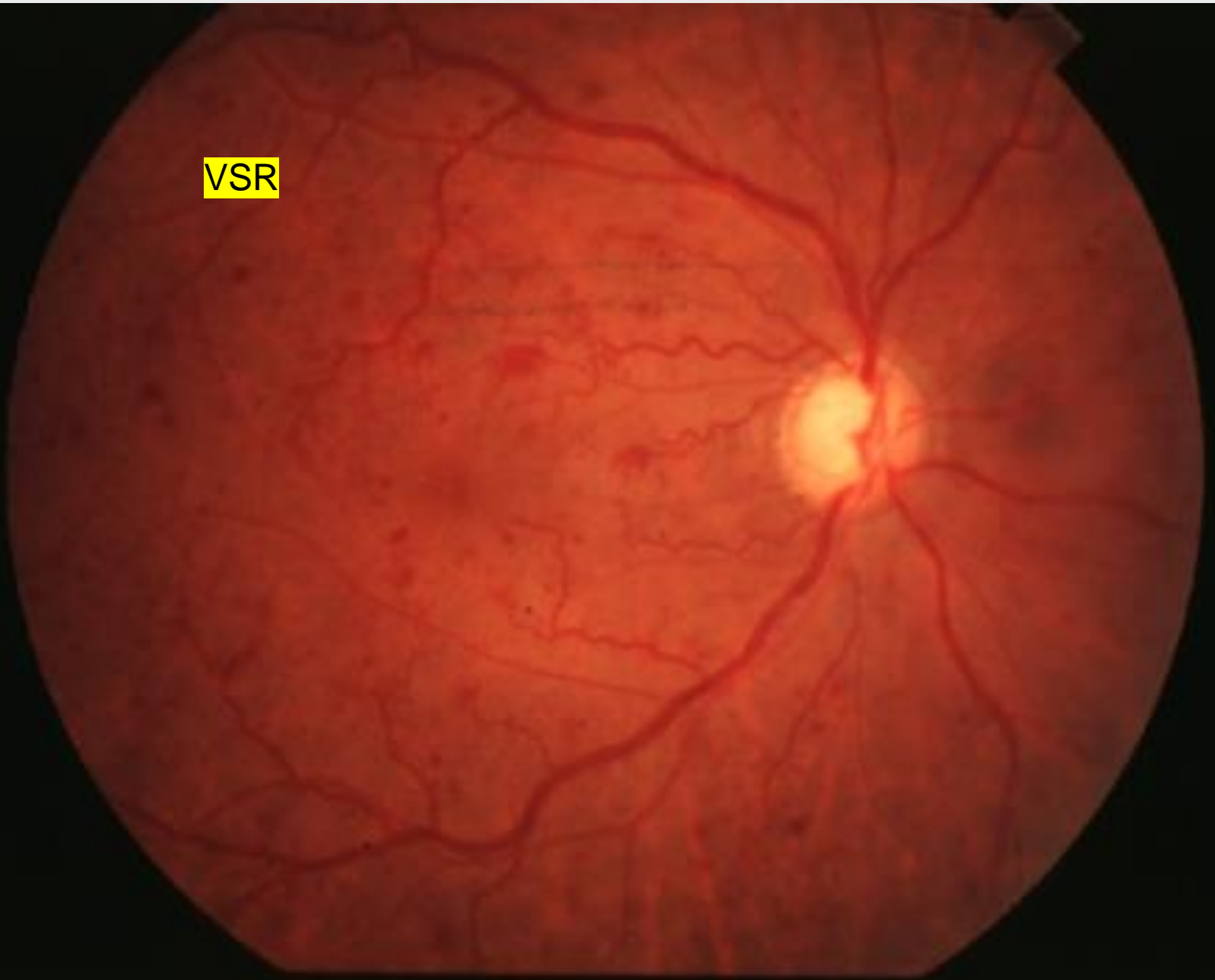
0.0.1.8



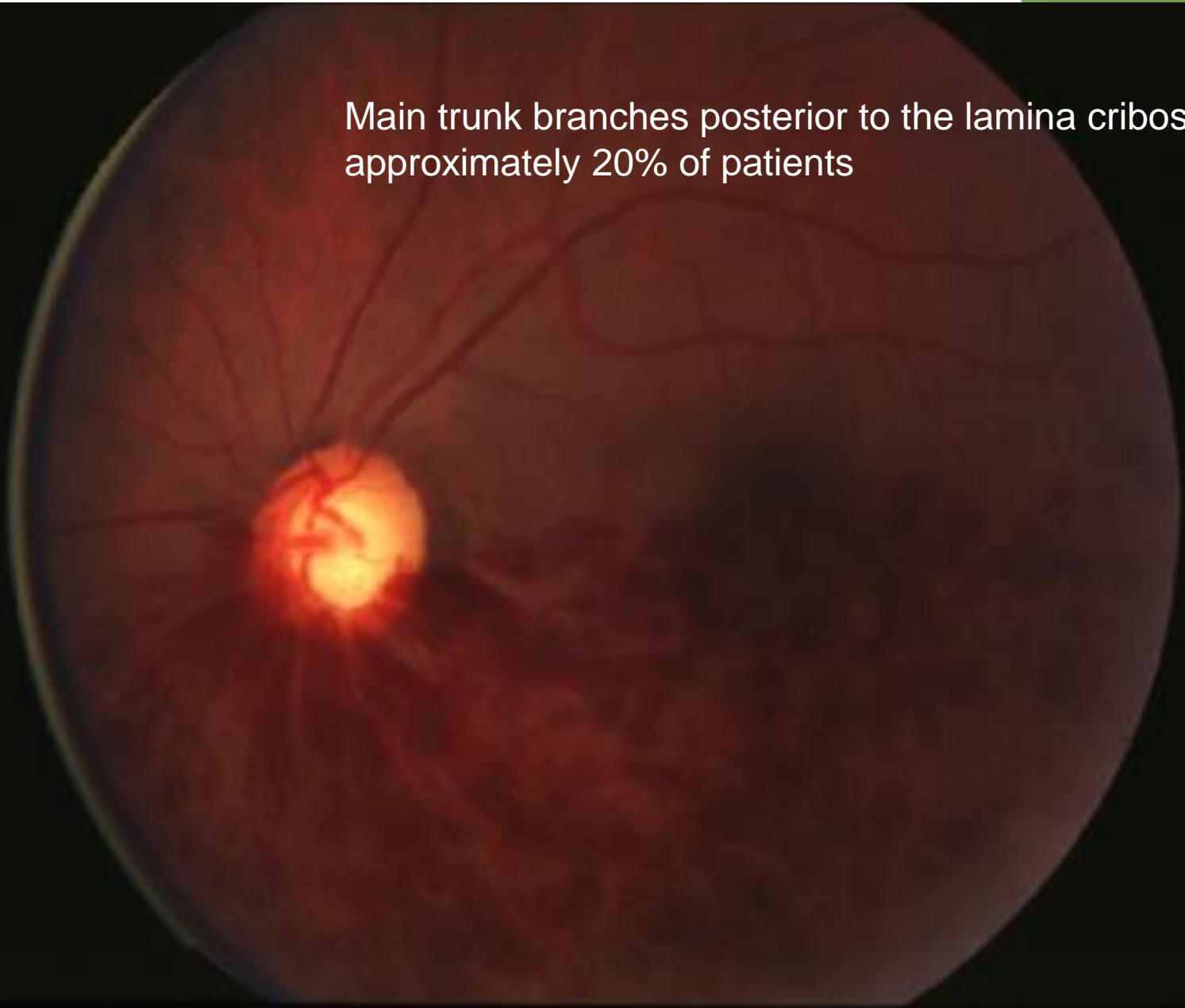1772



VSR

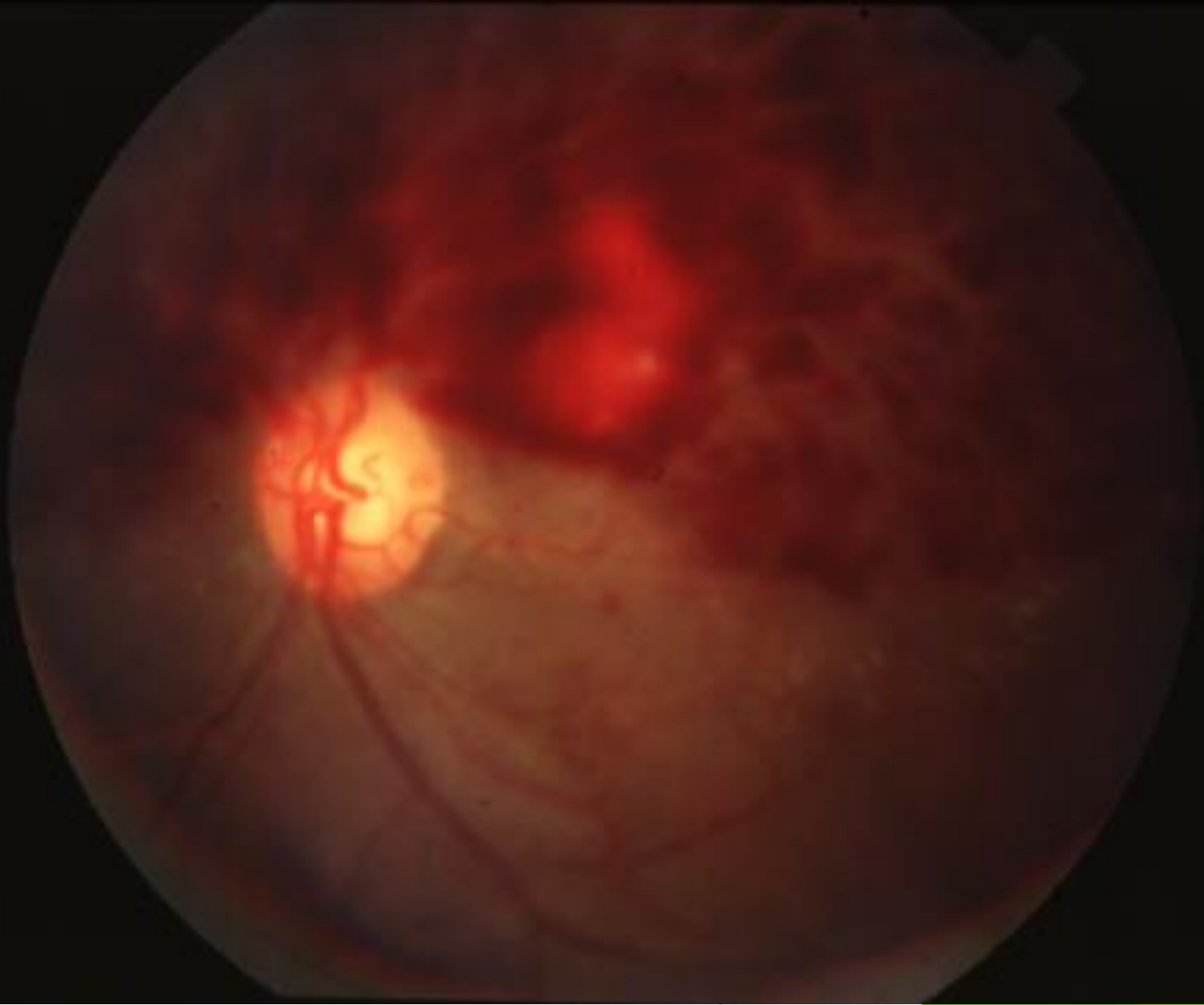

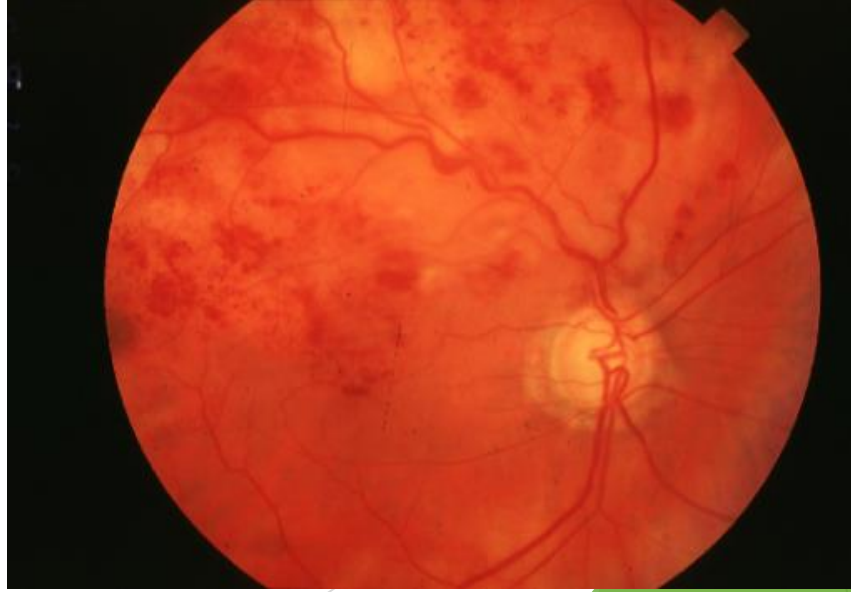
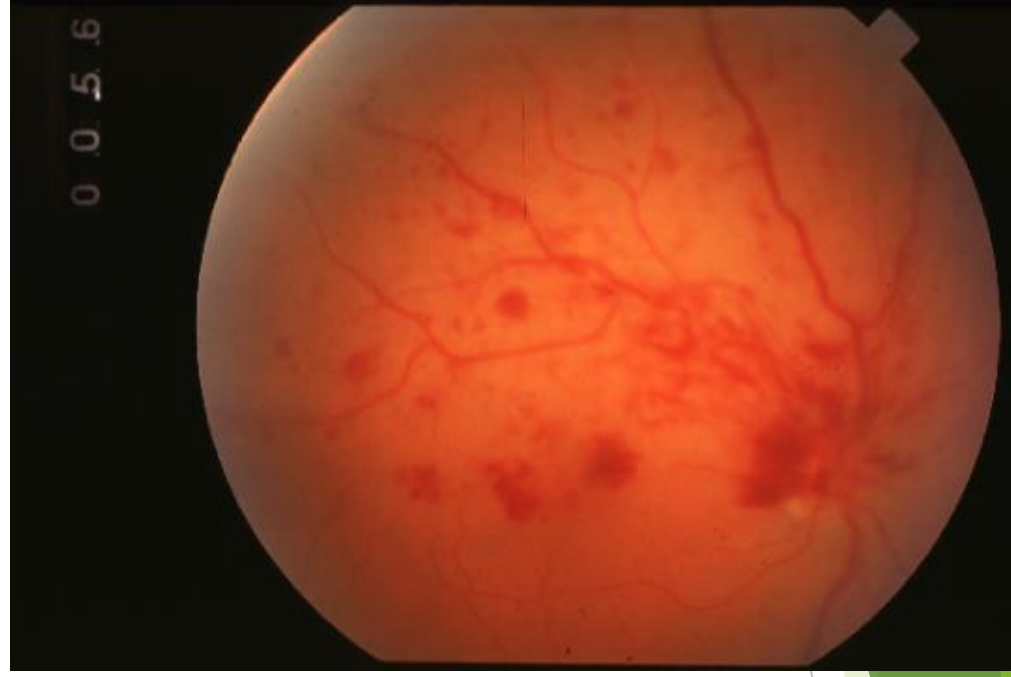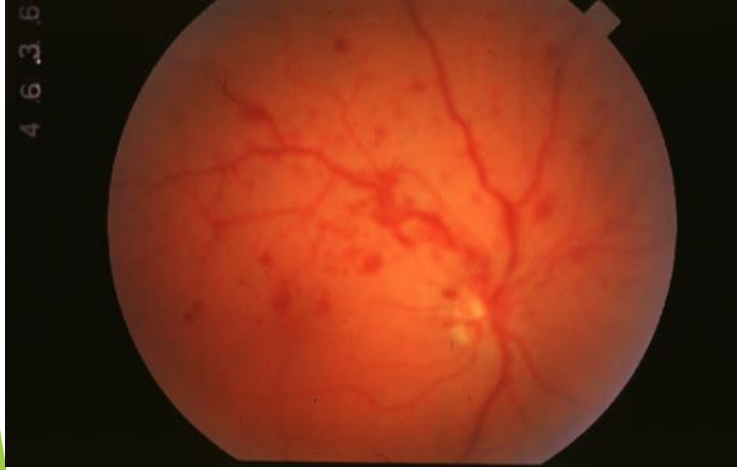
Main trunk branches posterior to the lamina cribrosa in approximately 20% of patients



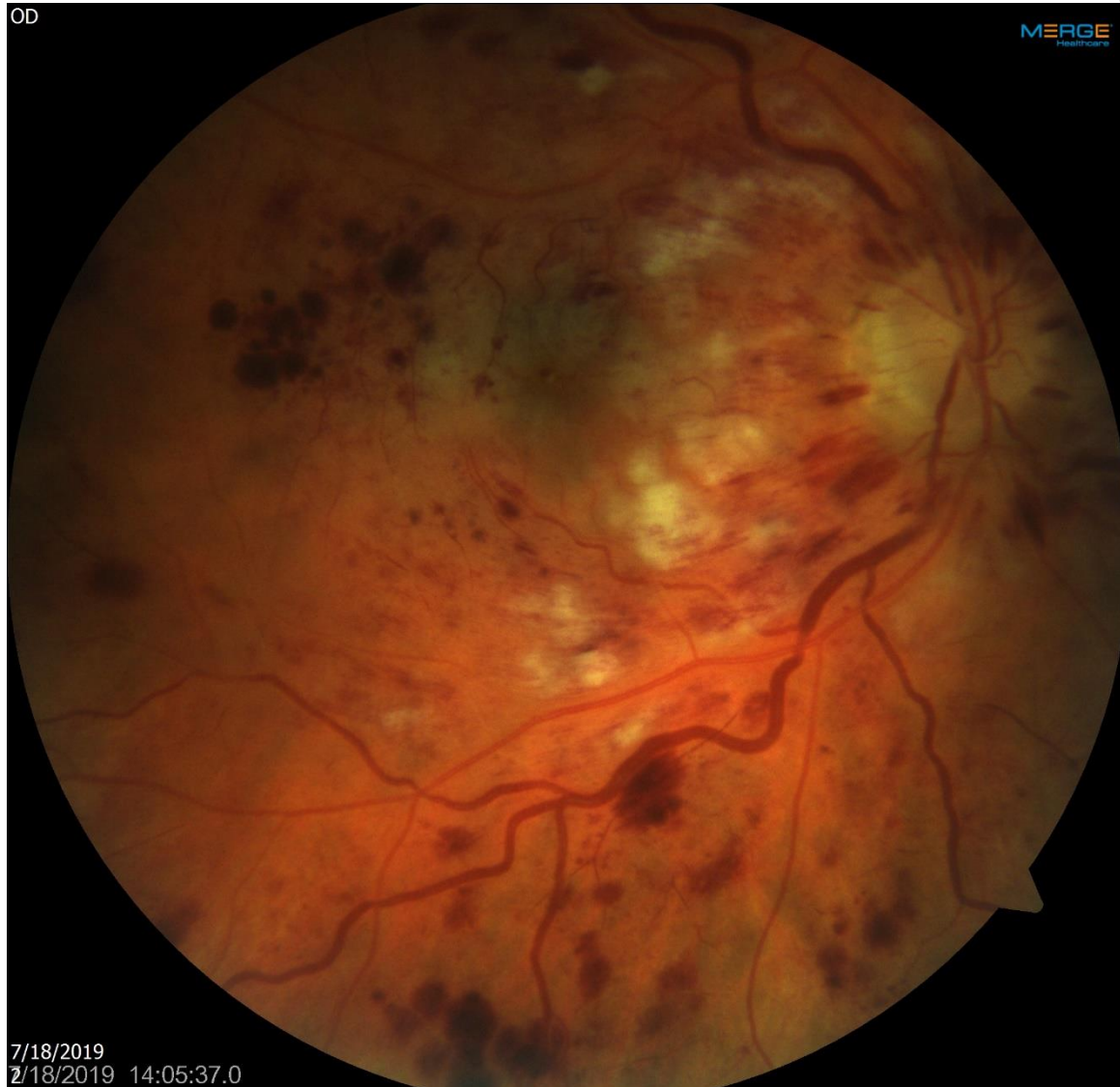
W. J. O. C.

0.24.0





Combined CRAO / CRVO



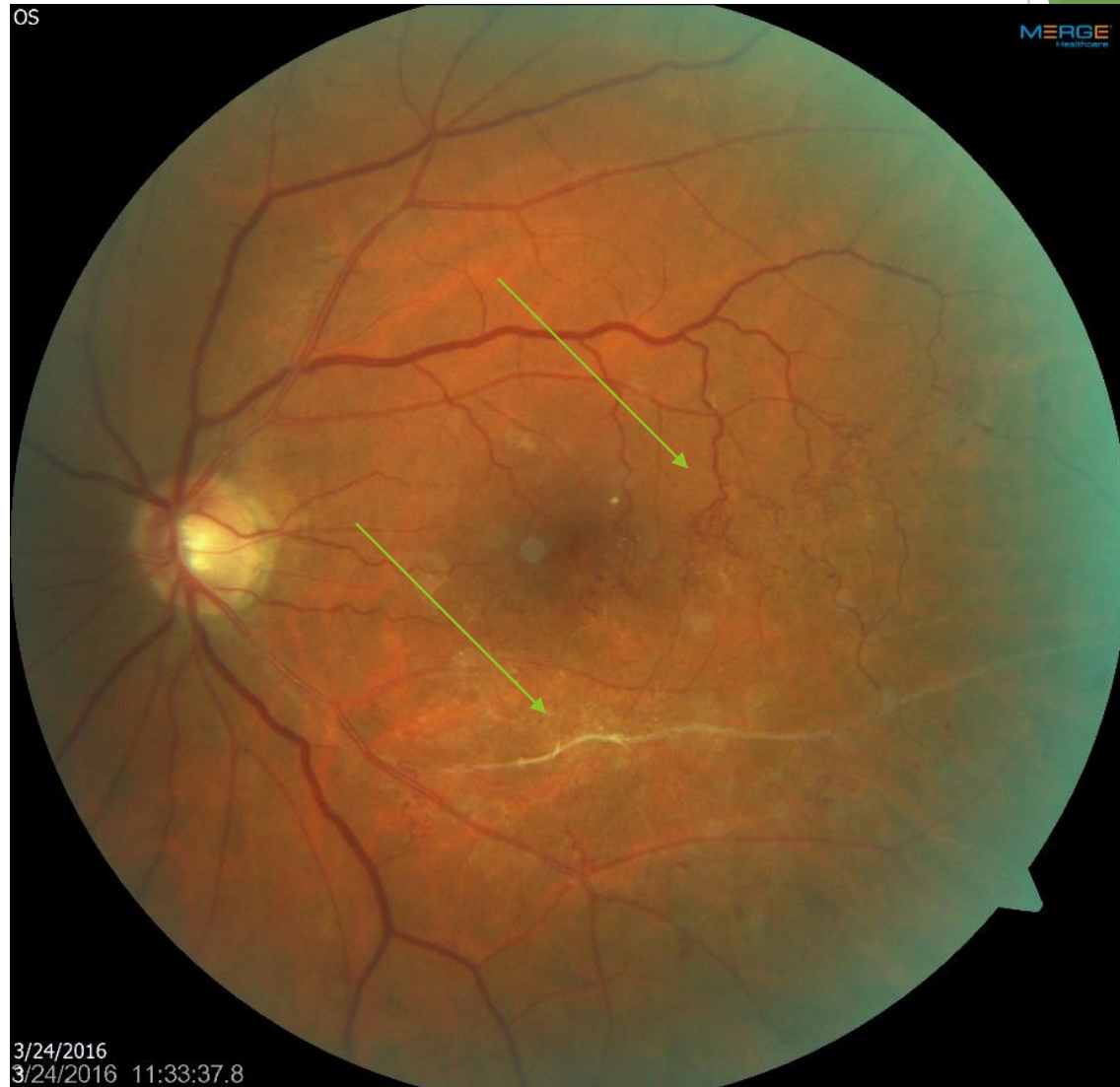BRVO

- ▶ Rarely ischemic, commonly non-ischemic.
- ▶ VA compromised if edema or blood reaches the macula or if there is long term macular ischemia
- ▶ Neo more rare, NVD/NVE >NVI
- ▶ 98% temporal. *Why? Because that is where most crossing changes are
- ▶ Prevalence in US of .6%

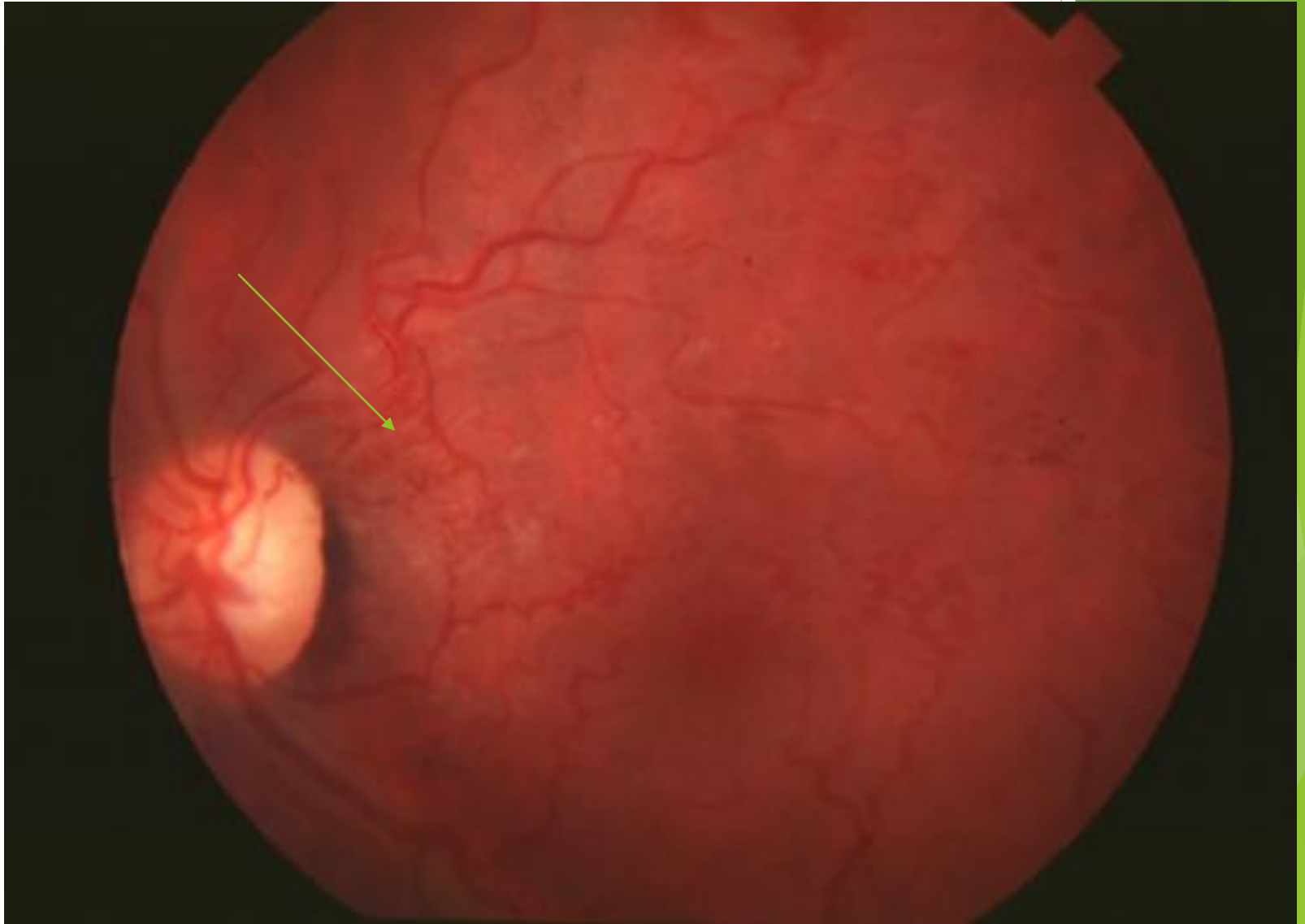
BRVO

- ▶ Spontaneous improvement in vision can occur as the macular edema resolves (over 1/3 return to 20/40 or better)
- ▶ Collateral vs. NV
- ▶ Collaterals form over 6-24 months then often regress and close, except for the largest ones. Can also form after CRVO

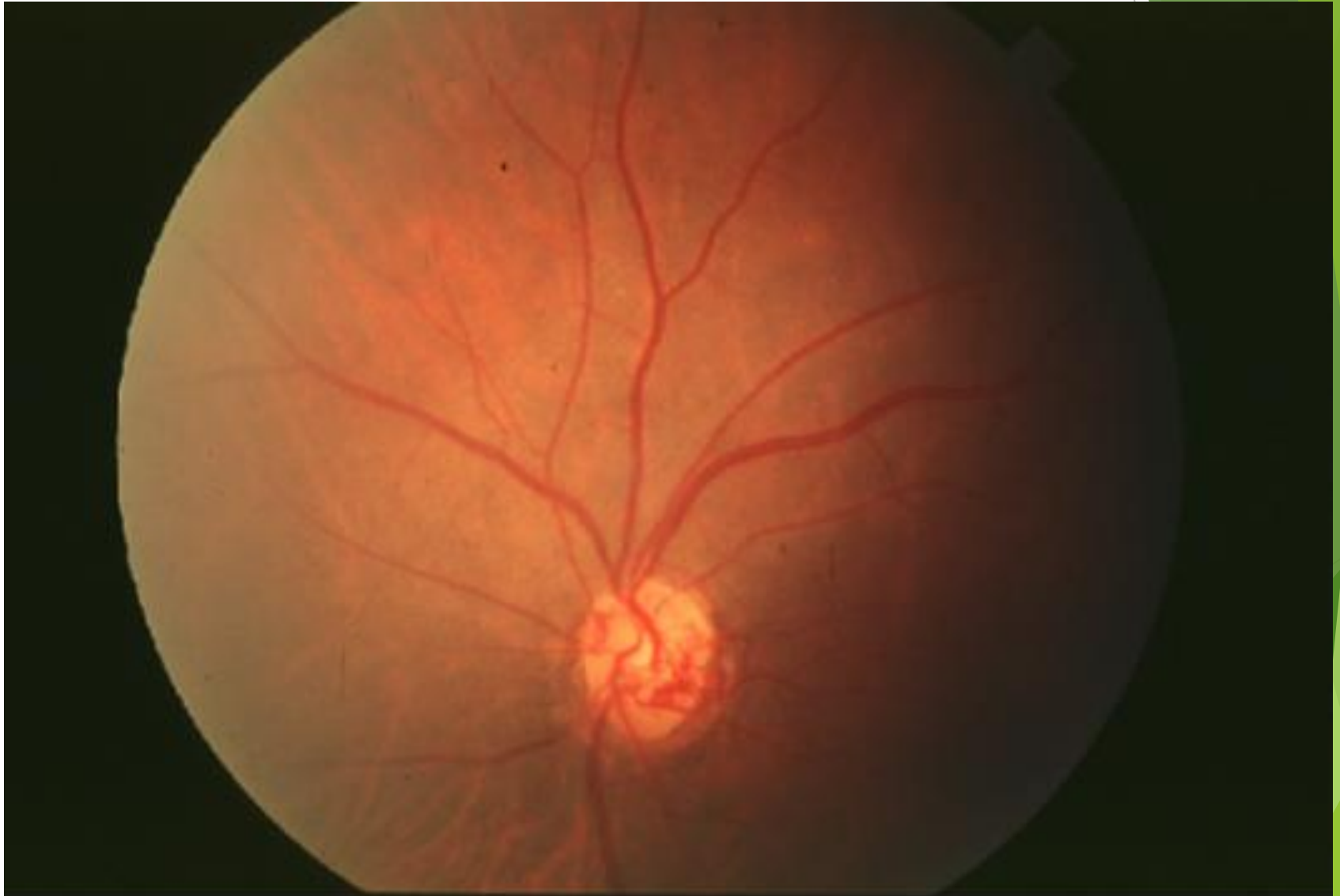Collaterals & sclerosed vein



Collaterals

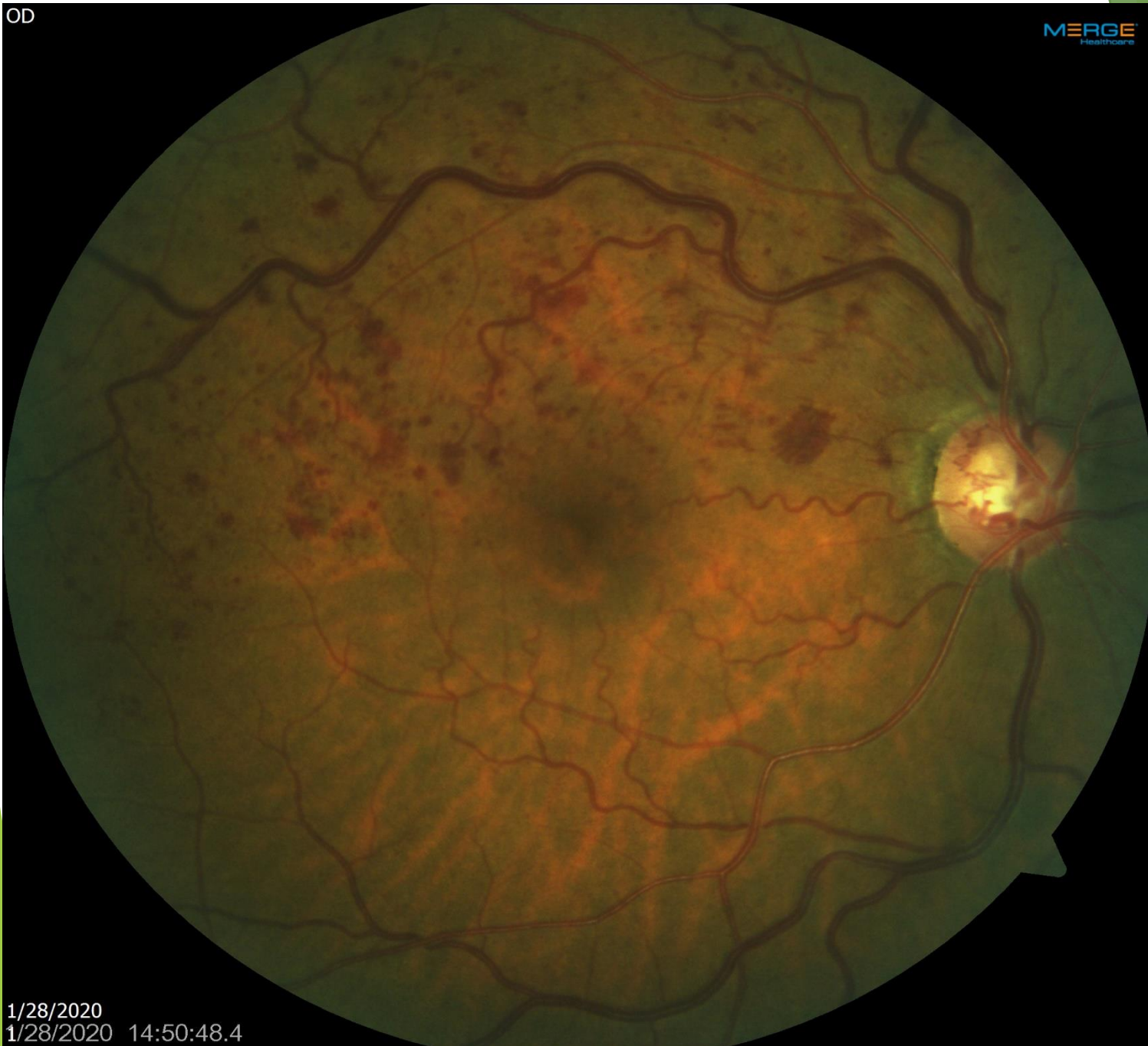

Collaterals: optic nerve



OD

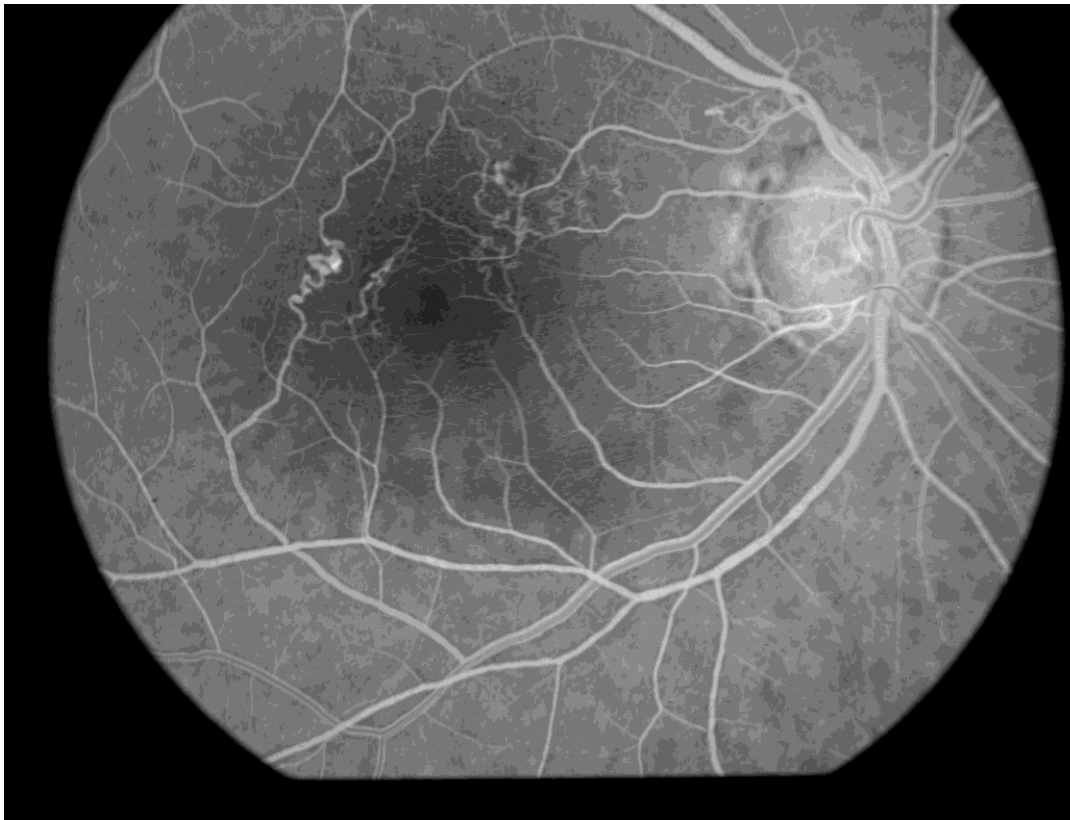
MERGE
Healthcare



collaterals

1/28/2020
1/28/2020 14:50:48.4

Collaterals IVFA courtesy Dr. Mohammad Rafietarry



BRVO treatment

- ▶ Historically: Grid - focal laser therapy if VA < 20/40
- ▶ Often wait a few months to see if improvement occurs without treatment (which it frequently does)

- ▶ Treatment has changed, however.....

Intravitreal kenalog

- ▶ SCORE study
 - ▶ Grid laser vs. 1mg/ml kenalog vs. 4mg / ml kenalog
 - ▶ After six months:
- ▶ Grid - focal laser equal to steroid injection

Intravitreal Avastin / Lucentis / Eylea / Beovu

- ▶ BRAVO study (Lucentis) At six months, gain of.....
- ▶ .3mg/ml injection vs. .5mg/ml injection vs. sham injection
 - 17 letters on EDRS chart
 - 18 letters
 - 7 letters

Eylea vs. Grid focal laser

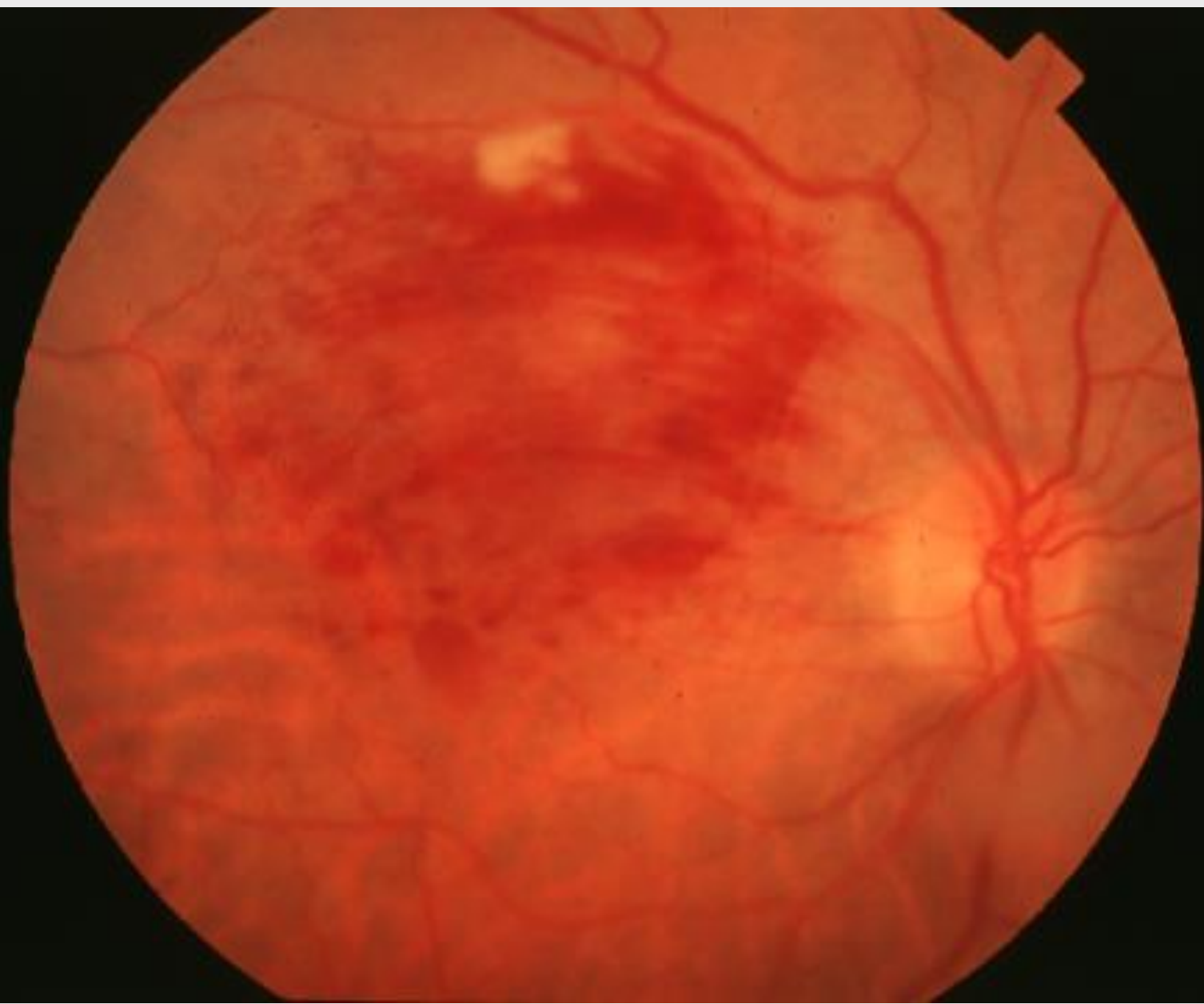- ▶ VIBRANT study of Eylea vs. laser in BRVO
- ▶ 183 patients randomized
- ▶ Assessed at 24 weeks
- ▶ 53% of Eylea group gained 15 or more letters
- ▶ 27% of grid / focal laser group gained 15 or more letters

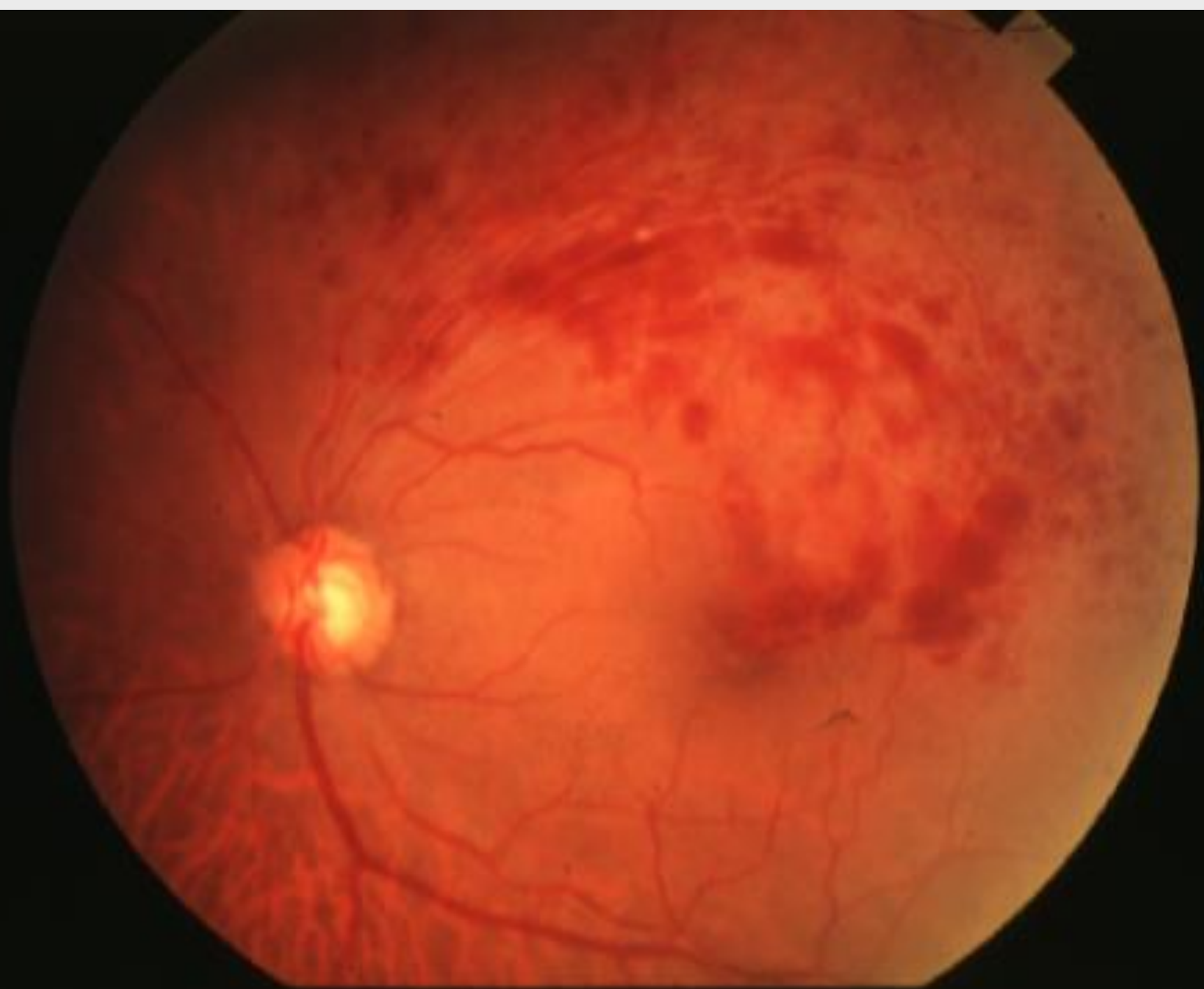Treatment

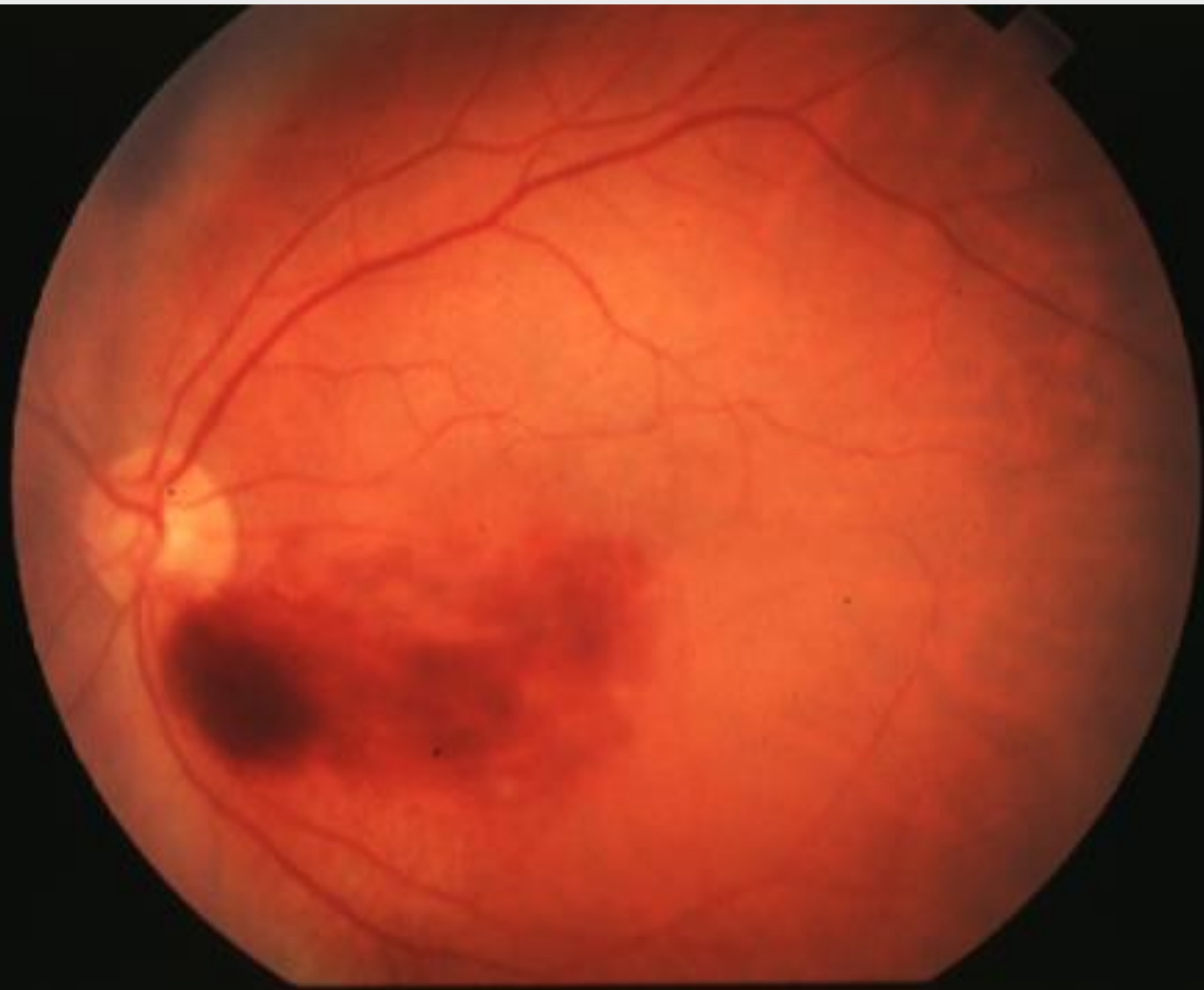- ▶ So modern management is early and prolonged (as needed) anti-VEGF injections in the presence of any significant macular edema
- ▶ Grid / focal laser therapy can be added in recalcitrant cases
- ▶ Can still be first line therapy if difficulty with travel, cost, etc.

Cost factors for perspective.....

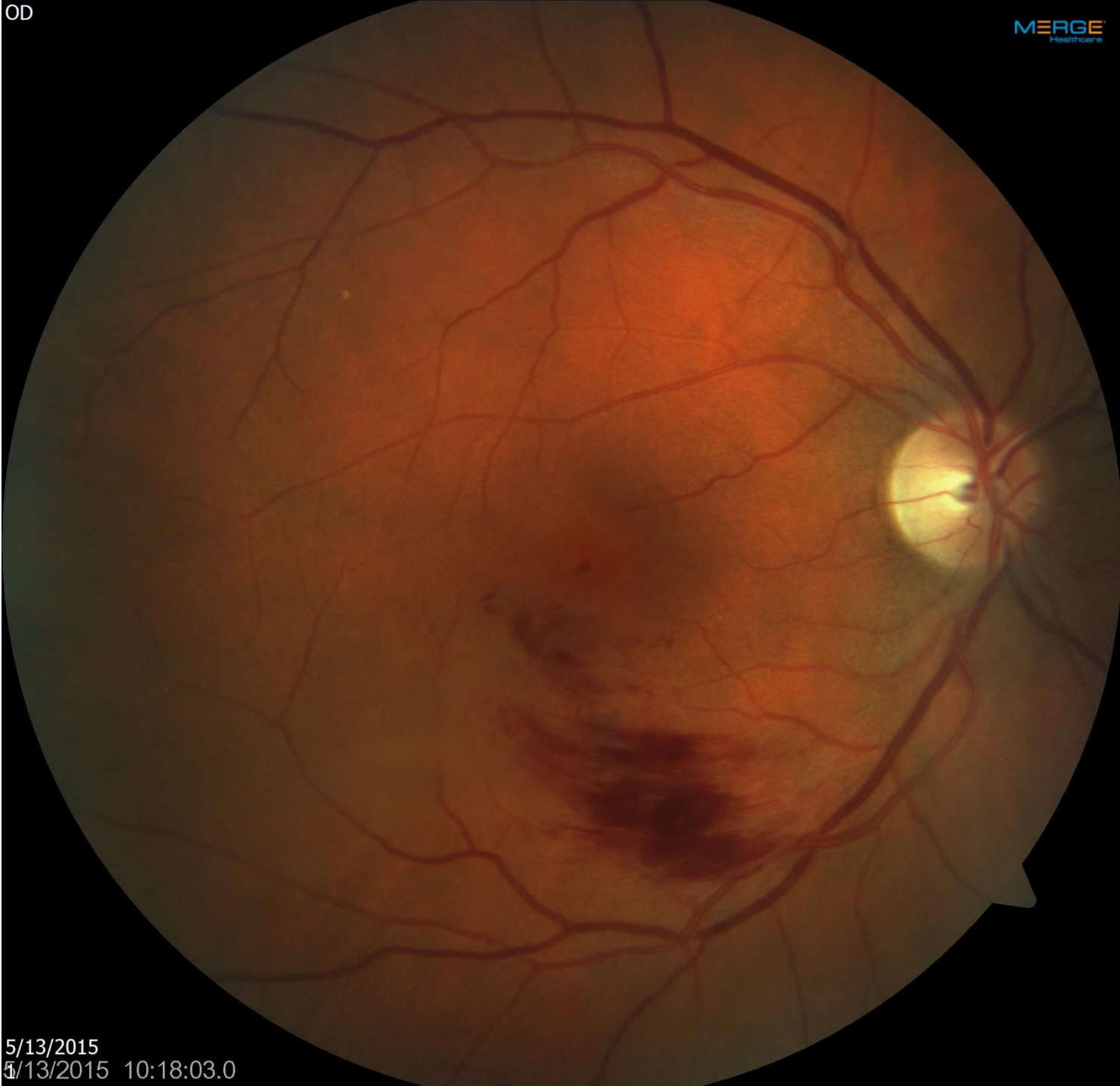
- ▶ Treating BRVO induced macular edema with Lucentis costs over \$13,000 per year for each line of vision saved.
- ▶ The average three year treatment cost across all treatment modalities is almost \$29,000
- ▶ Total annual cost of BRVO treatment in the US is estimated to be \$4.5 billion



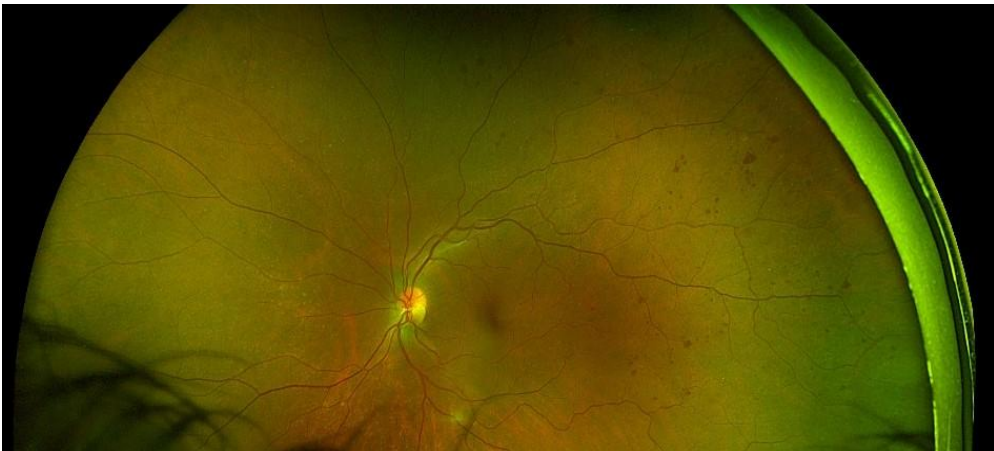




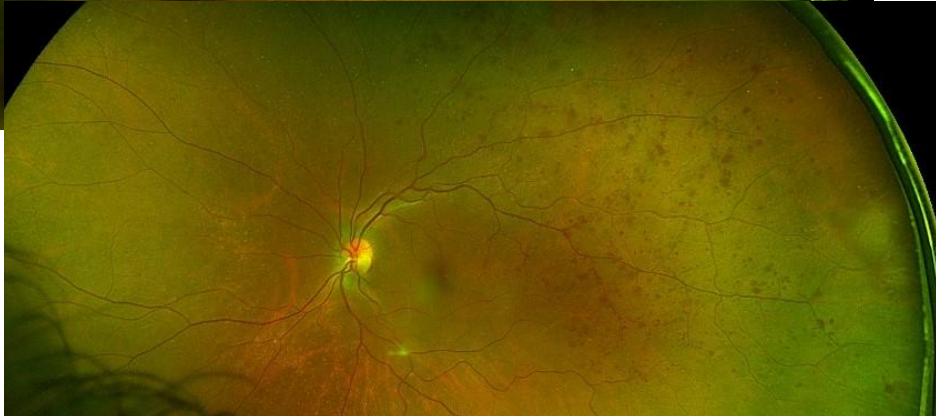OD



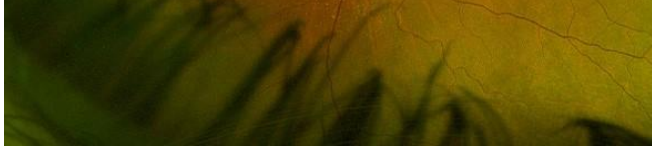5/13/2015
5/13/2015 10:18:03.0



March

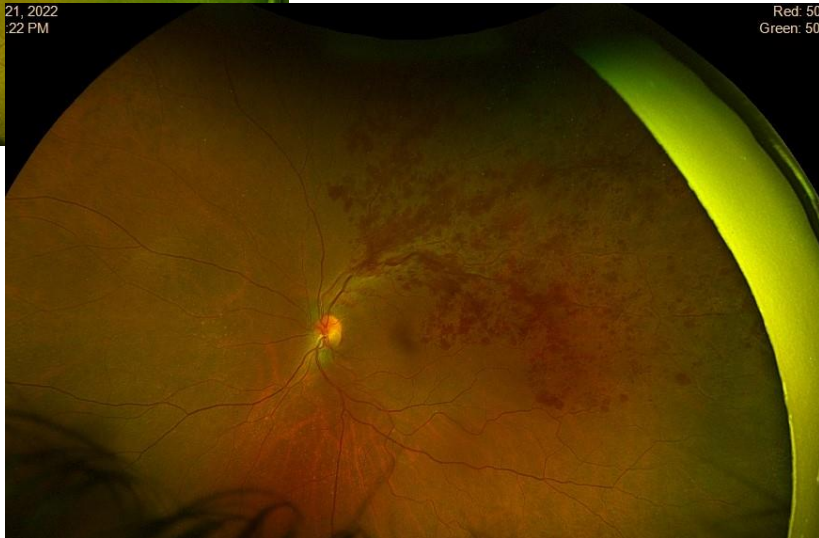


April



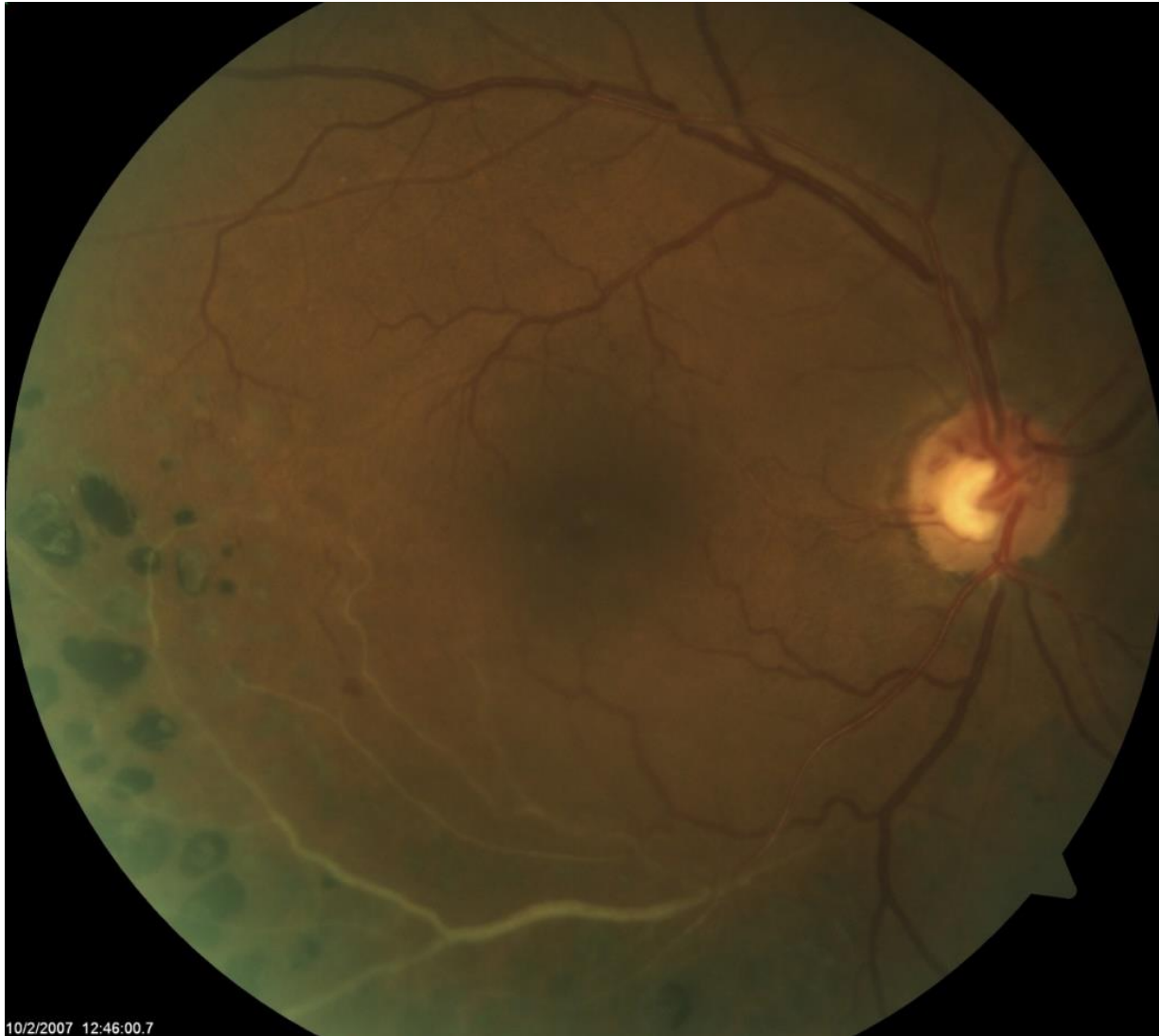21, 2022
:22 PM

Red: 50
Green: 50



June

BRVO S/P laser Tx



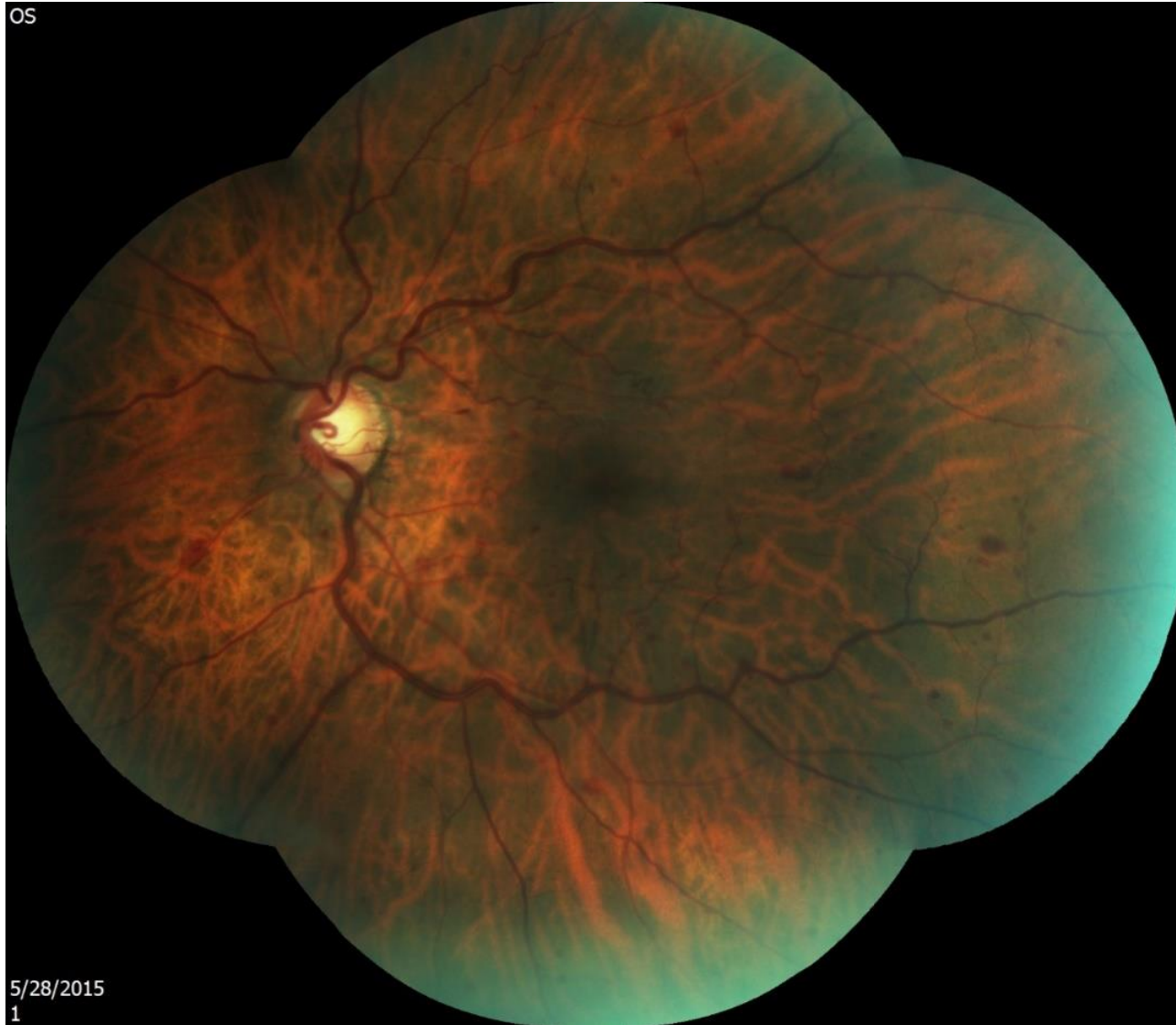Papillophlebitis

- ▶ May be an inflammatory variant of CRVO (f 2x m). Often strikes at a younger age, but not always
- ▶ Some debate if it is even a separate condition or if it is just a very mild CRVO
- ▶ Disc edema typically out of proportion with retinal hemorrhaging, 4 quadrant hemorrhaging out to periphery
- ▶ Typically mild VA reduction to around the 20/30 level but can be worse

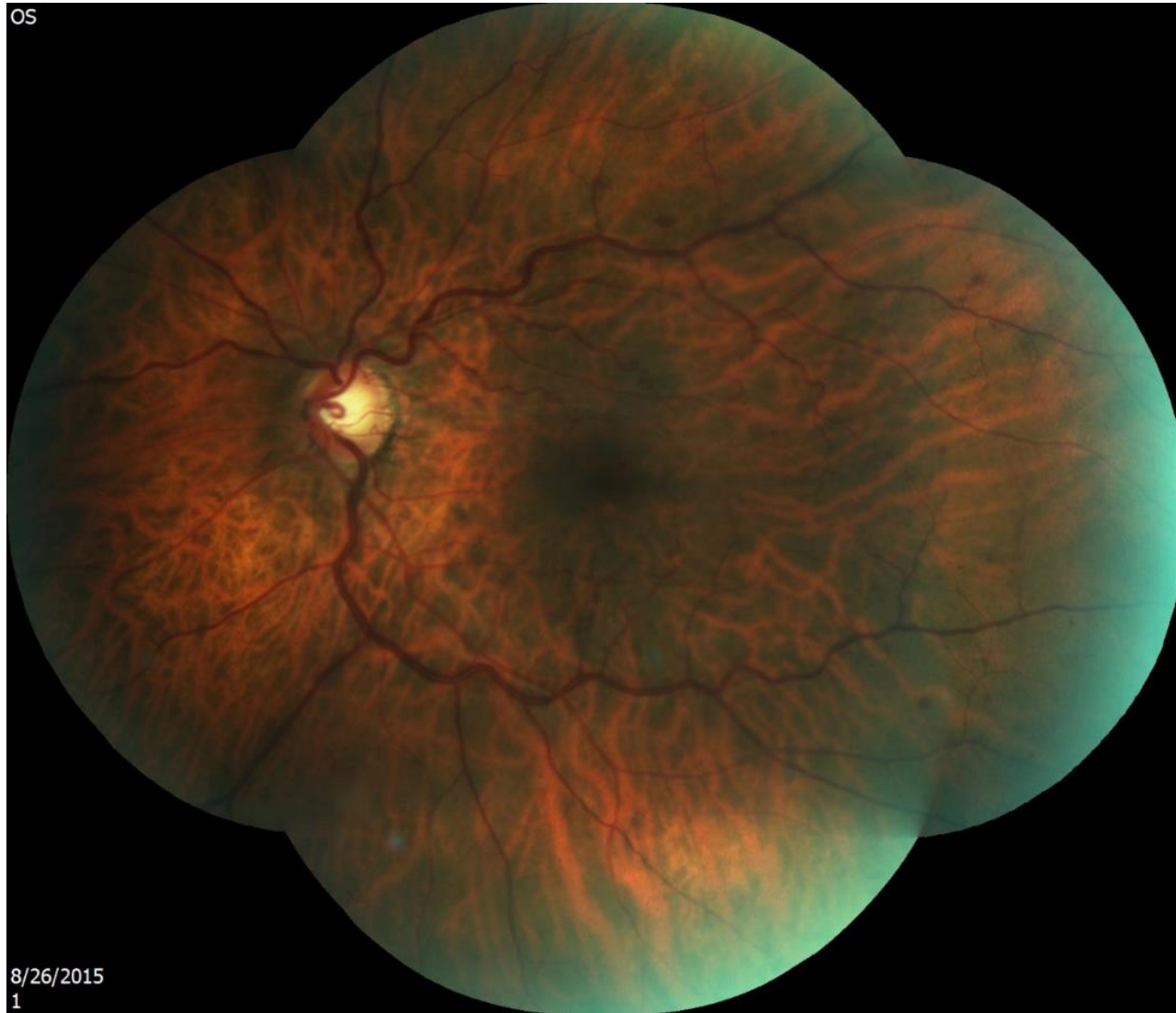Papillophlebitis

- ▶ Often a vague prodrome of scintillating, colored lights with visual disturbances
- ▶ Enlarged blind spot on the visual field
- ▶ Dilated and tortuous veins
- ▶ Condition is self limiting over the course of several months and a complete recovery is the norm
- ▶ May be related to APA syndrome, other less common systemic conditions, or may have no systemic association

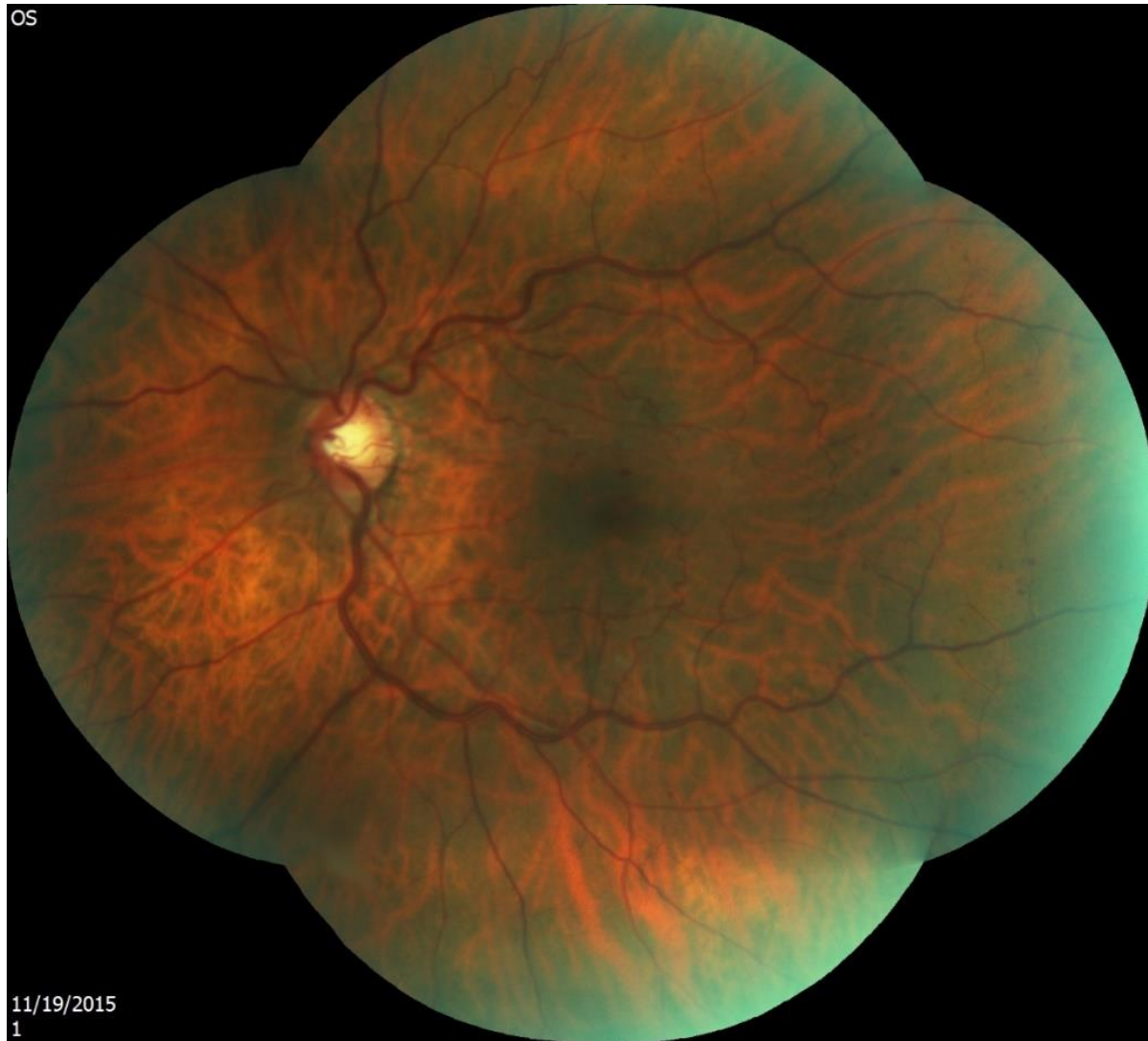Papillophlebitis



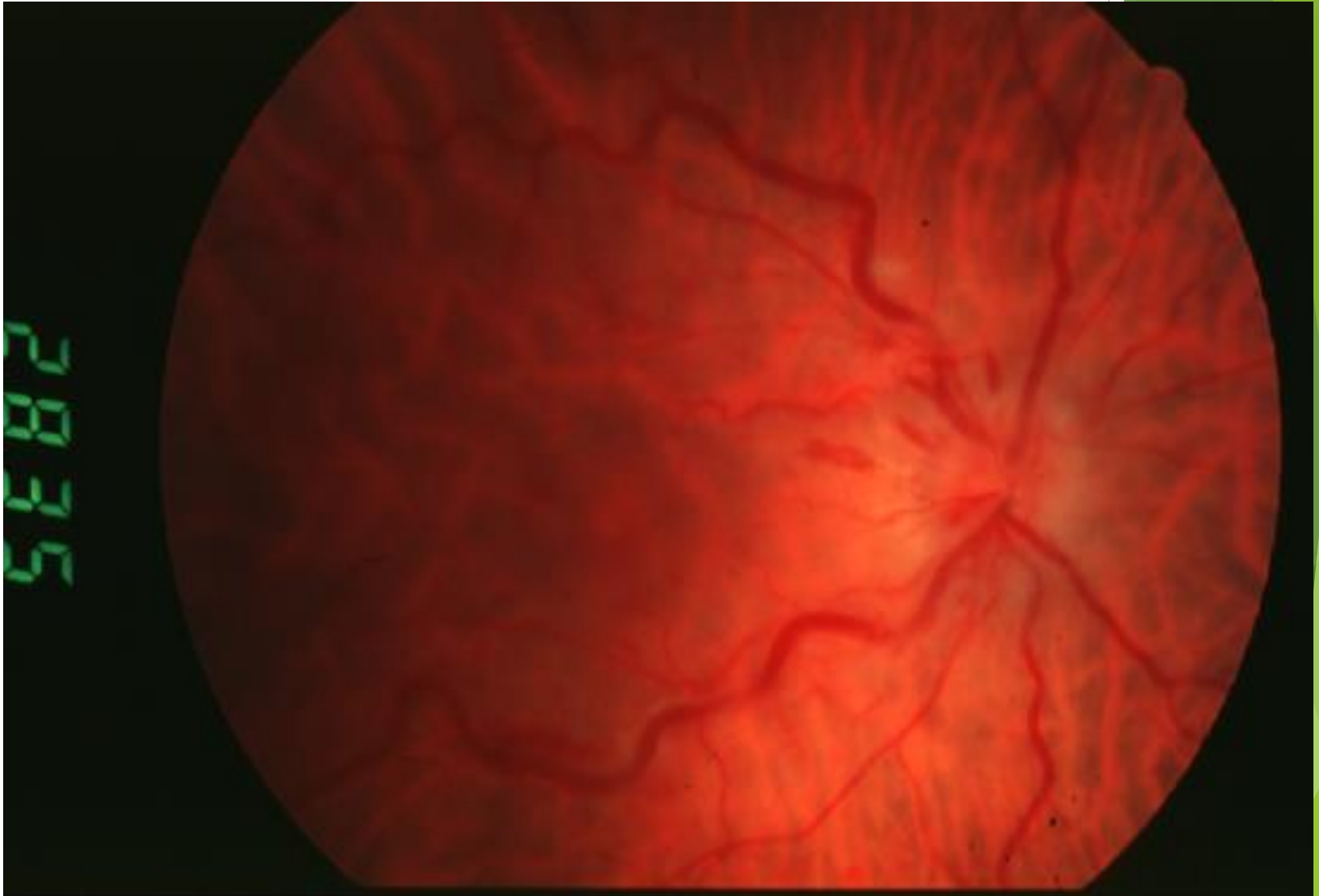
Papillophlebitis FU



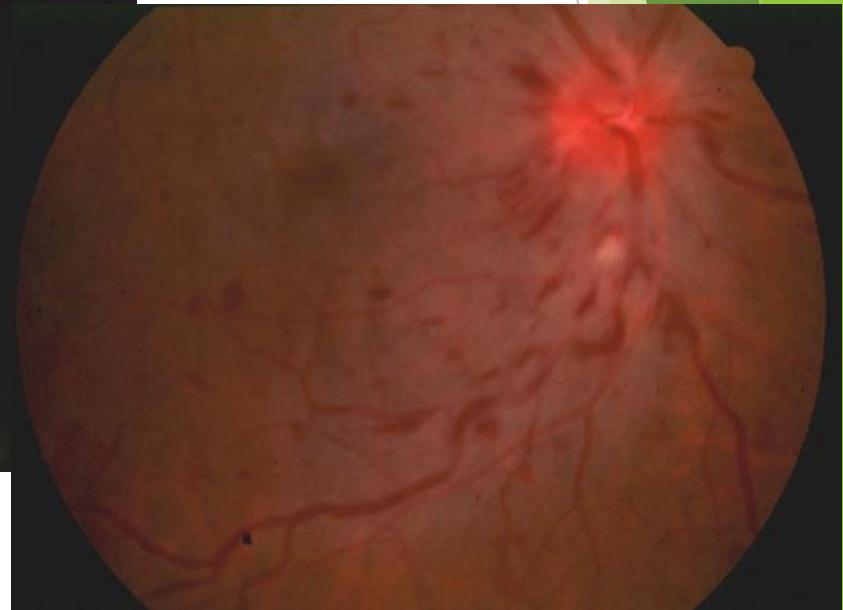
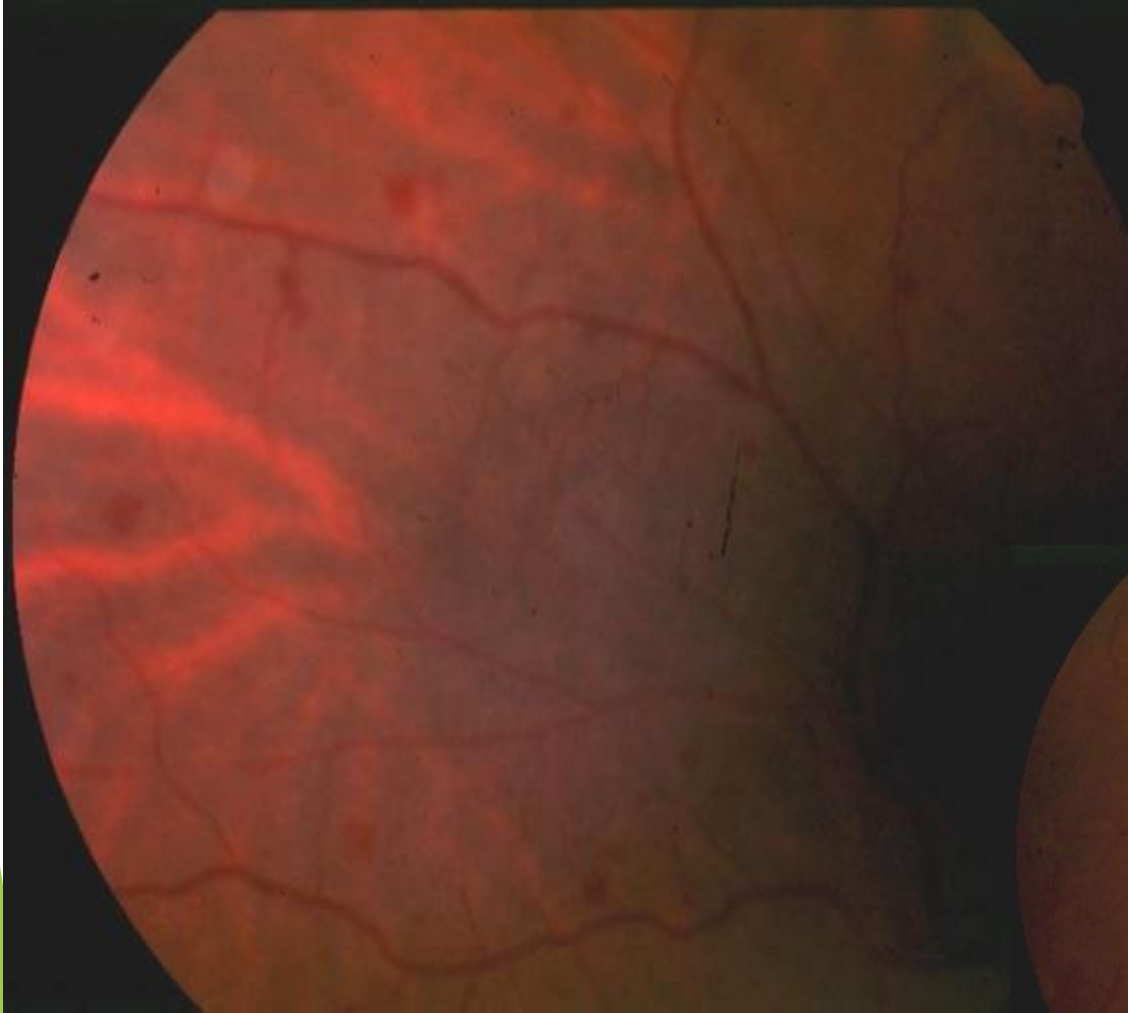
Papillophlebitis FU



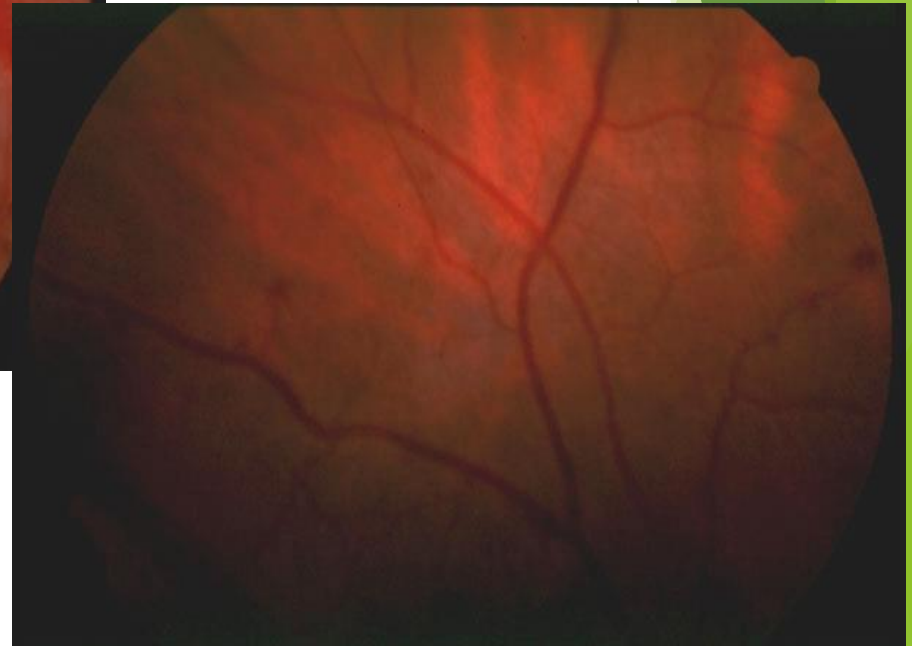
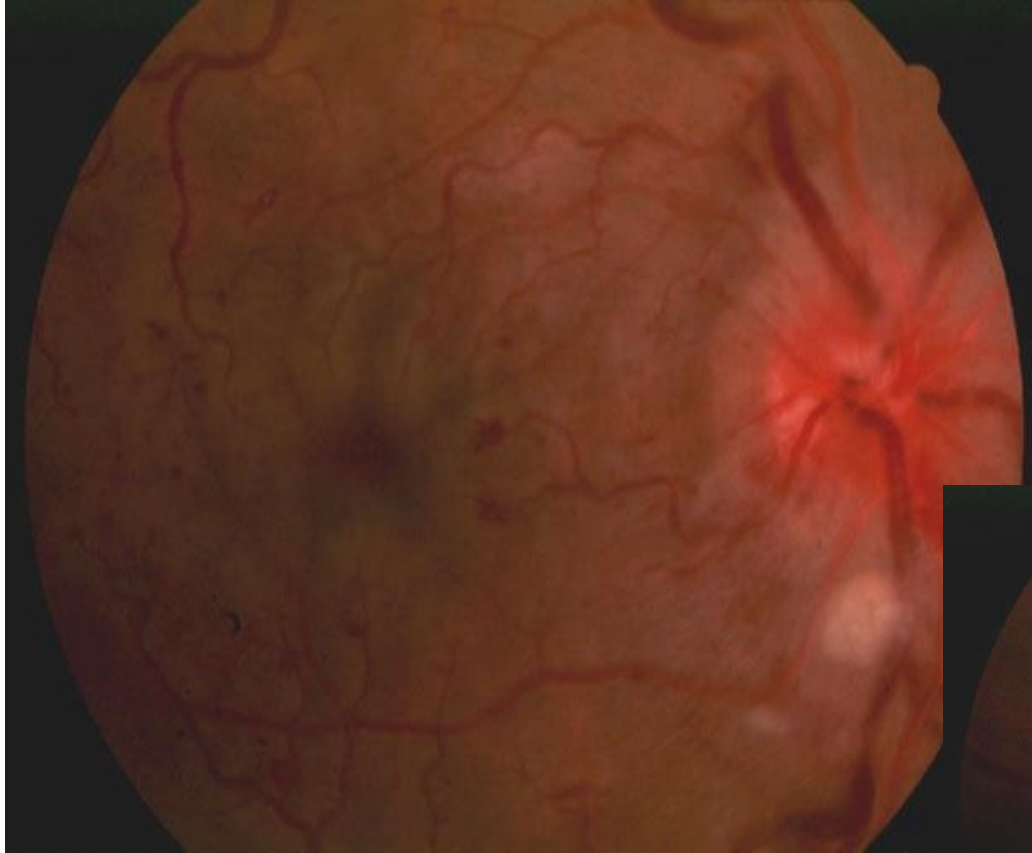
Papillophlebitis



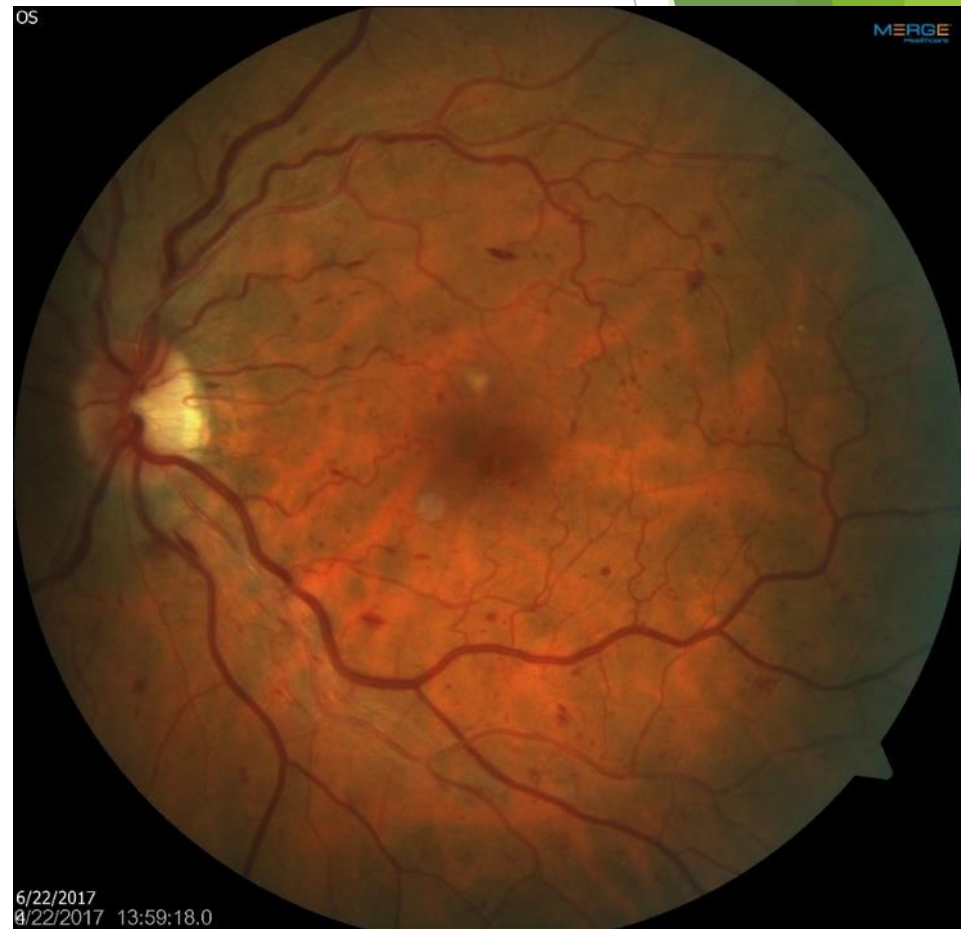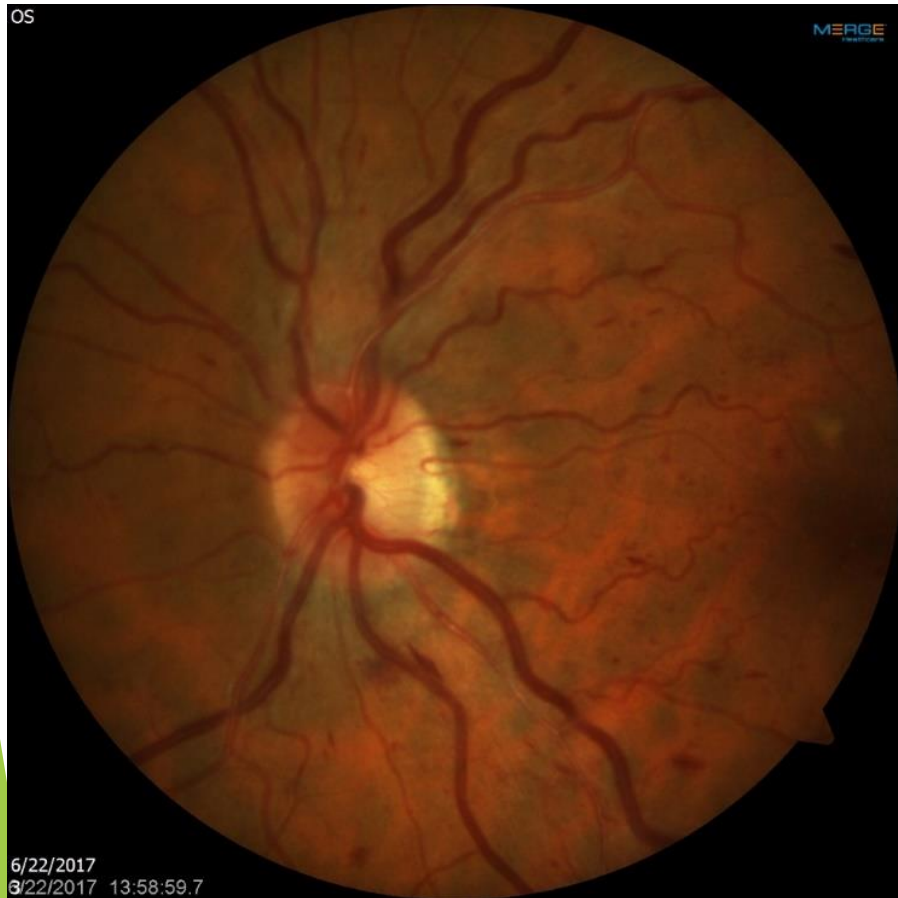Papillophlebitis



Papillophlebitis



Papillophlebitis



The End!

